

[Open Peer Review on Qeios](#)

[Case Report] Prednisolone Induced Gingival Enlargement: A Rare Case Report

Harish Prabhudev Pillutla, Aravind Kumar Pavuluri, Reddy Joseph Kishore, Mounisha Kondepati

Funding: No specific funding was received for this work.

Potential competing interests: No potential competing interests to declare.

Abstract

Drug-induced gingival overgrowth occurs commonly as an adverse effect of using drugs like calcium channel blockers, immunosuppressants, and anti-epileptics. Usually, in immunosuppressants, cyclosporin is the most common cause of gingival overgrowth. But this case report illustrates a rare gingival overgrowth caused by prednisolone which may be the first of its kind. Gingival overgrowth can be treated with multiplicity of therapeutic options like Gingivoplasty and/or Gingivectomy by using a scalpel, or electrocautery. Other contemporary therapeutic options like lasers, and cryosurgery gained prominence lately due to lesser post-operative complications. Amid various novel approaches, lasers demonstrated better healing and enhanced aesthetic outcomes making lasers an ideal treatment option for gingivoplasty/gingivectomy in gingival hyperplasia cases.

Keywords: Drug-induced gingival overgrowth, Prednisolone, Diode laser, Corticosteroids, Reactive arthritis.

Introduction

Gingival enlargement or gingival overgrowth is characterized by an increase in the size of the gingiva. There are many types of gingival enlargements, like inflammatory gingival enlargement, drug-induced gingival enlargement, hereditary gingival fibromatosis, and Gingival enlargement associated with systemic disease.^[1]

Drug-induced gingival overgrowth (DGIO) occurs as an abnormal growth of gingiva in a localized area or as generalized overgrowth due to the adverse effect of a few systemic drugs.^[2] There are many factors associated with DIGO, like age, poor oral hygiene, and genetic predisposition,^[2] Drugs associated with gingival hyperplasia are immunosuppressants(corticosteroids), calcium channel blockers, and antiepileptic drugs. Long-term use of corticosteroids has been associated with drug-induced gingival overgrowth, leading to increased bone loss, decreased collagen production, and stimulation of the inflammatory process in the periodontium.^[3] Immunosuppressants like Cyclosporine(44.9%), Everolimus(4.2%), Sirolimus(6.6%) were reported to cause gingival overgrowth.^[4] Corticosteroids are usually prescribed in organ transplant cases to prevent organ rejection, in autoimmune diseases like rheumatoid arthritis,

and also in severe cases of reactive arthritis. [1]

Reactive arthritis (ReA) comes under spondyloarthritis. It is an inflammatory reaction secondary to gastrointestinal or genitourinary infections. [5] Patients with reactive arthritis present with oligoarthritis of joints, enthesitis, cardiac abnormalities, and oral manifestations including aphthous ulcers. [6] Treatment modalities of ReA include Antibiotics, Nonsteroidal anti-inflammatory drugs (NSAIDs), Disease-modifying antirheumatic drugs (DMARDs), Corticosteroids, and Tumor necrosis factor-alpha antagonists. [6] In the case of moderate to severe ReA, Systemic Corticosteroids seem to be efficient in treating peripheral articular symptoms. [7,8] Prednisolone is a potent corticosteroid in treating ReA. The present case report illustrates a rare case of prednisolone-induced gingival overgrowth in reactive arthritis patients.

Case report

A 23-year-old male patient reported to the department of periodontics with a chief complaint of swollen gums in both upper and lower front and back teeth region for 6 years. The patient also reported bleeding while brushing. Medical and drug history revealed that the patient had a history of reactive arthritis and used prednisolone (omnacortil4 once daily) for 2 months in a tapering dose (20mg,15mg,10mg, for 10 days each respectively, and 5mg for 1 month) and was using the medication periodically contingent on the symptoms of arthritis for 1 year. On clinical examination, generalized fibrotic gingival enlargement was seen in both the upper and lower jaw. In the maxilla, gingival overgrowth covering 1/3rds of the crown and in the mandible, overgrowth covering 2/3rds of the crown is appreciated. Gingival examination revealed a firm nodular purple-brown (puce) colored enlargement involving the interdental papilla, marginal gingiva, and attached gingiva. Oral hygiene condition revealed plaque and calculus associated with generalized bleeding on probing. Complete hemogram values were within the normal limit and on clinical and radiographic examination, mild periodontitis is conceded along with grade-3 gingival overgrowth according to Bokenkamp classification (1994). Based on comprehensive medical history, local examination, and complete blood picture, a provisional diagnosis of prednisolone-induced gingival enlargement was made.

In the course of the treatment plan, oral prophylaxis was performed to remove local irritants. The patient was advised to use 0.2% chlorhexidine mouthwash (10mL bid for 7 days) twice a day, also patient was instructed to maintain good oral hygiene and was recalled after 1 week. Scaling root planning (SRP) was done to remove subgingival deposits and the patient was recalled after 1-month, clinical examination revealed an amiable reduction in the gingival overgrowth, but fibrotic pseudopockets are still persistent. For congenial aesthetic results, the surgical phase of treatment was attempted to remove gingival hyperplastic tissue by employing gingivectomy along with gingivoplasty in an elective approach with 810nm diode laser (Novolase)TM. Patient follow-up was done at 1 week, 3 months, and 1 year respectively.

Histopathological examination of the specimen under a microscope using 10x magnification with hematoxylin and eosin staining shows hyper parakeratotic epithelium with long rete pegs. In the connective tissue stroma, focal areas show deposition of abundant collagen fibers associated with fibroblasts. Other focal areas presented dense chronic inflammatory infiltrate with abundant vascularization.

Discussion

Treatment for DIGO includes initial oral prophylaxis followed by scaling and root planning. If gingival overgrowth subsides after the initial therapy, there is no need for further treatment. If it doesn't subside after initial therapy, various treatment modalities like drug substitution and simple Gingivoplasty/gingivectomy can be done based on the extent of overgrowth with scalpel, electrocautery, cryosurgery, and lasers.

To overcome post-operative complications, lasers are the prime choice because of their known advantages like good healing, less post-operative pain, aesthetics, good contouring, and less scarring. So, in this case report 810nm diode laser is used in treating prednisolone-induced gingival overgrowth.

Laser dentistry is a modern innovation that has gained popularity in recent times due to patient comfort and potential advantages like less bleeding, less pain, and improved healing. There are many types of lasers, one of which we are going to discuss here is semiconductor laser or diode laser. The semiconductor laser is being used vastly as it is economical, highly efficient, and reliable with convenient ergonomics.^[7] Their smaller size and high energy density make them useful in medical procedures.^[7] Diode lasers have applications as bio-stimulation devices (soft lasers) and also as surgical lasers (hard lasers).^[7] There are various applications of diode lasers in periodontics like ankyloglossia, vestibuloplasty, gingivoplasty/gingivectomy, frenectomy, pyogenic granuloma, crown lengthening, photobiomodulation (PBM), photodynamic therapy(PDT).

Normal human gingival fibroblasts proliferate in response to cyclosporine-induced gingival hypertrophy. The increase of collagen observed in gingival overgrowth can be accounted to cyclosporine-induced suppression of collagenolytic activity inside the gingival tissues.

Its histopathological evaluation reveals distinctly inflamed lesions along with fibrosis.^[2]

Microscopic features of this Prednisolone-induced gingival enlargement biopsy sample are consistent with the histopathological picture of immunosuppressive drug (cyclosporine) associated gingival enlargement. Even though there are a multitude of factors involved in this case report like reactive arthritis, use of prednisolone, and age, our interpretation of the pathophysiology is unclear. But interestingly the findings seem to be confluent with the cytological analysis of cyclosporine-induced gingival overgrowth.

Conclusion

Prednisolone-induced gingival enlargement is a rare case. As per our search in databases like PUBMED, MEDLINE, etc There seems to be no literature on prednisolone causing gingival overgrowth, and further research, case reports and retrospective studies should be done on prednisolone-induced overgrowth to substantiate the diagnosis and get a better understanding on mechanism and pathogenesis.

Figures

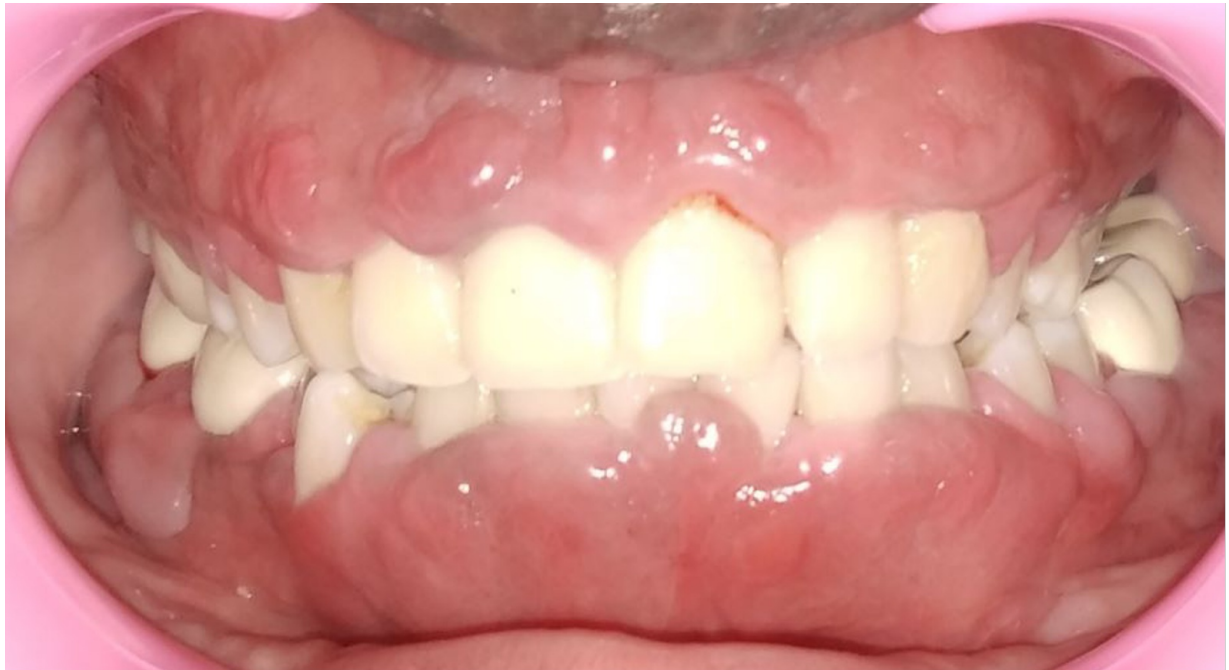

Figure 1. Pre-operative picture of gingival overgrowth (front profile)

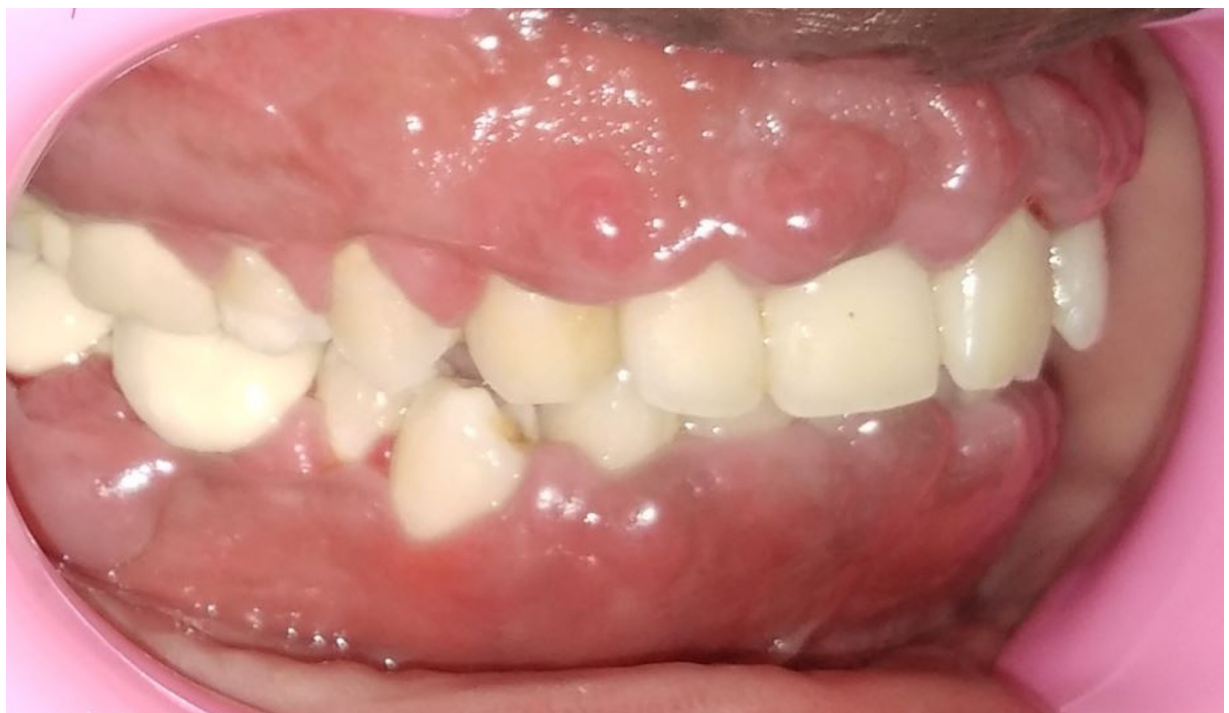

Figure 2. Pre-operative picture of gingival overgrowth (right profile)

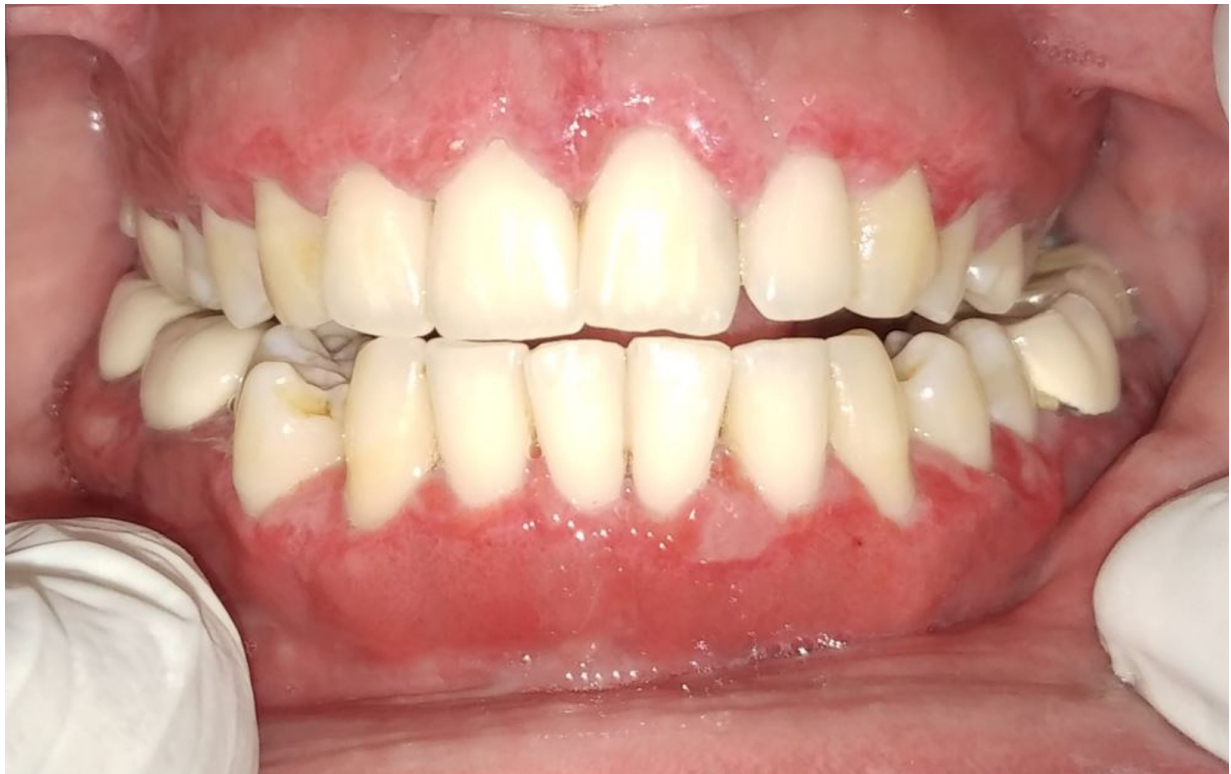

Figure 3. One-week follow-up picture (front profile)

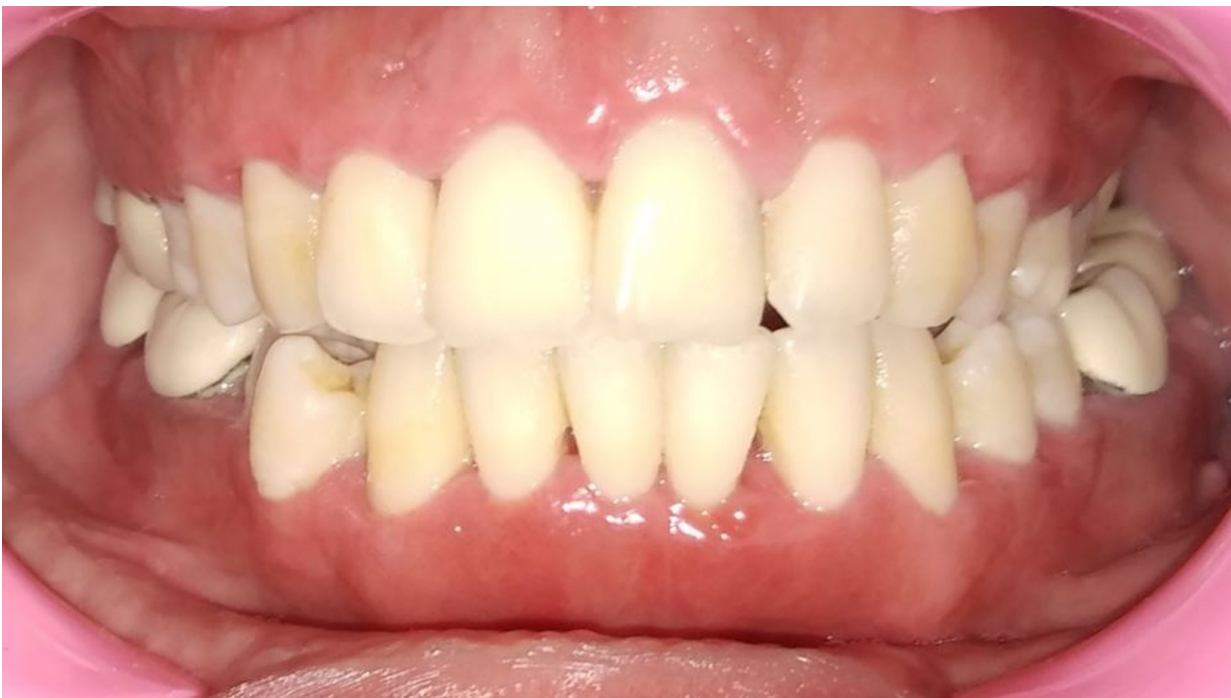

Figure 4. Three months follow-up picture (front profile)

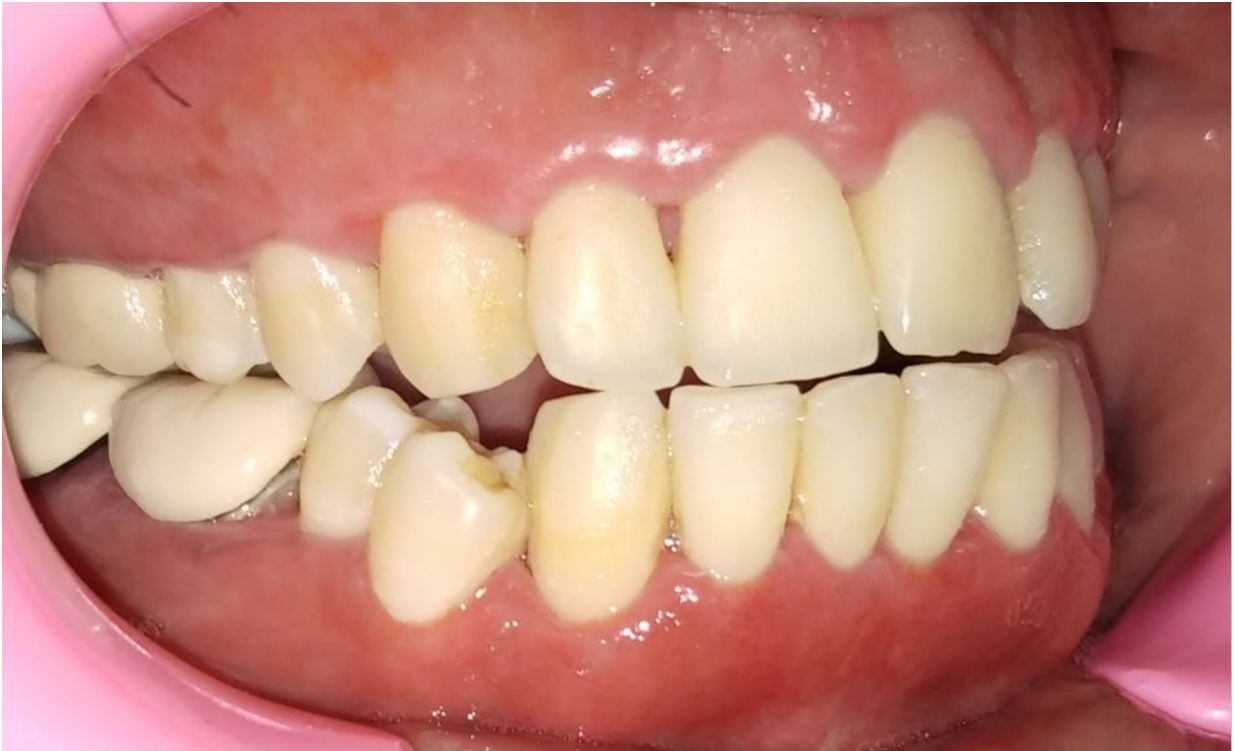

Figure 5. Three months follow-up picture (right profile)

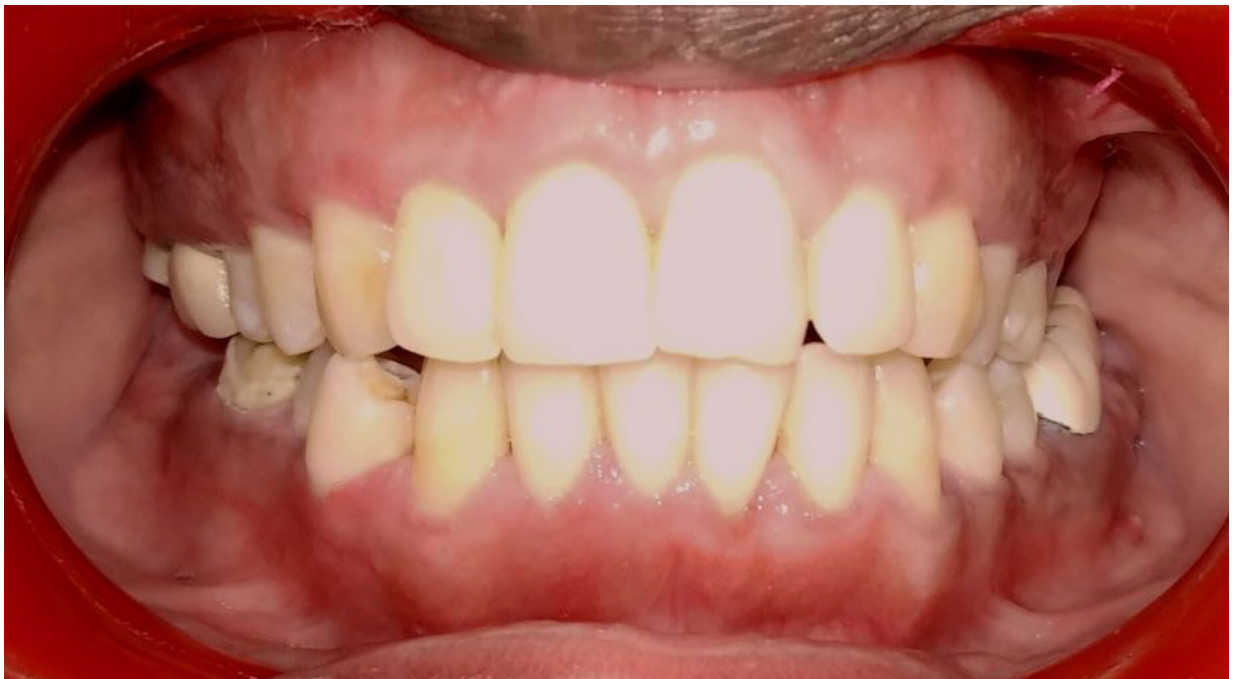

Figure 6. One-year follow-up picture (front profile)

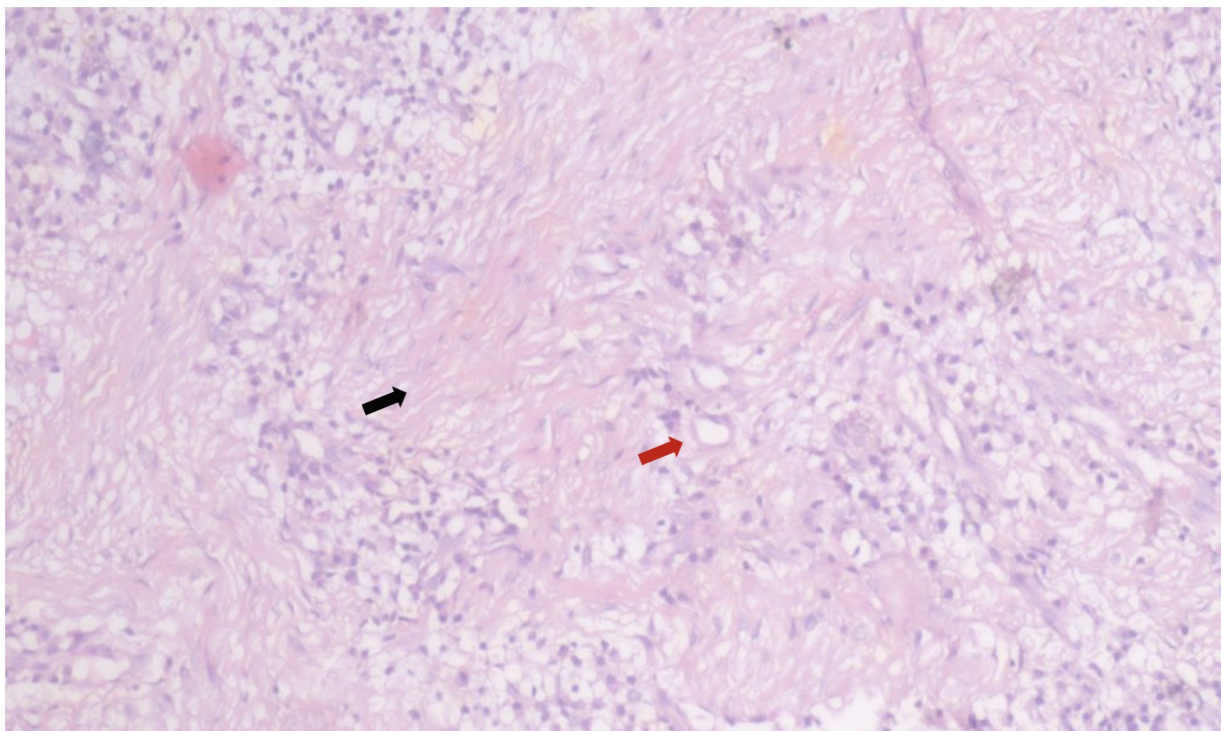


Figure 7. Haematoxylin and eosin (H&E) stained section exhibiting abundant collagen fibers represented with a black arrow and vascularization represented with a red arrow under 10x magnification.

Statements and Declarations

Conflicts of interest

No potential conflict of interest relevant to this article was reported.

Funding

None.

Other References

- Wendling D, Prati C, Chouk M, Verhoeven F. Reactive arthritis: treatment challenges and future perspectives. *Curr Rheumatol Rep* 2020;22:1-7.
- Bharti V, Bansal C. Drug-induced gingival overgrowth: The nemesis of gingiva unravelled. *J Indian Soc Periodontol* 2013;17:182.

References

1. ^{a, b}Tungare S, Paranjpe AG. *Drug-Induced Gingival Overgrowth*. [Updated 2022 Sep 19]. In: *StatPearls [Internet]*. Treasure Island (FL): StatPearls Publishing; 2024 Jan. Available from: <https://www.ncbi.nlm.nih.gov/books/NBK538518/>
2. ^{a, b, c}Drożdżik A, Drożdżik M. *Drug-Induced Gingival Overgrowth—Molecular Aspects of Drug Actions*. *Int J Mol Sci* 2023;24:5448.
3. [^]Agrawal AA. *Gingival enlargements: Differential diagnosis and review of literature*. *World J Clin Cases* 2015;3:779.
4. [^]Brasil-Oliveira R, Cruz ÁA, Sarmiento VA, Souza-Machado A, Lins-Kusterer L. *Corticosteroid use and periodontal disease: a systematic review*. *Eur J Dent* 2020;14:496-501.
5. [^]García-Kutzbach A, Chacón-Súchite J, García-Ferrer H, Iraheta I. *Reactive arthritis: update 2018*. *J Clin Rheumatol* 2018;37:869-74.
6. ^{a, b}Carter JD. *Treating reactive arthritis: insights for the clinician*. *Ther Adv Musculoskelet Dis* 2010;2:45-54.
7. ^{a, b, c}Romanos GE, *Laser Fundamental Principles*. In Romanos GE, editor. *Advanced Laser Surgery in Dentistry, 1st ed*. Hoboken: John Wiley & Sons;2021.1-33.