

[Open Peer Review on Qeios](#)

[Case Report] Clear Cell Carcinoma of the Ovary with Disseminated Intravascular Coagulation and Haemoperitoneum with Tumour Perforation

Thilina Rathnasekara¹, Lanka Wijekoon², Prasanna Weerawansa², Bhagya Jayasiri, Sisira Siribaddana²

¹ University of Colombo

² Rajarata University of Sri Lanka

Funding: No specific funding was received for this work.

Potential competing interests: No potential competing interests to declare.

Abstract

We report a case of a 34-year-old woman with haemoperitoneum and acute disseminated intravascular coagulation (DIC) following the rupture of ovarian clear cell carcinoma (OCCC), the first documented case of its kind. Although DIC is known to be associated with ovarian cancer, acute DIC with bleeding in the clear cell variant has not been reported.

The patient, who had a right adnexal lesion, was found to have anaemia and thrombocytopenia. Intra-abdominal bleeding due to the rupture of a malignant ovarian cyst associated with DIC was identified as the cause. After surgery, the DIC resolved, suggesting that OCCC can be an aetiology for acute DIC and bleeding.

Rathnasekara T¹, Wijekoon L², Weerawansa P², Jayasiri B³, Siribaddana SH²

¹ *Postgraduate Institute of Medicine, University of Colombo*

² *Department of Medicine, Faculty of Medicine and Allied Sciences, Rajarata University of Sri Lanka*

³ *Department of Gynaecology and Obstetrics, Teaching Hospital Anuradhapura*

*Correspondence: thilina.rathnasekara1@gmail.com

Introduction

Ovarian clear cell carcinoma (OCCC) is a rare subtype of ovarian epithelial carcinoma and has several common complications, including endometriosis and a hypercoagulable state causing thromboembolic complications [1][2]. Disseminated intravascular coagulation (DIC), always a complication of another disease, such as malignancy, can manifest with thrombosis, thromboembolism, or bleeding [3]. Here, we report a case of a female patient presenting with haemoperitoneum and DIC associated with a ruptured clear cell carcinoma of the ovary.

Case Presentation

A 34-year-old woman developed dysmenorrhoea four months before this presentation. Her abdominal ultrasound confirmed a right adnexal cystic lesion with both thick and thin septae. A contrast-enhanced computed tomography (CT) scan showed a well-demarcated right adnexal cyst measuring 10cm (anterior-posterior) x 9cm (craniocaudal) x 8cm (width), with a few thin and thick septae within the lesion and no pelvic or para-aortic lymphadenopathy.

Due to the elevated cancer antigen 125 level (120 ng/mL), she was admitted for surgical excision of her right ovarian cyst. On admission, she developed a mild fever and had a low platelet count of 43000/mm³, with increasing abdominal pain. The patient developed shortness of breath and had no other apparent cause for the bleeding. She was pale and dyspnoeic with a respiratory rate of 30 breaths per minute and had tachycardia of 124 beats per minute with a blood pressure of 100/60 mmHg. The lower abdomen was tender with ascites on percussion.

The patient's platelet count dropped rapidly from 43000/mm³ to 8000/mm³ and her haemoglobin level from 10.9 g/dl to 8.2 g/dl. The blood picture revealed microangiopathic haemolytic anaemia with low haemoglobin. A rotational thromboelastometry (RoTEM) revealed clotting factor deficiency, low fibrin and platelets, suggesting consumption due to the DIC (Figure 1 and Table 1). Abdominal ultrasonography demonstrated predominantly solid areas in the right adnexal lesion, suggesting rupture of the tumour with free fluid in the abdomen, implying intraperitoneal bleeding.

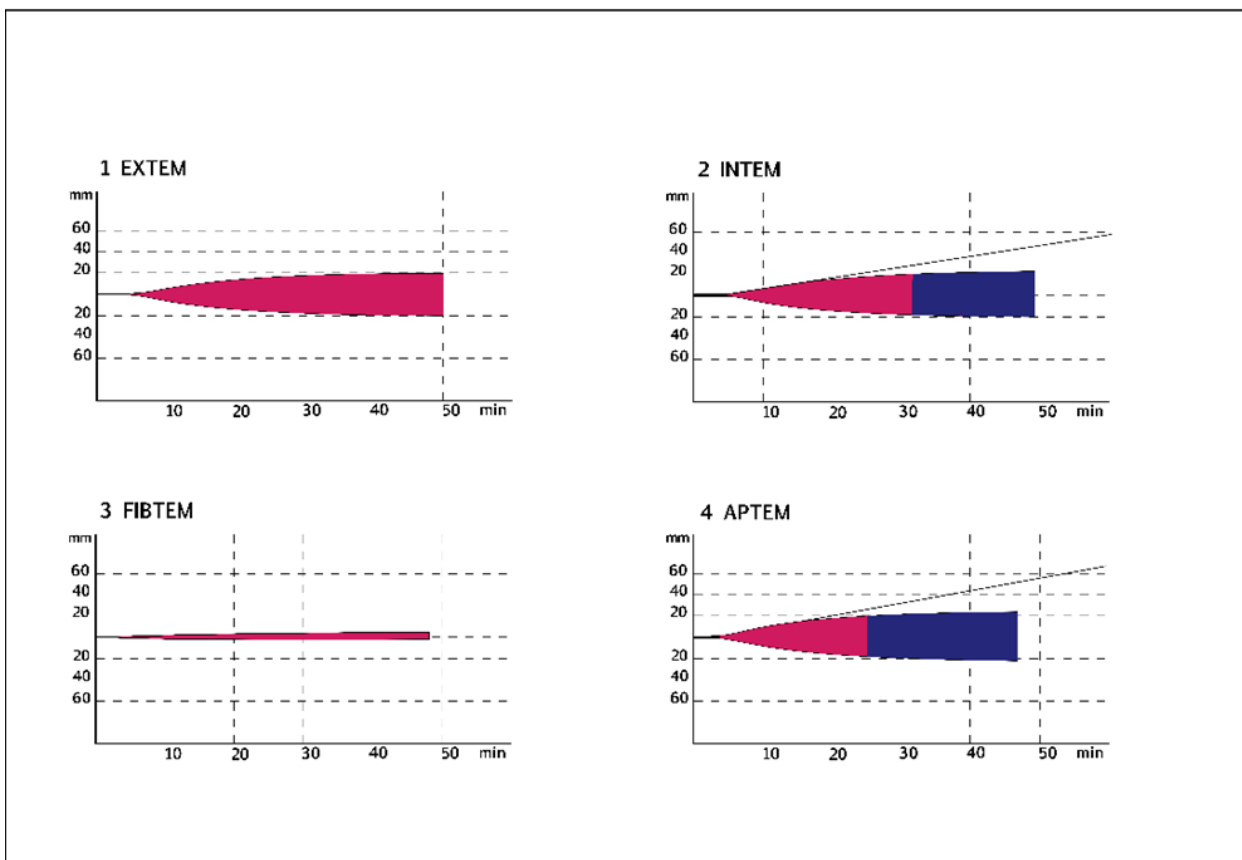


Figure 1. RoTEM study

RoTEM: Rotational thromboelastometry, EXTEM: extrinsically-activated test with tissue factor, INTEM: intrinsically-activated test using ellagic acid, FIBTEM: fibrin-based extrinsically activated test with tissue factor and the platelet inhibitor cytochalasin D, APTEM: a modified EXTEM assay incorporating aprotinin to stabilise the clot against hyperfibrinolysis, mm: millimetre, min: minute

Table 1. RoTEM study indicating clotting factor deficiency by prolonged CT and CFT and low fibrinogen by reduced α . Low platelet count causing reduced clot strength indicated by low A10 and MCF.

	CT	CFT	α	A10	MCF
EXTEM	314s			11mm	20mm
	(38-79)			(43-65)	(50-72)
INTEM	285s	1611s	14°	12mm	22mm
	(100-240)	(30-110)	(70-83)	(44-66)	(50-72)
FIBTEM	152s			4mm	4mm
				(7-23)	(9-25)
APTEM	237s	1296s	16°	13mm	24mm

(RoTEM: Rotational thromboelastometry, CT: clotting time, CFT: clot formation time, α : alpha-angle, A10: amplitude at 10 minutes after clotting time, MCF: maximum clot firmness, EXTEM: extrinsically-activated test with tissue factor, INTEM: an intrinsically-activated test using ellagic acid, FIBTEM: fibrin-based extrinsically activated test with tissue factor and the platelet inhibitor cytochalasin D, APTTEM: a modified EXTEM assay incorporating aprotinin to stabilise the clot against hyperfibrinolysis)

An urgent laparotomy was planned, and blood, fresh frozen plasma, and platelets were transfused to optimise the patient before surgery. The surgery confirmed the presence of haemoperitoneum and bleeding from the right adnexal cyst. A bilateral salpingo-oophorectomy was performed.

The histopathology described a right OCCC without lymphovascular or perineural invasion and endometriosis in surrounding tissues (Figure 2 and Figure 3). After the surgical resection, the platelet count increased, and the DIC resolved, indicating that the ovarian tumour triggered the DIC.

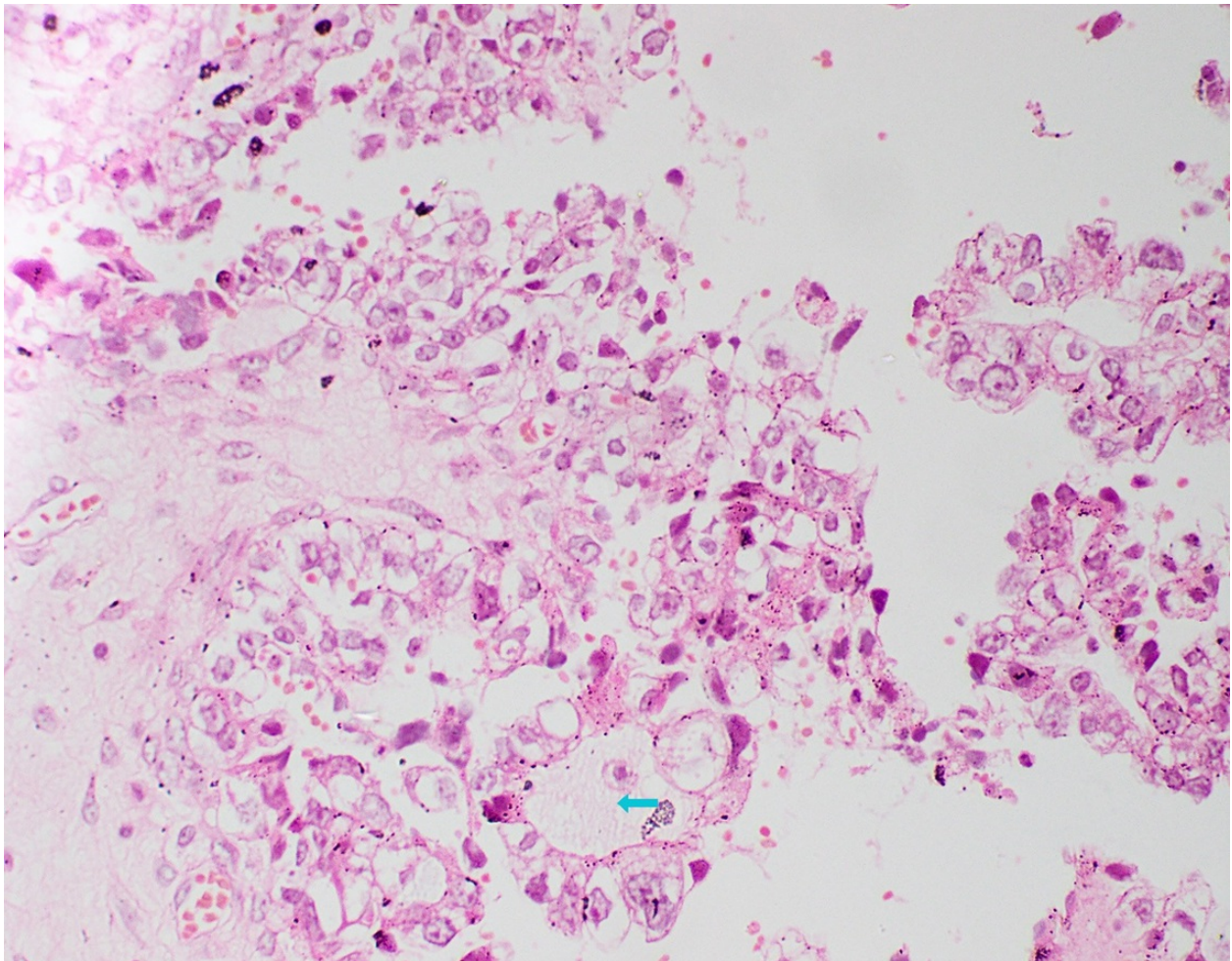


Figure 2. Histopathology of the tumour with haematoxylin and eosin stain showing a tubulocystic (light blue arrow) structure.

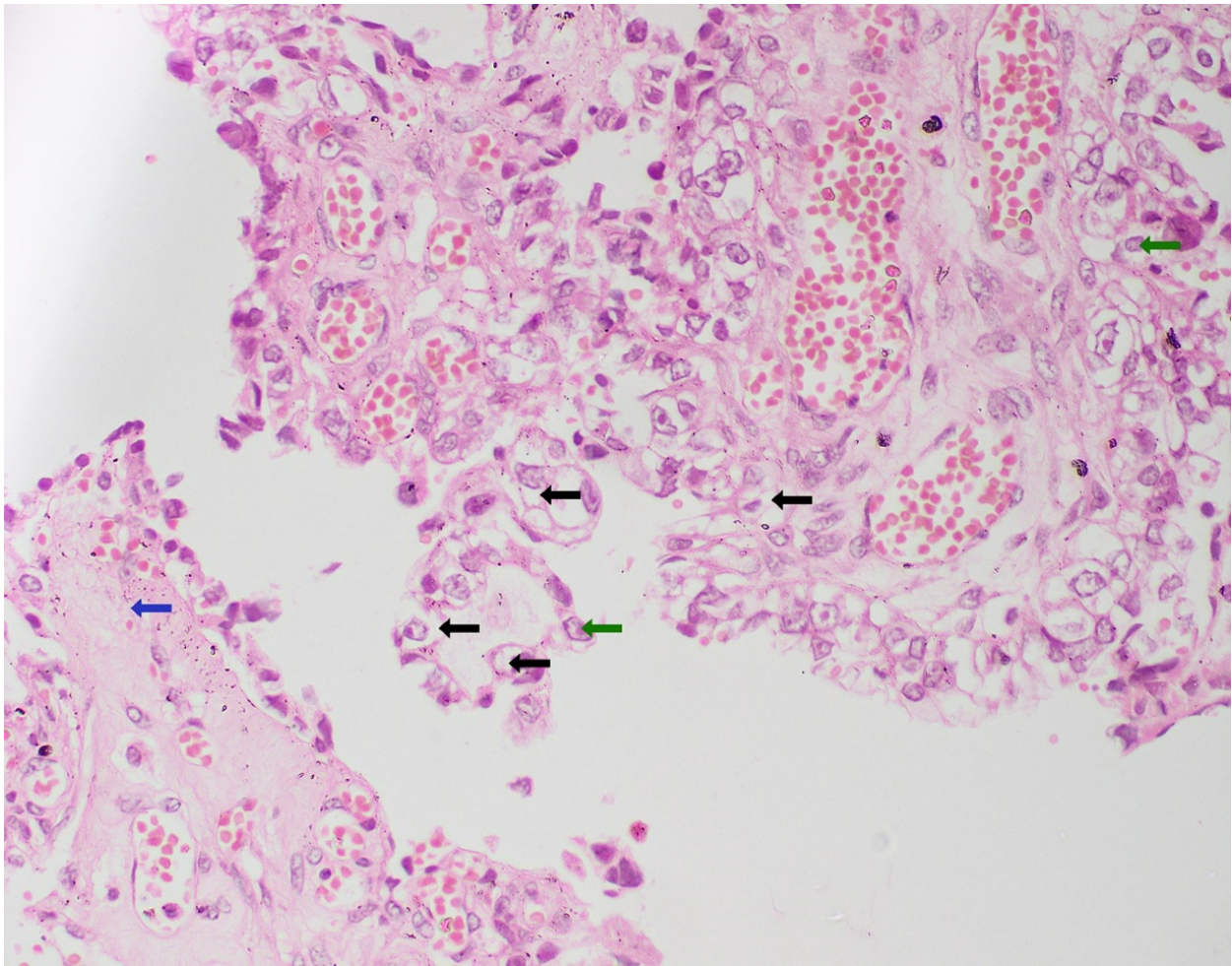


Figure 3. Histopathology of the tumour with haematoxylin and eosin stain showing papillary (blue arrow) structures lined by cells with clear cytoplasm (black arrows) and hobnail cells (green arrows).

Before discharge, she developed shortness of breath again. She was diagnosed with a pulmonary embolism involving the distal-most sub-segmental pulmonary arteries of both lower lobes, for which she received low molecular weight heparin. In the meantime, she was started on chemotherapy with paclitaxel, carboplatin, and bevacizumab.

Discussion

OCCC can be associated with a hypercoagulable state, manifesting with thrombosis and thromboembolism^[2]. The pathogenesis of DIC in OCCC is poorly understood^[2]. The expression of a procoagulant factor by malignant cells or the release of tissue factor by malignant cells can initiate the DIC^{[3][4]}. DIC is usually a complication of another disease, commonly a malignancy, that leads to unregulated coagulation pathway activation^[3]. D-dimer is frequently elevated with OCCC and is associated with a poor prognosis^[2]. This intravascular coagulation pathway activation manifests as a thrombotic obstruction of small vessels, leading to organ failure. This results in widespread bleeding due to the concurrent consumption of platelets and clotting factors^[3].

Most (90%) ovarian tumours have an epithelial origin^[5]. The lining of the ovaries and the fallopian tubes, known as the

coelomic epithelium, is assumed to be the source of epithelial ovarian cancer. OCCC is a less common subtype, accounting for 6% of ovarian epithelial carcinoma [1][5]. Although there are reports of other types of ovarian carcinoma with DIC, this is the first case report of OCCC associated with acute DIC. Acute DIC with intra-tumoral bleeding into a mixed serous papillary and endometrioid well-differentiated adenocarcinoma of the ovary has been reported [4]. A hypercoagulable state causing nonbacterial thrombotic endocarditis, leading to thromboembolic manifestations with DIC in patients with OCCC in a Caucasian patient, is described [1]. A patient with chronic DIC with recurrent cerebral thrombosis and OCCC, and another with recurrent cerebral thrombosis with ovarian cancer, have been reported [6][7]. A case report of ovarian mucinous cystadenocarcinoma associated with DIC complicating cerebral, peripheral, pulmonary, and coronary thrombotic events has been documented [8]. However, to our knowledge, no reported OCCC with acute DIC causing haemoperitoneum exists. Nevertheless, we are cautious in declaring a causal relationship.

Conclusions

In a patient with OCCC with low haemoglobin, bleeding due to DIC should be considered. Clear cell carcinoma, a subtype of ovarian epithelial carcinoma, can be associated with acute DIC, and acute DIC may be a complication of all ovarian cancers of epithelial origin.

References

1. ^{a, b, c}Oueida, Z., & Scola, M. (2011). *Ovarian clear cell carcinoma presenting as nonbacterial thrombotic endocarditis and systemic embolisation*. *World Journal of Oncology*, 2(5), 270–274. <https://doi.org/10.4021/wjon367e>
2. ^{a, b, c, d}Tamura, R., Yoshihara, K., Matsuo, K., et al. (2021). *Proposing a molecular classification associated with hypercoagulation in ovarian clear cell carcinoma*. *Gynecologic Oncology*, 163, 327-333. <https://doi.org/10.1016/j.ygyno.2021.08.009>
3. ^{a, b, c, d}Levi, M. (2018). *Pathogenesis and diagnosis of disseminated intravascular coagulation*. *International Journal of Laboratory Hematology*, 40, 15-20. <https://doi.org/10.1111/ijlh.12830>
4. ^{a, b}Matsushita, H., Kurabayashi, T., Tomita, M., Yamamoto, Y., Aoki, Y., & Tanaka, K. (2001). *Disseminated intravascular coagulation associated with intratumoral haemorrhage of ovarian cancer*. *Gynecologic and Obstetric Investigation*, 51(4), 274–276. <https://doi.org/10.1159/000058064>
5. ^{a, b}Auersperg, N., Wong, A. S., Choi, K. C., Kang, S. K., & Leung, P. C. (2001). *Ovarian surface epithelium: biology, endocrinology, and pathology*. *Endocrine Reviews*, 22(2), 255–288. <https://doi.org/10.1210/edrv.22.2.0422>
6. [^]Izumi, M., Terao, S., Takagi, J., Koshimura, J., Takatsu, S., & Mitsuma, T. (1996). *Favorable prognosis in a case of recurrent cerebral infarctions caused by chronic disseminated intravascular coagulation due to ovarian carcinoma*. *No To Shinkei*, 48(6), 581–585. <https://pubmed.ncbi.nlm.nih.gov/8703562/>
7. [^]Yeh, P-S., & Lin, H-J. (2004). *Cerebrovascular complications in patients with malignancy: report of three cases and review of the literature*. *Acta Neurologica Taiwanica*, 13(1), 34–38. <https://pubmed.ncbi.nlm.nih.gov/15315300/>
8. [^]Siegman-Igra, Y., Flatau, E., & Deligdish, L. (1977). *Chronic diffuse intravascular coagulation (DIC) in nonmetastatic*

ovarian cancer. Gynecologic Oncology, 5(1), 92–100. [https://doi.org/10.1016/0090-8258\(77\)90012-9](https://doi.org/10.1016/0090-8258(77)90012-9)