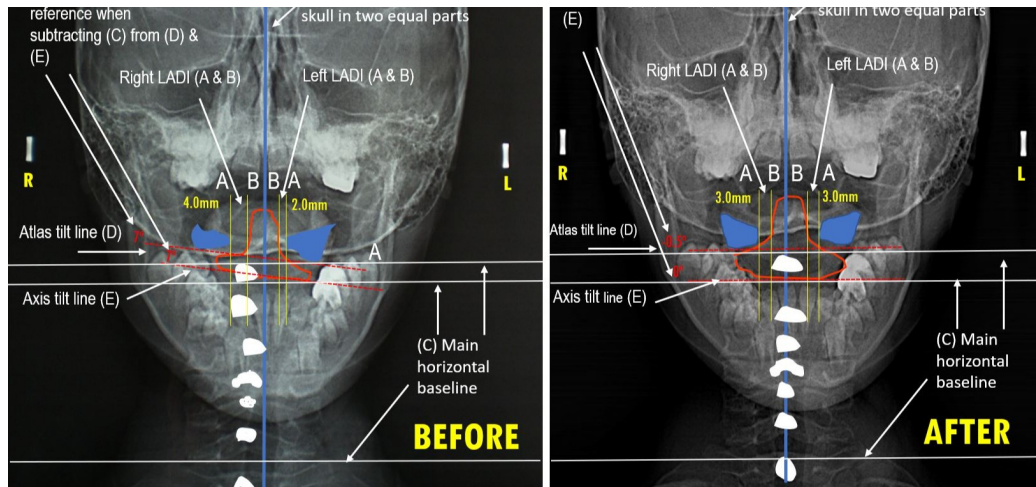

# Improvement in Cervical Spinal Misalignment After the Application of the Neuromuscular Atlasprofilax Method in one Single Session. A Case Report.

Lluís Manent<sup>1</sup>, José Gabriel León Higuera, orlando Angulo, Cristian Andres Garcia-Morcote, María Emma Zableh Solano<sup>2</sup>

<sup>1</sup> Health Sciences University Foundation

<sup>2</sup> Universidad Santo Tomás

**Funding:** The author(s) received no specific funding for this work.

**Potential competing interests:** Lluís Manent: Director of the Atlasprofilax Academy Switzerland Latin America corp. José G. León: Medical director of the Atlasprofilax Academy Switzerland Latin America Corp. Cristian Andrés García Morcote: Associated Director at Atlasprofilax Academy Switzerland Latin America corp. Orlando Angulo: reports no declaration of interest Kathleen Lewis: Practitioner of the Atlasprofilax Method María Emma Zableh: reports no declaration of interest declared that no potential competing interests exist.

## Abstract

A 7-year-old girl with diagnosed lateral mandibular deviation and other related temporomandibular joint disorders was referred for an anteroposterior x-ray examination to study a possible cervical spinal misalignment prior to the application of the Atlasprofilax method. The purpose of this radiographic examination was to assess probable improvement in her cervical spinal alignment after the application of the Atlasprofilax Method that already showed benefits in temporomandibular joint disorders and fibromyalgia in previous studies. Determination and probable improvement of Atlas and Axis tilt, lateral atlantodental asymmetry and cervical spinous processes misalignment were taken as endpoints. An x-ray examination was performed before the application of this method confirming Atlas and Axis tilt, lateral atlantodental asymmetry and cervical spinous processes misalignment from C2 to T1. The result in a posterior x-ray examination following the same radiological guidelines for anteroposterior open mouth examination determined a clear improvement in the Atlas and Axis tilt as well in the lateral atlantodontoid interval alongside with correction of the previously misaligned vertebrae of the cervical spine. Such radiological improvements on the

described structures poses the question on the benefits and clinical relevance of using specific targeted vibropressure used by the Atlasprofilax method on some key spots related to fascia and skeletal muscles. Thus, through a complex combination of mechanisms that involve mechanotransduction and cell metabolism, this clinical and non-invasive intervention could ameliorate preliminarily several ailments related to fascia and muscle skeletal disorders associated commonly with pain such temporomandibular disorders among others. Finally, it is relevant to the authors to raise awareness that it may be a gap between defining hard structures such as spine and joints asymmetries that cause pathological conditions and that can be observed by means of imaging such CT, MRI or x-ray examinations and the probable etiological underlying relationship coming from the understudied principles of fascial tensegrity. This etiology may include clinical or subclinical metabolic abnormalities in muscles, specially in the neck muscles but more specifically in the suboccipital muscles and its surrounding or inner soft tissues such as the myodural bridge.

## INTRODUCTION

A 7-year-old girl with diagnosed with lateral mandibular deviation and other related temporomandibular joint disorders was referred for an anteroposterior x-ray examination to study a possible cervical spinal misalignment prior to the application of the Atlasprofilax method and to assess probable improvement in her cervical spinal alignment after the application of the Atlasprofilax Method. The same x-ray examination was performed after the application of this method. The purpose of this examination was to determine if the Atlasprofilax method could produce an improvement in the spinal alignment of the cervical segment (C1 to C7) by means of x-ray examination after the application of this method in one single session. Neck disability has been associated with jaw dysfunction and chronic temporomandibular disorders (1,2), even in subjects that do not present symptoms in the neck region but do have signs of cervical spine dysfunction (3). Cervical hypolordotic misalignment, tendency toward cervical kyphosis, and postural deviations are associated clinical findings in TMD (4,5). Thus, clinicians do increasingly recommend additional examination of the craniocervical system to assess and treat upper cervical spine disorders that are commonly associated with temporomandibular dysfunction (6–8).

## CASE PRESENTATION

### ***1. Methods, measurements, and endpoints***

#### *1.1 Imaging examination: methods, measurements and endpoints*

The anteroposterior x-ray examination was performed following the guidelines defined by Murphy (9). The patient's head was immobilized with the device stabilizers, and x-ray images were taken before and after of the Atlasprofilax method within an interval of 57 days.

To determine the probable misalignment, the craniocervical centric line centered on the septum area in both examinations was taken as the reference line (F). The lateral masses of the Atlas were coloured in blue and a horizontal line in red (D) was drawn from one lower C1 facet, at its lowest contact point, to the contralateral one. The Axis shape was coloured (in

red) and another line in red (E) was drawn from the lowest contact point of the lower C2 facet to the contralateral one. Both red lines (D & E) were compared to a basal horizontal line (C) used as a reference. The spinous processes from C2 to C7 were drawn and coloured (in white) to determine their misalignment with respect to the reference of the caudal midline (F) of the craniocervical centric that was coloured in blue (See Figure 1). In addition, two vertical lines (A & B) in yellow were drawn to measure in mm and to compare prior vs. after the clinical intervention probable differences in the lateral atlantodontoid interval (LADI). The same radiological equipment was used in the same radiological clinic as well as the same radiological procedure to establish a valid comparison between the two examinations taken in an interval of 57 days prior and after the application of the Atlasprofilax method (See Figure 1 and Figure 2).

### *1.2 Clinical and radiographic examination: methods, endpoints and findings*

The patient was diagnosed by a specialized dentist in temporomandibular disorders (TMD) following Rocabado's diagnostic guidelines (10). The diagnose by means of a gnathostatic device was lateral mandibular deviation with following facial asymmetries: skeletal class III due to mandibular prognathism, retroinclination of lower incisors, mesial molar step specially in right side with decreased overjet and lower dental midline deviated to left side. Besides the diagnosis and the observed facial asymmetries the patient was in good physical condition, asymptomatic and pain-free. The patient was referred for open-mouth anteroposterior x-ray examination to determine probable spine misalignment. The purpose of the radiological examination was to determine if a previous cervical misalignment was present and if after the Atlasprofilax procedure could ameliorate a probable cervical spinal misalignment in the spinous processes from C2 to T1 as well as differences in the left vs. right LADI.

Thus, at imaging level, variations in distance of each vertebrae spinous process (C2-T1) from the craniocervical centric line in the coronal plane were taken as endpoints. Changes in the coronal visualization and presentation of the morphological structures of C1's lateral massae and Axis position such as tilt and LADI were also taken as endpoints. A vertical line in yellow was drawn at the most external point of each lateral mass of the Atlas (A) where the lateral mass was in closest proximity to the odontoid. Another vertical line in yellow was drawn at the at the odontoid neck (B) (See figure 1). Due to the anatomical variations in the shape of the odontoid process, which generally occur in its upper two thirds, the space to be measured between the inner edge of the lateral mass and the outer edge of the odontoid process is the one located at the neck of the odontoid process, i.e. the one located just on the line joining the narrowest edges of both lateral masses. Hence, the vertical alignment of the C2-C7 spinous processes in relationship with the craniocervical centric line, LADI (a)symmetries, and C1 and C2 tilt were the main endpoints to compare findings on the improvement of (a)symmetry and alignment of these structures before and after therapy.

## *2. Clinical and radiographic intervention*

The clinical intervention was done the 25<sup>th</sup> November 2013 and comprised a non-invasive neurostimulation with a special device by means of controlled vibropressure and percussion using specific frequencies with a soft tip. Prior to the intervention an anteroposterior x-ray examination was taken on the same day. The same x-ray examination was performed on 21<sup>st</sup> January 2014, 57 days after the application of the Atlasprofilax Method. The application was performed

once during six minutes on several specific spots of the suboccipital area to stimulate certain receptors involved in muscle reflex and fascia tensegrity targeting a profound mechanotransduction effect on the suboccipital muscles and the cervical fascial. The semispinatus muscles act as skeletal muscles transferring mechanical and elastic energy to the fascia and from there, to the periosteum and to the ligamentum nuchae. Controlled vibropressure on the semispinatus of the neck generates the regulation of cervical nociception inducing changes at the base of the skull and in the ligamentum nuchae. The vibration is transferred also to the suboccipital muscles and to the cervical fascia. The fascia that surrounds the semispinatus of the head has a high number of golgi tendons organs and amyelinic endings, thus responding to mechanical pressure and tension more efficiently than other structures. Vibration and mechanotransduction (11) in this area is transferred by different complex mechanisms to several muscles and muscle layers that are involved in the regulation of the vertebral proper alignment according to the principles of the fascia tensegrity (12).

### 3. Results (imaging findings and clinical findings)

#### 3.1 Imaging findings: Axis and Atlas tilt, cervical spinous processes misalignment, and LADI

##### *Imaging findings prior to the therapy:*

1. Tilt of Atlas and Axis: when examining the coronal plane prior to the application of the Atlasprofilax method, a tilt of  $7^{\circ}$  in the lateral massae of the Atlas bone (D) and a tilt of  $7^{\circ}$  in the Axis (E) can be seen (red dashed lines, See Figure 1) in comparison to the main horizontal baseline (C) (See Figure 1 and Table 1).

2. Deviation of C2 spinous process: A clear deviation of C2 spinal process in comparison to the vertical line dividing the skull in two equal parts across the septum (F) can also be easily observed. A tilt of the whole Axis vertebra probably also consistent with rotation and atlanto-rotatory subluxation is also observed in the first examination. Presentation or appearance in the shape of Atlas lateral massae shown to be asymmetrical (See Figure 1).

3. Deviation of C2 to T1 spinous processes: Before the therapy, all spinous processes from C2 to T1 were found to be clearly out of alignment when compared to the reference line (F). None of them was aligned within this craniocervical midline. All spinous processes from C2 to T1 presented a clear deviation from middle craniocervical line (See Figure 1).

4. LADI asymmetry: When observing LADI prior to therapy (lines A & B for left and right) an asymmetry consistent of 2 mm difference could be observed where left LADI was 4mm and right LADI was 2 mm (See Figure 1 and Table 1).

##### *Imaging finding after the therapy:*

In the posterior x-ray examination 57 days after the first x-ray examination and 52 days after application of the Atlasprofilax method following changes in the endpoints were observed:

1. Tilt of Atlas and Axis: the tilt of Atlas vertebra (D) when compared to the baseline (C) has gone down from  $7^{\circ}$  to  $-0.5^{\circ}$  while the Axis tilt has achieved a perfect match of  $0^{\circ}$  with the baseline (C), having previously a tilt of  $7^{\circ}$ . The shape of both Atlas lateral massae (coloured in blue) appear to be more symmetrical in comparison to the x-ray examination prior to therapy (See Figure 1 and Table 1).
2. Deviation of C2 spinous process: C2 spinous process appears to be centered and well aligned with the coronal vertical line (F) taken as reference for symmetry measurement (See Figure 1).
3. Deviation of C2 to T1 spinous processes: All spinous processes from C2 to T1 achieved a clearly improved alignment in concordance with and following the caudal craniocervical midline (F) (See Figure 1).
4. LADI asymmetry: when observing LADI (yellow lines A & B for left and right) after the application of the Atlasprofilax Method in one single session performed 57 days before, both LADIs (left and right) have achieved a perfect symmetry consistent of 3 mm each with no differences (See Figure 1 and Table 1).

## TABLES

Table 1. Comparison of asymmetries in LADI, C1 and C2 tilt prior and after the therapy

	LADI left in mm	LADI Right in mm	LADI difference in mm L vs. R	C1 tilt in degrees	C2 tilt in degrees
Before the therapy	2	4	2	7	7
After the therapy	3	3	0	-0.5	0

No side-effects related to the intervention were observed.

## DISCUSSION

### *Temporomandibular dysfunction and radiographic measurement of cervical spine:*

A sagittal cervical radiographic study comparing TMJD and non-TMJD patients found statistical difference in the TMJD patients group presenting flexion of the first cervical vertebra associated with an anteriorization of the cervical spine (13). Other cervical sagittal radiographic study found correlation between TMD and cervical hyperlordosis (4,14). Several studies and systematic reviews have found a relationship between TMJ-associated disorders and cervical spine abnormalities (15). Associated TMD-ailments are commonly arthralgia, myofascial pain, facial pain and neck pain. A decrease in C2–C7 Cobb and increase in the posterior occipito-cervical angle have been found to be associated with TMDs prevalence revealing that the cervical angle was related to TMDs (16). Radiographic studies associating cervical segment abnormalities with TMD are usually performed in the sagittal plane showing loss of spaces, alteration of physiologic angles and normal physiologic curvature of the cervical spine but do not show deviations of the vertebral

bodies or spinous processes with respect to an anteroposterior craniocervical centric.

TMD seems to have, according to multiple existing literature, a multifactorial etiology (17). Alterations in occlusion (18), psychological conditions, such as anxiety or depression (19), stress and other factors are commonly associated to TMD.

But an important part of TMD etiology remains associated to structural problems such forwarded head posture (20) or the Atlas vertebra alignment (13). Current available therapies for treating this condition and its symptoms seem have little influence on craniocervical posture but are effective when it comes to the relief of painful symptoms (21). A systematic review found strong evidence of craniocervical postural changes in myogenous TMD and moderate evidence of cervical postural misalignment in arthroogenous TMD (22). Interestingly, TMD have been linked to suboccipital muscle abnormalities (23). Fibromyalgia patients do also show a correlation with TMD (24,25) and neck pain (25). The Atlasprofilax method targets a restoration of suboccipital muscles abnormalities and a metabolic and functional improvement of cervical deep fascia and suboccipital muscle abnormalities as well as improvements of clinical or subclinical atlanto-rotatory subluxation (ARS) and asymmetry of the lateral atlantodental interval (LADI) (26). The Atlasprofilax method has been shown to be effective in reducing significantly and in a long-lasting manner fibromyalgia symptoms and achieving as well an exit of the 100% of the patients included in one study six months after the procedure out of the American College of Rheumatology's fibromyalgia classification and criteria (27). When looking at the effectiveness of Atlasprofilax in the amelioration of TMD-related symptoms in a sample of 151 patients (28) the results were a significantly alleviation of the symptoms in an average of 72,8% of the patients after one month. The group of patients who reported symptomatology related to noise, clicking and joint pain was reduced by more than half and bruxism by about 70%. In another case report of a 30-year-old woman suffering from TMD a computed tomography scan determined an atlantoaxial rotatory subluxation (ARS) and asymmetry of the lateral atlantodental interval (LADI) prior to the application of the Atlasprofilax method that was solved with this neuromuscular procedure together with a substantial improvement of TMD and other ailments (26).

*Atlasprofilax: a potential effective Method towards amelioration of cervical spine misalignment and against TMD symptoms?*

There is evidence linking various clinical manifestations and painful conditions to structural and metabolic deformations of the suboccipital muscles (29–35) . This soft tissue alterations and its link to painful conditions could be correlated or consistent with clinical or subclinical ARS and LADI (26).

Cervical spine mechanical and metabolic alterations trough muscle chains and fascial continuum could be the result from abnormalities at the CCJ level affecting proximal regions such as the TMJ and more distal regions such as the upper limb and neck giving as a result a metabolic-mechanical posture alteration. This phenomenon is linked with musculoskeletal pain, fibromyalgia (36) and cervicogenic tension-type headache (37) without excluding many other ailments. Since the Atlasprofilax method is designed to ameliorate metabolic and structural alterations of the soft tissues and bony structures at the occipito-cervical hinge, an improvement of the clinical manifestations associated with the pathophysiology of this

region and other distal (37) or proximal regions connected to it is to be expected as demonstrated by certain studies and case reports already mentioned.

There is growing scientific evidence on the role of the fascial network in distally spreading CCJ-related abnormalities (38). Fascia cannot be separated from joints, viscera, muscles, tendons and meninges, conforming and integrity network of body's anatomy and biomechanics (39–41) including nociception and interoception that are interlinked with the extracellular matrix (42). Thus, the use of specific sustained vibropressure by means of a special device in key spots of the suboccipital muscles and deep cervical fascia may constitute a novel therapeutic approach in the restoration of metabolic and structural abnormal patterns in the upper cervical spine.

This way, the mechanotransduction mechanisms used by the Atlasprofilax method would have some benefits in the response to mechanical signals from the extra cellular matrix, transmitting the signal to the cytoskeleton an turn into changes of the fascia and muscle cellular biochemistry (43) while ameliorating tension and symmetry in the function of the muscle responsible for bones or vertebrae proper alignment, thanks to the application of certain mechanical forces with specific frequencies exerted on the fascia (12), alleviating pain and ameliorating function and range of movement. This soft tissue restoration can turn in better vertebral alignment not only in the craniocervical hinge but also in the temporomandibular joint and the whole spine due to a restoration of muscle and fascia properties involved in mechanical loads linked to certain muscles that, when biochemically and mechanically altered, can lead to spinal misalignment. Atlasprofilax can shed light on the use of mechanotransduction and its physiological and therapeutic mechanisms for the treatment of various health problems associated with benign chronic pain with implications between musculoskeletal such as TMD-related dysfunctions and the complex functioning of cellular and metabolic interactions of the fascial network. Soft tissue non-invasive myofascial and or neuromuscular interventions have the potential of ameliorating not only the soft tissue cellular condition and associated pain but also the dysfunction and chronic pathological asymmetries in bony or hard structures. The problem is that, apart from MRI by diffusion tensor imaging, the most common imaging techniques such as x-rays and CT can only mainly focus on hard structures such as joints and bones. But when it comes to visualizing soft structures, its level of accuracy in determining cellular physiological or pathophysiological conditions of tissues such as fascia, tendons or muscles at a metabolic level is not enough to provide evidence of pathology or abnormality nor to deliver ways for measuring changes of relevance when beneficial non or minimal-invasive therapeutical interventions on soft tissues are delivered. Thus, to explain how the structural changes in bony structures can occur so quickly when observing clear previous existing asymmetries that turn into a post-therapy much enhanced symmetry -in one single intervention that lasted 6 minutes consisting of non-invasive vibropressure by mechanotransduction - could most probably only be explained through cellular and metabolic mechanisms involving the external stimulus into the vast unexplored field of fascia and its tensegrity principles. In order to explain this particular mechanism, MRI by diffusion tensor imaging and new imaging technologies should be put in place beyond the scope of most commonly used x-ray and CT examination.

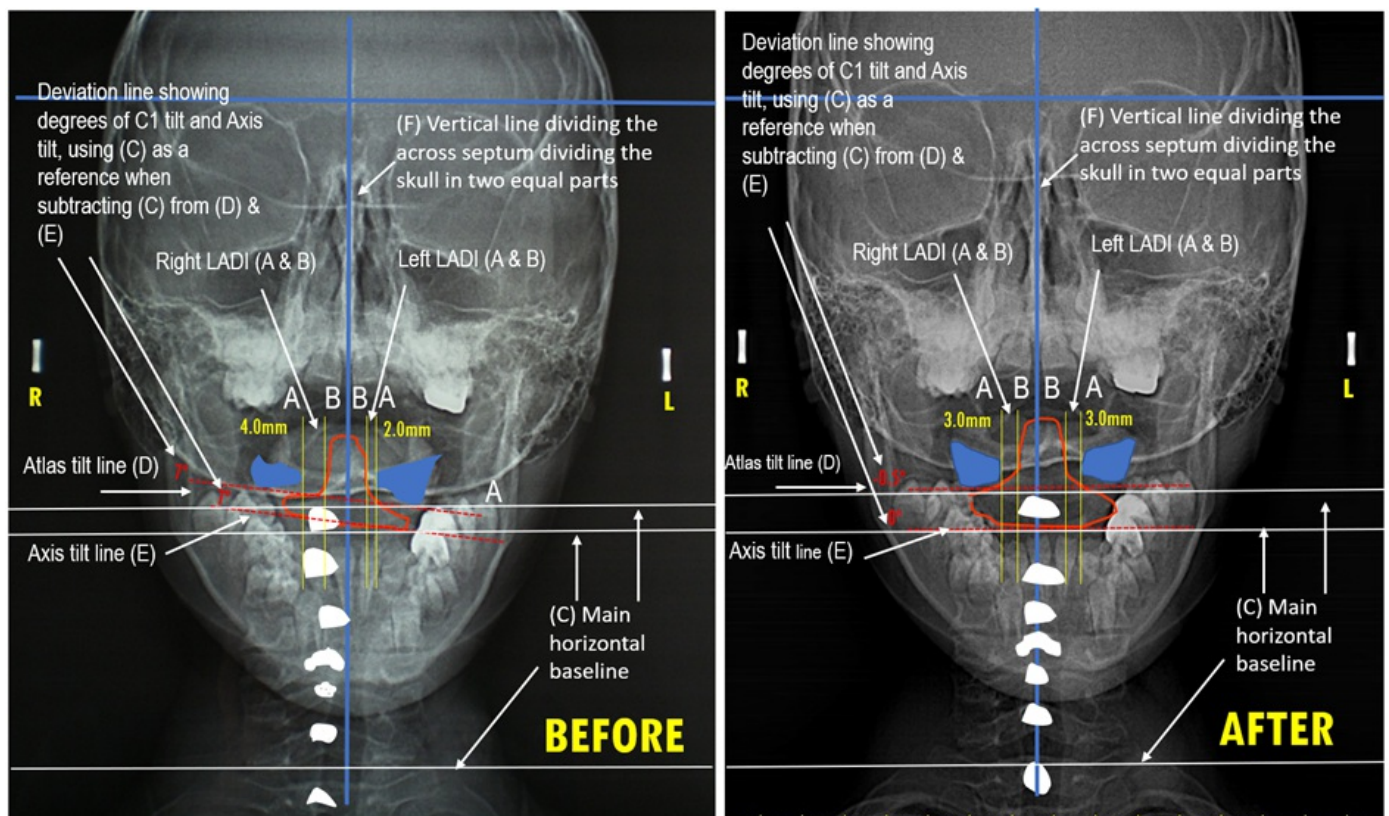
## CONCLUSIONS

This case report shows LADI asymmetry, alongside with C1 and C2 tilt, and a deviation with a clear misalignment from C2 to T1 in the cervical spine which is corrected in a single session through the Atlasprofilax method and can be visualized by means of an anteroposterior radiographic examination.

The physiological and anatomical biomechanical interactions between the CCJ, the suboccipital muscles and the temporomandibular joint are well known. Atlasprofilax is a therapeutic intervention that focuses on the treatment of abnormalities and restoration of the suboccipital muscles and deep cervical fascia. This can lead, as in this case, to an improvement in the alignment of the craniocervical bony structures and the spine through non-invasive stimulation by vibropressure and mechanotransduction in the suboccipital region. This improvement may result in the relief of symptomatic or presymptomatic manifestations of TMDs.

The Atlasprofilax method has already shown improvements in previous case reports and studies on TMD, fibromyalgia, cervicobrachialgia and herniated discs. Although the evidence is still limited, larger studies are recommended to determine the therapeutic scope of this method and its spectrum of applications in musculoskeletal pathologies of benign and myofascial origin.

## FIGURES

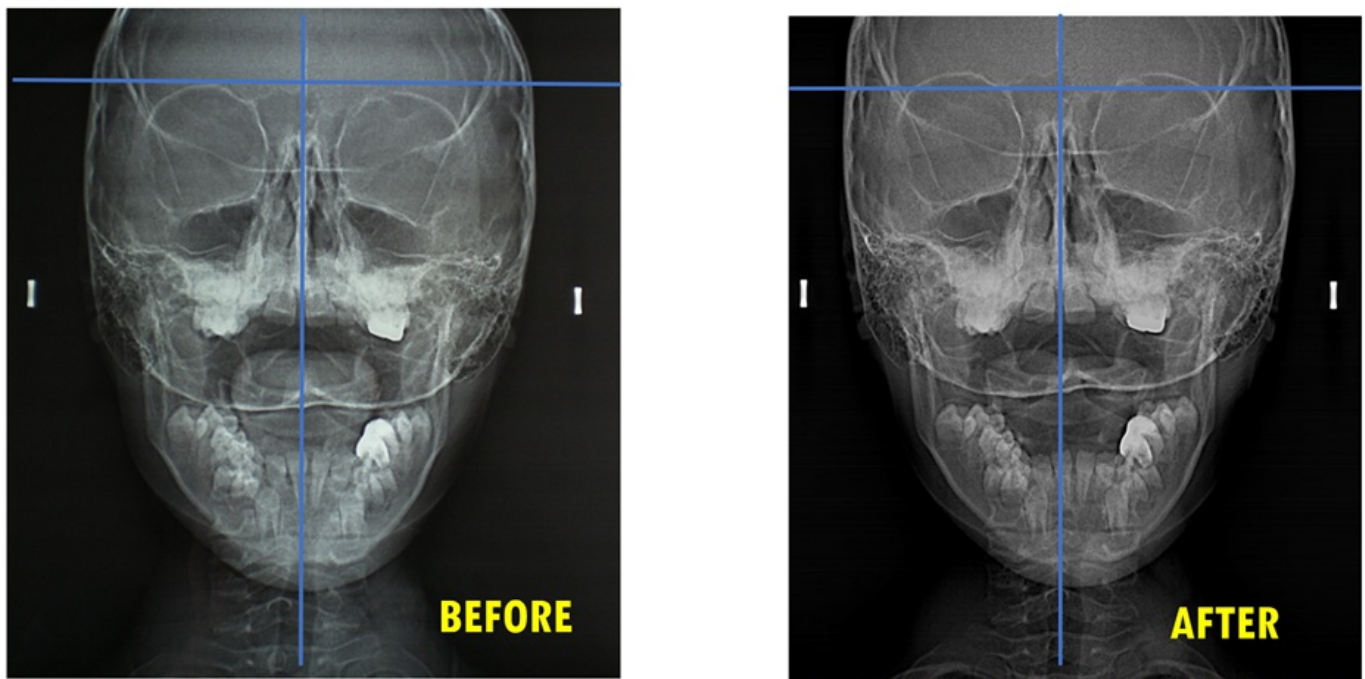


**Figure 1:** (Left image: before intervention) Anteroposterior view x-ray examination before the application of the



Atlasprofilax Method. A 7° tilt of the Atlas lateral massae as well as of the Axis vertebrae can be seen clearly (red dashed lines). Left vs. right LADI is clearly 2-fold asymmetrical by 2mm (vertical A & B yellow lines). C2's spinous process is clearly out of the craniocervical midline (vertical line in blue taking the septum as reference) indicating probable rotation of C2. C3 to C7 (and also T1) appear to be clearly out of alignment in relationship with the craniocervical midline (F) (vertical line in blue taking the septum as reference) indicating cervical vertebrae misalignment.

(Right image: after intervention) Same anteroposterior view x-ray examination 57 days after the first examination and 52 days after the Atlasprofilax Method application. Atlas' lateral massae do not show previous tilt and appear to be normalized and closer to orthogonality (red dashed lines) going from a previous tilt of 7° down to -0.5° after the intervention. Same occurs to C2 tilt (red dashed lines) where the previous tilt of 7° appears to be normalized to 0°. Left vs. right LADI is normalized and appears to be symmetrical by 3 mm in both L/R LADIs (vertical A & B yellow lines; 0 mm asymmetry) after the clinical intervention. C2's spinous process (coloured in white) appears now to be well-aligned centered with the craniocervical midline (vertical in blue taking the septum as reference). C3 to C7 (and also T1) appear to be after the procedure well-aligned in relationship with the craniocervical midline (vertical in blue taking the septum as reference) indicating a proper cervical vertebrae alignment.



**Figure 2:** Same figure per figure 1 but without measurements.

### Authors' contributions

**Lluís Manent:** Writing - original draft, review & editing, supervision; **José G. León:** Conceptualization, Supervision; **Cristian Andrés García Morcote:** reviewing, editing, supervision; **Orlando Angulo:** reviewing, editing, supervision; **María Emma Zableh Solano:** Conceptualization, Supervision

## Acknowledgements

We want to posthumously thank Dr. Victoria Gutiérrez Navast† for her contribution to this work.

## Consent

Written informed consent from the participant subject was obtained.

## Human and animal rights

As an observational case report, no experiments were performed on human subjects. Nevertheless; this case study is within the ethical standards of the Helsinki Declaration of 1975, as revised in 2000.

## Keywords

Atlantoaxial rotatory subluxation; Cervical spine, Lateral atlantodental interval; Odontoid-lateral mass interspaces asymmetry; Atlasprofilax; Mechanotransduction; Craniocervical joint; Fascia; Vertebral subluxation; Suboccipital muscles, Temporomandibular disorder.

## Abbreviations

ARS= Atlantoaxial rotatory subluxation

CCJ= Craniocervical joint

CT= Computed tomography

ECM= Extracellular matrix

LADI= Lateral atlantodental interval

TMJD= Temporomandibular joint disorder

## REFERENCES

1. Silveira A, Gadotti IC, Armijo-Olivo S, Biasotto-Gonzalez DA, Magee D. Jaw dysfunction is associated with neck disability and muscle tenderness in subjects with and without chronic temporomandibular disorders. *Biomed Res Int*. 2015;2015.
2. K. W-D, S. B, A. N-B, E. T. Correlation between TMD and cervical spine pain and mobility: Is the whole body balance TMJ related? *Biomed Res Int* [Internet]. 2014;2014. Available from: [http://europepmc.org/search?query=\(DOI:10.1155/2014/582414\)%0Ahttp://www.hindawi.com/journals/bmri/2014/582414/%0Ahttp://doi.org/10.1155/2014/582414](http://europepmc.org/search?query=(DOI:10.1155/2014/582414)%0Ahttp://www.hindawi.com/journals/bmri/2014/582414/%0Ahttp://doi.org/10.1155/2014/582414)
3. Fink M, Tschernitschek H, Stiesch-Scholz M. Asymptomatic Cervical Spine Dysfunction (CSD) in Patients with Internal Derangement of the Temporomandibular Joint. *Cranio*. 2002;20(3):192–7.
4. Coskun Benlidayi I, Guzel R, Tatli U, Salimov F, Keceli O. Relationship between cervical angle and

- temporomandibular disorders in young and middle-aged population. *Cranio - J Craniomandib Pract.* 2020;38(3):174–9.
5. Saito ET, Akashi PMH, De Sacco ICN. Global body posture evaluation in patients with temporomandibular joint disorder. *Clinics.* 2009;64(1):35–9.
  6. Stiesch-Scholz M, Fink M, Tschernitschek H. Comorbidity of internal derangement of the temporomandibular joint and silent dysfunction of the cervical spine. *J Oral Rehabil.* 2003;30(4):386–91.
  7. Grondin F, Hall T, Laurentjoye M, Ella B. Upper cervical range of motion is impaired in patients with temporomandibular disorders. *Cranio - J Craniomandib Pract.* 2015;33(2):91–9.
  8. De Wijer A, Steenks MH, De Leeuw JRJ, Bosman F, Helders PJM. Symptoms of the cervical spine in temporomandibular and Cervical Spine Disorders. *J Oral Rehabil.* 1996;23(11):742–50.
  9. Murphy A. Cervical spine (odontoid view). In: Radiopaedia.org [Internet]. Radiopaedia.org; 2018. Available from: <http://radiopaedia.org/articles/58730>
  10. Rocabado M. Análisis biomecánico cráneo cervical a través de una teleradiografía lateral. *Rev Chil Ortod.* 1984;1:1–11.
  11. Ingber DE. Tensegrity and mechanotransduction. *J Bodyw Mov Ther.* 2008;12(3):198–200.
  12. Bordoni B, Varacallo M, Morabito B, Simonelli M. Biotensegrity or Fascintegrity? *Cureus.* 2019;
  13. De Farias Neto JP, De Santana JM, De Santana-Filho VJ, Quintans-Junior LJ, De Lima Ferreira AP, Bonjardim LR. Radiographic measurement of the cervical spine in patients with temporomandibular dysfunction. *Arch Oral Biol.* 2010;55(9):670–8.
  14. Munhoz WC, Marques AP, Siqueira JTT de. Radiographic evaluation of cervical spine of subjects with temporomandibular joint internal disorder. *Pesqui Odontol Bras.* 2004;18(4):283–9.
  15. Olivo SA, Bravo J, Magee D J, Thie N M, Major P W, Flores Mir C. The Association between head and cervical posture and temporomandibular disorders : a systematic review. *J Orofac Pain.* 2006;20(1):9–23.
  16. Gao D, Zhang S, Kan H, Zhang Q. Relationship between cervical angle and temporomandibular disorders in young and middle-aged population. *CRANIO®* [Internet]. 2022 Mar 15;1–7. Available from: <https://www.tandfonline.com/doi/full/10.1080/08869634.2022.2049544>
  17. Oral K, Küçük BB, Ebeoğlu B, Dinçer S. Etiology of temporomandibular disorder pain. *Agri.* 2009;21(3):89–94.
  18. Thilander B, Rubio G, Pena L, De Mayorga C. Prevalence of Temporomandibular Dysfunction and Its Association with Malocclusion in Children and Adolescents: An Epidemiologic Study Related to Specified Stages of Dental Development. *Angle Orthod.* 2002;72(2):146–54.
  19. Ohrbach R. Anxiety and Depression in Adolescents and Their Relationship With Signs and Symptoms of Temporomandibular Disorders. *Yearb Dent.* 2006;2006:329–30.
  20. J.A. H, A.M. R. Head posture and cervicovertebral and craniofacial morphology in patients with craniomandibular dysfunction. *Cranio* [Internet]. 1992;10(3):173–9. Available from: <http://www.embase.com/search/results?subaction=viewrecord&from=export&id=L22980474>
  21. Cunha MMF da, Peixoto KO, Resende CMBM de, Costa MPS do N da, Carvalho ALO de, Melo RA, et al. Effects of therapies for temporomandibular disorder on the craniocervical posture: A randomized clinical trial. *Res Soc Dev.* 2021;10(4):e36210411512.

22. Chaves TC, Turci AM, Pinheiro CF, Sousa LM, Grossi DB. Static body postural misalignment in individuals with temporomandibular disorders: A systematic review. *Brazilian J Phys Ther.* 2014;18(6):481–501.
23. Assche R Van, Von B, Klein P. Interaction between Suboccipital Muscles and TMJ Muscles. 2006.
24. Velly AM, Look JO, Schiffman E, Lenton PA, Kang W, Messner RP, et al. The effect of fibromyalgia and widespread pain on the clinically significant temporomandibular muscle and joint pain disorders-a prospective 18-month cohort study. *J Pain.* 2010;11(11):1155–64.
25. Yunus MB. The prevalence of fibromyalgia in other chronic pain conditions. *Pain Res Treat.* 2012;2012.
26. G León J, Manent L, Lewis K, Angulo O. Clinical and Imaging Improvement After the Atlasprofilax Method in a Patient with Cervicobrachial Syndrome and Temporomandibular Joint Disorders. A Case Report. *Acta Sci Orthop.* 2021;4(10):92–102.
27. Malagón J, Villaveces M, Manent L. A Therapeutic Alternative in the Management of Fibromyalgia. *Rev Cuarzo.* 2017;23(1):30.
28. Gutiérrez Navas VE. EFECTO DE LA TERAPIA AtlasPROFILAX® SOBRE LOS SÍNTOMAS RELACIONADOS CON DISFUNCIÓN TEMPOROMANDIBULAR, BRUXISMO Y LA RELACIÓN DE LAS LÍNEAS MEDIAS DENTALES. *UstaSalud.* 2013;12(2):124.
29. Fernández-De-Las-Peñas C, Cuadrado ML, Arendt-Nielsen L, Ge HY, Pareja JA. Association of cross-sectional area of the rectus capitis posterior minor muscle with active trigger points in chronic tension-type headache: A pilot study. *Am J Phys Med Rehabil.* 2008;87(3):197–203.
30. Andary MT, Hallgren RC, Greenman PE, Rechten JJ. Neurogenic atrophy of suboccipital muscles after a cervical injury. *Am J Phys Med Rehabil.* 1998;77(6):545–9.
31. Elliott J, Jull G, Noteboom JT, Darnell R, Galloway G, Gibbon WW. Fatty infiltration in the cervical extensor muscles in persistent whiplash-associated disorders: A magnetic resonance imaging analysis. *Spine (Phila Pa 1976).* 2006;31(22).
32. Rick Hallgren. Magnetic Resonance Imaging of the Upper Cervical Spine. Detection of Atrophic Changes in Rectus Capitis Posterior Minor Muscles. *Chiropr Ressour Organ [Internet].* Available from: [https://chiro.org/Headache/Magnetic\\_Resonance\\_Imaging.html](https://chiro.org/Headache/Magnetic_Resonance_Imaging.html)
33. Elliott JM, Pedler AR, Jull GA, Van Wyk L, Galloway GG, O'leary SP. Differential changes in muscle composition exist in traumatic and nontraumatic neck pain. *Spine (Phila Pa 1976).* 2014;39(1):39–47.
34. Yuan XY, Yu SB, Liu C, Xu Q, Zheng N, Zhang JF, et al. Correlation between chronic headaches and the rectus capitis posterior minor muscle: A comparative analysis of cross-sectional trail. *Cephalalgia.* 2017;37(11):1051–6.
35. Fernández-De-Las-Peñas C, Alonso-Blanco C, Cuadrado ML, Gerwin RD, Pareja JA. Myofascial trigger points and their relationship to headache clinical parameters in chronic tension-type headache. *Headache.* 2006;46(8):1264–72.
36. K.D. J, L.A. K, S.D. M, R.M. B, F.B. H. Postural control deficits in people with fibromyalgia: A pilot study. *Arthritis Res Ther [Internet].* 2011;13(4). Available from: <http://arthritis-research.com/content/13/4/R127%5Cnhttp://ovidsp.ovid.com/ovidweb.cgi?T=JS&PAGE=reference&D=emed10&NEWS=N&AN=2011533462>
37. León JG, Manent L, Lewis K, Angulo O. Total Resorption of a Chronic L4-L5 Disc Extrusion After Application of

the Atlasprofilax Method: A Case Report. *Am J Case Rep.* 2022;23.

38. Sutcliffe P, Lasrado S. Anatomy, Head and Neck, Deep Cervical Neck Fascia. *StatPearls [Internet]*. 2020; Available from: <http://www.ncbi.nlm.nih.gov/pubmed/31082135>
39. Schleip R, Findley TW, Chaitow L, Huijing P. Fascia: The Tensional Network of the Human Body: The science and clinical applications in manual and movement therapy. *Fascia Tens Netw Hum Body Sci Clin Appl Man Mov Ther.* 2012;1–535.
40. Cathcart E, McSweeney T, Johnston R, Young H, Edwards DJ. Immediate biomechanical, systemic, and interoceptive effects of myofascial release on the thoracic spine: A randomised controlled trial. *J Bodyw Mov Ther.* 2019;23(1):74–81.
41. Bordoni B, Myers T. A Review of the Theoretical Fascial Models: Biotensegrity, Fascintegrit, and Myofascial Chains. *Cureus.* 2020;
42. Wang HQ, Li XK, Wu ZX, Wei YY, Luo ZJ. The effect on the extracellular matrix of the deep fascia in response to leg lengthening. *BMC Musculoskelet Disord.* 2008;9.
43. Cheng B, Lin M, Huang G, Li Y, Ji B, Genin GM, et al. Cellular mechanosensing of the biophysical microenvironment: A review of mathematical models of biophysical regulation of cell responses. *Phys Life Rev.* 2017;22–23:88–119.