

[Open Peer Review on Qeios](#)

Computed Tomography Imaging of COVID-19 Vaccination–related Axillary Lymphadenopathy: Updated Review of Literature

Som Biswas¹, Srirupa Biswas

¹ Le Bonheur Children's Hospital

Funding: No specific funding was received for this work.

Potential competing interests: No potential competing interests to declare.

Abstract

As of September 2022, approximately 606 million cases of COVID-19 have been reported and 6.5 million deaths have occurred worldwide [1]. COVID-19 vaccination programs are in progress around the world to control the pandemic [2]. Till September 2022 approximately 12.6 billion doses of the vaccine have been globally administered [3]. It has been found that reactive hyperplasia of the ipsilateral axillary nodes and sometimes contralateral node is a side effect of vaccination [4]. The frequency of imaging-detected lymphadenopathy ranged between 14.5 to 53% [5]. Cancer patients undergoing active treatment or follow-up surveillance undergo frequent cross-sectional imaging which incidentally detects vaccine-related lymphadenopathy. A Chest CT scan is the most used imaging modality for lung cancer monitoring and lung screening for metastasis of other malignancies. Thus, incidentally detected COVID-19-associated axillary lymph node enlargement is seen in these patients who undergo frequent chest CT scans including the axilla. It is difficult to differentiate lymph node enlargement due to Covid vaccination from lymph node metastasis on imaging. This can lead to unnecessary fine needle aspiration cytology or biopsy thus increasing the patient's cost and public health burden [6][7][8].

This systematic review aims to evaluate the published literature evidence of axillary lymphadenopathy after COVID-19 vaccination and its imaging features on Chest CT.

Keywords: Computed Tomography, Imaging, COVID-19 Vaccination–related Axillary Lymphadenopathy, Review.

The systematic review was performed as per the PRISMA guidelines and checklist. Since this was a systematic review, institutional review board approval was not needed. PubMed database was searched for relevant English language articles up till September 2022. The search terms "Vaccine" OR "Vaccination" AND "Axillary Lymphadenopathy" OR "Axillary Lymph node" AND "Covid-19" AND "CT Chest". 7 studies or reports were identified using the predefined keywords. One of them described myocardial perfusion imaging findings and others described PET/CT imaging findings. Only 1 study was initially found to describe exclusively CT chest findings of covid 19 associated axillary lymphadenopathy.

From the “similar articles section” of this paper few additional studies were found describing CT chest findings in covid 19 associated axillary lymphadenopathy. Studies that described findings on ultrasound or mammography or PET/ CT or MRI were included only if Chest CT images were also described. Studies describing non-axillary lymphadenopathy were excluded. Letter to Editors, conference abstracts, and non-research articles (such as opinions and commentaries) were excluded. Identical articles and abstracts were identified to avoid duplication. Similar studies published by the same institution were analyzed and only the most recent comprehensive study was included to avoid data duplication. Data extraction was performed by 3 investigators independently and results were cross-checked and merged for analysis.

Ahn et al. describe Axillary Lymphadenopathy after mRNA COVID-19 Vaccination on CT Chest images^[9]. It occurred 7 days after the second dose of mRNA COVID-19 in a 32-year-old man. The lymph node measured 15mm in its short axis. Axial CT Chest imaging in a 39-year-old woman initially revealed normal lymph nodes. However, 8 days after vaccination with mRNA Covid-19 vaccine patient demonstrated left axillary lymph nodes measuring 1.4 cm on the short axis. All patients were asymptomatic.

Lane et al. describe COVID-19 Vaccine-Related Axillary Lymphadenopathy in Patients with Current or Prior Breast Cancer and Other Malignancies on Cross-Sectional Imaging including MRI, CT, and PET-CT. They found that vaccination can cause level I-III axillary lymphadenopathy ^[10]. They found axillary adenopathy in the left level II axilla lymph node in a 70-year-old female with a history of right breast cancer and bilateral mastectomy. Enlarged lymph nodes were seen five days after the second COVID-19 vaccine. Follow-up ultrasounds showed an enlarged lymph node with focal cortical bulge and loss of fatty hilum.

Viana et al. ^[11] describe the first Brazilian case report of post-COVID-19 adenopathy within 24 hours of the COVID-19 vaccine. The patient developed fever, axillary discomfort, and also a convulsion episode after administration of the Pfizer BioNTech COVID-19 vaccine in the right arm. He underwent Chest computer tomography on the same day which showed axillary fat standing with lymph node enlargement.

Nishino et al. ^[11] utilized prevaccine and postvaccine chest CT data of lung cancer patients who had received two doses of mRNA-based COVID-19 vaccinations. The incidence rate was found to be 9%. The median time of development of lymph node enlargement was 1.7 weeks after the second booster shot. Vaccine type (mRNA1273 vaccine) and female sex were revealed to be predisposing factors. The median number of enlarged nodes was four and the median short-axis diameter of the largest node was 7 mm.

Yu et al. ^[11] present a misdiagnosed case of lymphadenopathy after COVID-19 vaccination from SinoVac. 34-year-old lady presented with left axillary pain and fever. She received her first and second doses of the SinoVac COVID-19 vaccine five and four months ago respectively. Both doses were administered to the left arm. She developed left axillary swelling and pain. Computer tomography demonstrated left axillary lymphadenopathy. Follow-up was performed using ultrasound which showed an initial increase in the size of the lymph nodes. Initial ultrasounds misreported necrotic lymph nodes and fine needle aspiration cytology was negative for tuberculosis or malignancy. Follow-up ultrasound showed a decrease in the size of the lymph nodes and eventual resolution after 8 months. The lymphadenopathy was attributed finally to side effects of the COVID-19 vaccine based on clinical, imaging, and histopathological findings, and this was confirmed in the

prognosis as it resolved on its own.

Placke et al. [12] studied 8 patients with melanoma or Merkel cell carcinoma who underwent lymph node excision and received Covid-19 vaccination within 6 weeks before surgery. They found that the lymphadenopathy images of Covid-19 were similar to lymph nodal metastasis.

Wolfson et al. [13] studied 1217 patients who had taken Covid-19 vaccine and had undergone breast imaging. 9% (29 patients) had lymph node enlargement identified with mammography alone, 61% (203 patients) had lymph node enlargement detected on sonography. 44 % (537 patients) had lymph node enlargement on atleast one imaging. The average lymph node size was 1.8 cm. Lymphadenopathy was typically seen within 14 days of vaccination and was rare after 50 days of second dose.

The majority of lymphadenopathy after Moderna vaccination occurred within 2 to 4 days and radiological observations lasted between 4 days to 10 weeks. The lymphadenopathy that occurred with Sinovac vaccine occurred at 4 months and resolved at 8 months. All the studies discussed above had initial CT chest imaging. The CT features of Covid axillary lymphadenopathy in all these studies were similar to lymph nodal metastasis or any other infectious cause of lymph node enlargement. Follow-up by ultrasound was done, which showed resolution of lymphadenopathy in all the studies without any treatment, confirming COVID-19 as the etiology.

Guidelines and algorithms for management of lymphadenopathy in current setting of Covid-19 vaccinations - Current Society of Breast Imaging Guidelines [14]:

1. For average-risk women with screening-detected ipsilateral lymphadenopathy and no other suspicious mammographic findings: Assess as BI-RADS 2, no dedicated follow-up
2. At short-term imaging follow-up (≥ 12 weeks): If improving lymphadenopathy, assess as BI- RADS 2
3. At short-term imaging follow-up (≥ 12 weeks): If unchanged lymphadenopathy, assess as BI-RADS 3, consider additional 6-month follow-up If increased lymphadenopathy, then consider lymph node sampling

Schiaffino et al. [15] recommended in European Society of Breast Imaging that 1) vaccination should be administered in the contralateral arm or in the thigh in cases with previous history of breast cancer, (2) all vaccination data has to be collected for all patients referred to breast imaging services (3) breast imaging examinations should be performed before vaccination or at least 12 weeks after the last vaccine dose; (4) apply standard imaging protocols regardless of vaccination status in newly diagnosed breast cancer, (5) in any case of symptomatic or imaging-detected axillary lymphadenopathy before vaccination or at least 12 weeks after, examine with appropriate imaging the contralateral axilla and both breasts to exclude malignancy; (6) perform standard work-up in case of axillary lymphadenopathy contralateral to the vaccination side, (7) Lymphadenopathy only ipsilateral to the vaccination side within 12 weeks after vaccination can be considered benign or probably-benign, in patients without breast cancer history and no suspicious breast imaging findings, (8) post-vaccination lymphadenopathy coupled with suspicious breast finding requires standard work-up, including biopsy when appropriate in patients without breast cancer history, (9) interpret lymphadenopathy considering the timeframe from vaccination and overall nodal metastatic risk in patients with breast cancer history, interpret and manage

post-vaccination (10) complex or unclear cases should be managed by the multidisciplinary team.

Zhang et al. [16] have state in their paper that risk-based management algorithm scan significantly reduced unnecessary biopsies in low-risk patients. They also describe the imagin features to differentiate benign from malignant lymphadenopathy. In axilla not only the size but the morphology of the lymph node including its shape, cortical thickness, uniformity, and presence or absence of central fatty hila are considered important criteria for differentiating normal from abnormal lymph nodes. Normal and benign nodes appear oval or reniform, with cortical thickness less than or equal to 3 mm and a preserved fatty hilum. Ultrasound evaluation and classification of axillary lymph nodes based on the cortical thickness and appearance of the hilum have been found to be more accurate in predicting malignancy than overall size of the lymph node. Nodal vascularity at color Doppler US also helps distinguish benign from metastatic lymph nodes, with benign nodes demonstrating hilar perfusion and most metastatic nodes demonstrating eccentric or peripheral perfusion. Patients with active breast cancer should be evaluated with standard imaging protocols regardless of vaccination status.

Ryogo Minamimoto et al. [17] describe in their paper the imaging features of FDG-PET/CT imaging after Covid-19 vaccination. There is normal to moderate increase in lymph node size with thickening of cortex and fatty hilum, suggesting benign lesions. Sometimes the lymph node can show abnormal size or loss of fatty hilum shortly after vaccination that can be confused for malignancy. FDG uptake has been shown in axillary lymph nodes following vaccination. It tends to occur within 7 dasy of vaccination and resolves by 12-14 days. It can even persisit for 10 weeks. Generally ipsilateral lymph nodes are involvd however contralateral lymph nodes can also be affected.

Cohen *et al.* [18] categorized vaccine-associated hypermetabolic lymphadenopathy (VAHL) according to the intensity and area of FDG uptake in axial lymph nodes as follows: grade 1, mild FDG-uptake intensity ($SUV_{max} < 2.2$); grade 2, moderate FDG-uptake intensity ($2.2 \leq SUV_{max} < 4$); grade 3, high FDG- uptake intensity ($SUV_{max} \geq 4$) in normal-size nodes; and grade 4, high FDG-uptake intensity ($SUV_{max} \geq 4$) in enlarged nodes. The incidence of VAHL was 36.5% among all subjects who were vaccinated but was significantly higher after the 2nd vaccination (45.8%) compared with the 1st vaccination (26.3%). Node size, FDG uptake in axial lymph nodes beyond level 1, and the site of vaccination were all more prominent after the 2nd vaccination. After the first vaccination, the incidence of VAHL was higher at 6-12 days after vaccination compared with that in the first 5 days and at 13 days. After the second vaccination, the incidence and grade of VAHL were highest in the first 6 days, decreased gradually over time, and were significantly low at more than 20 days after vaccination. VAHL was recognized in 29% of vaccinated patients at 3 weeks after the second vaccination, but only 7% had grade 3 or 4 VAHL. After the first vaccination, there was a higher incidence and higher grade of VAHL in subjects aged ≤ 62 years than in others; whereas after the second vaccination, there was a higher incidence and higher grade of VAHL in subjects aged ≤ 64 years than in others (26). Regarding FDG uptake in lymph nodes, greater uptake was associated with second vaccination; in contrast, lower uptake was associated with older age, immunosuppressive treatment, and hematologic disease (30).

Conclusions

Vaccine-related lymphadenopathy in patients with lung cancer can lead to diagnostic dilemmas. In the initial stage, axillary lymphadenopathy can alter staging and can result in unnecessarily invasive procedures. Second, it can make the evaluation of the effectiveness of neo-adjuvant therapy difficult. Finally, new lymph node enlargement in post-operative patients makes it difficult to distinguish it from recurrence.

List of Abbreviations

- Chest CT: Chest Computed Tomography
- MRI: Magnetic Resonance Imaging.
- PET / CT: Positron Emission Tomography / Computerized Tomography.

Tables and Figures

Table 1. Details of Studies with CT chest imaging of Covid-19 post vaccination axillary lymphadenopathy.

AUTHOR	PUBLICATON YEAR	STUDY ORIGIN	SAMPLE SIZE	MAXIMAL NODE DIAMETER ON SHORT AXIS	VACCINE TO LYMPHADENPATHY TIME	VACCINE USED
Ahn RW et al..	2021	USA	3	2 cm	7 days	mRNA Covid vaccine
Lane DW et al..	2021	USA	6	1.3cm	15 days	Moderna and Pfizer
Viana JA et al..	2021	Brazil	1	-	1 day	Pfizer
Nishino M et al..	2021	USA	232	1.4cm	6.6 weeks	mRNA1273 BNT162b2
Qian Y et al..	2022	China	1	1.5cm	4 months	CoronaVac
Placke JM et al..	2021	Germany	8	1.6cm	50 days	BioNTech Pfizer

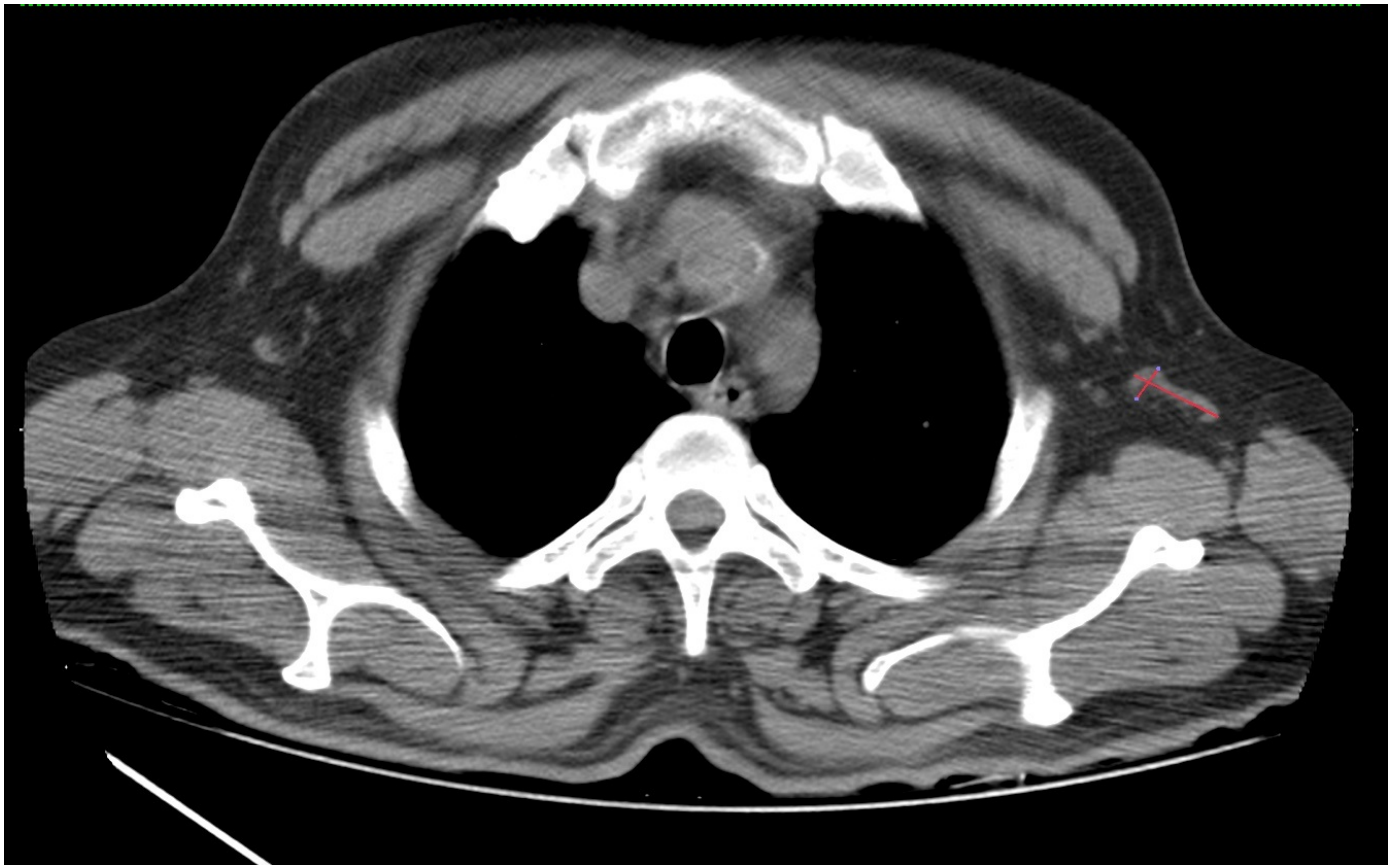

Fig.1. CT Chest non-contrast axial images: Measurement of left axillary enlarged lymph node post vaccination.

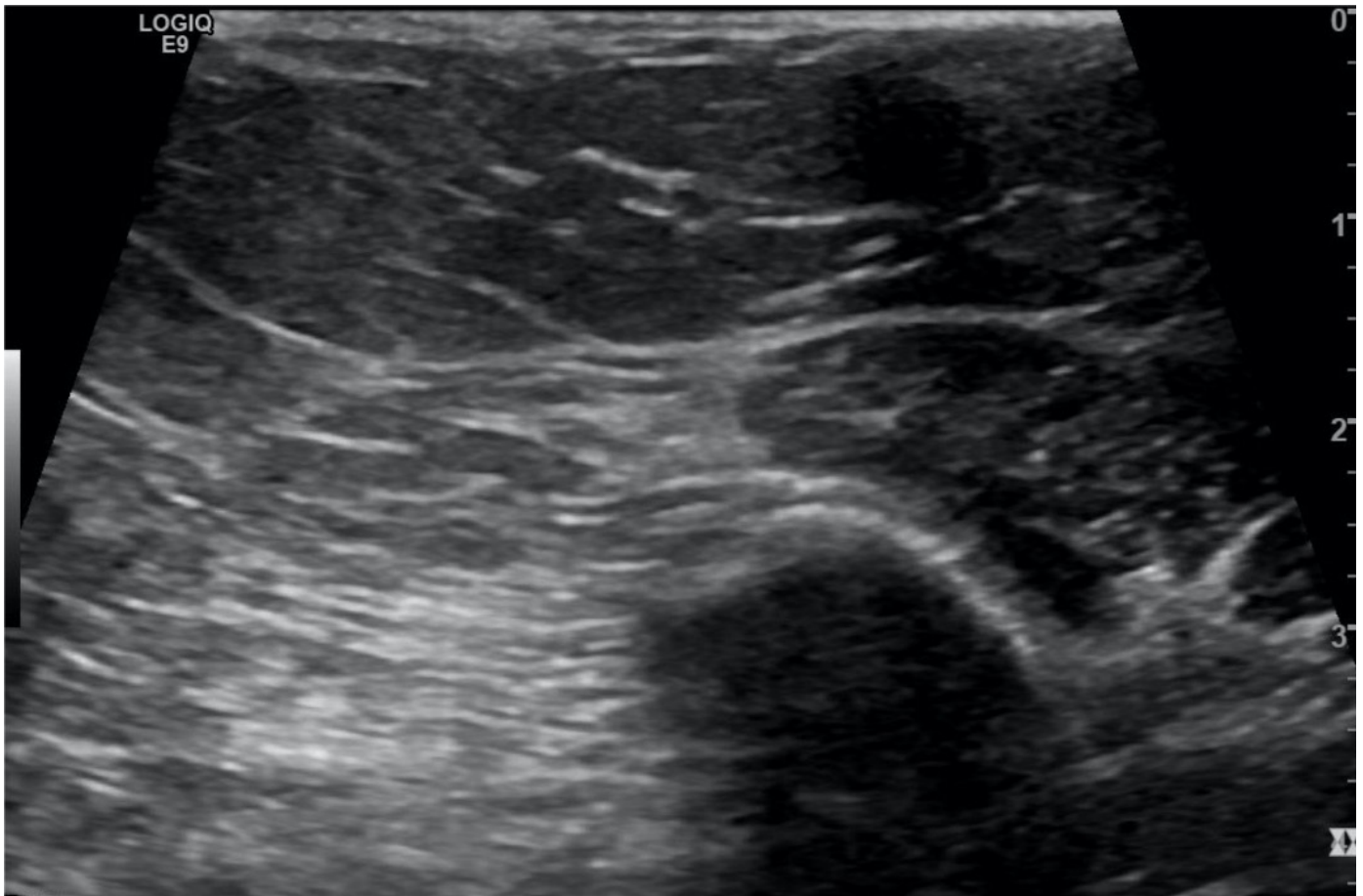


Fig.2. Follow up ultrasound images after 1 month showing resolution of axillary lymphadenopathy.

References

1. [^]<https://www.bing.com/covid> (Accessed Sep 08, 2022).
2. [^]Duman N, ALzaidi Z, Aynekin B, Taskin D, Demirors B, Yildirim A, et al.. COVID-19 Vaccine Candidates, and Vaccine Development Platforms Available Worldwide. *J Pharm Anal* (2021) 11(6):675–82. DOI: 10.1016/j.jpha.2021.09.004.
3. [^]Fishbein DB, Baer GM. Animal Rabies: Implications for Diagnosis and Human Treatment. *Ann Intern Med* (1988) 109(12):935–7. DOI: 10.7326/0003-4819-109-12-935
4. [^]Garreffa E, Hamad A, O'Sullivan CC, Hazim AZ, York J, Puri S, et al.. Regional Lymphadenopathy Following COVID-19 Vaccination: Literature Review and Considerations for Patient Management in Breast Cancer Care. *Eur J Cancer* (2021) 159:38–51. DOI: 10.1016/j.ejca.2021.09.033.
5. [^]Garreffa E, Hamad A, O'Sullivan CC, Hazim AZ, York J, Puri S, et al.. Regional Lymphadenopathy Following COVID-19 Vaccination: Literature Review and Considerations for Patient Management in Breast Cancer Care. *Eur J Cancer* (2021) 159:38–51. DOI: 10.1016/j.ejca.2021.09.033.
6. [^]Becker AS, Perez-Johnston R, Chikarmane SA, et al.. Multidisciplinary recommendations regarding postvaccine adenopathy and radiologic imaging: radiology scientific expert panel. *Radiology*. 2021;300: E323–E327.
7. [^]Ahn RW, Mootz AR, Brewington CC, Abbara S. Axillary lymphadenopathy after mRNA COVID-19 vaccination. *Radiol Cardiothorac Imaging*. 2021;3: e210008.
8. [^]Co M, Wong PCP, Kwong A. COVID-19 vaccine-associated axillary lymphadenopathy - A systematic review. *Cancer Treat Res Commun*. 2022; 31:100546. DOI: 10.1016/j.ctarc.2022.100546. Epub 2022 Mar 11. PMID: 35334408; PMCID: PMC8913438.
9. [^]Ahn RW, Mootz AR, Brewington CC, Abbara S. Axillary Lymphadenopathy After mRNA COVID-19 Vaccination. *Radiol Cardiothorac Imaging*. 2021 Feb 3;3(1): e210008. DOI: 10.1148/ryct.2021210008. PMID: 33778667; PMCID: PMC7861140.
10. [^]Lane DL, Neelapu SS, Xu G, Weaver O. COVID-19 Vaccine-Related Axillary and Cervical Lymphadenopathy in Patients with Current or Prior Breast Cancer and Other Malignancies: Cross-Sectional Imaging Findings on MRI, CT, and PET-CT. *Korean J Radiol*. 2021 Dec;22(12):1938-1945. DOI: 10.3348/kjr.2021.0350. Epub 2021 Oct 26. PMID: 34719892; PMCID: PMC8628159.
11. ^{a, b}Nishino M, Hatabu H, Ricciuti B, Vaz V, Michael K, Awad MM. Axillary Lymphadenopathy After Coronavirus Disease 2019 Vaccinations in Patients With Thoracic Malignancy: Incidence, Predisposing Factors, and Imaging Characteristics. *J Thorac Oncol*. 2022 Jan;17(1):154-159. DOI: 10.1016/j.jtho.2021.08.761. Epub 2021 Sep 29. PMID: 34506955; PMCID: PMC8423658.
12. [^]Placke JM, Reis H, Hadaschik E, Roesch A, Schadendorf D, Stoffels I, Klode J. Coronavirus disease 2019 vaccine mimics lymph node metastases in patients undergoing skin cancer follow-up: A monocentre study. *Eur J Cancer*. 2021 Sep;154:167-174. doi: 10.1016/j.ejca.2021.06.023. Epub 2021 Jun 26. PMID: 34280870; PMCID: PMC8233908.
13. [^]Wolfson S, Kim E, Plaunova A, Bukhman R, Sarmiento RD, Samreen N, Awal D, Sheth MM, Toth HB, Moy L, Reig B.

Axillary Adenopathy after COVID-19 Vaccine: No Reason to Delay Screening Mammogram. Radiology. 2022 May;303(2):297-299. doi: 10.1148/radiol.213227. Epub 2022 Feb 8. Erratum in: Radiology. 2022 Sep;304(3):E57. PMID: 35133198; PMCID: PMC8855316.

14. [^]Grimm L, Srini A, Dontchos B, et al.. Revised SBI recommendations for the management of axillary adenopathy in patients with recent COVID-19 vaccination. Published February 28, 2022. Accessed March 10, 2022.
15. [^]Schiaffino S, Pinker K, Magni V, Cozzi A, Athanasiou A, Baltzer PAT, Camps Herrero J, Clauser P, Fallenberg EM, Forrai G, Fuchsjäger MH, Helbich TH, Kilburn-Toppin F, Kuhl CK, Lesaru M, Mann RM, Panizza P, Pediconi F, Pijnappel RM, Sella T, Thomassin-Naggara I, Zackrisson S, Gilbert FJ, Sardanelli F. Axillary lymphadenopathy at the time of COVID-19 vaccination: ten recommendations from the European Society of Breast Imaging (EUSOBI). *Insights Imaging. 2021 Aug 20;12(1):119. doi: 10.1186/s13244-021-01062-x. PMID: 34417642; PMCID: PMC8378785.*
16. [^]Zhang M, Ahn RW, Hayes JC, Seiler SJ, Mootz AR, Porembka JH. Axillary Lymphadenopathy in the COVID-19 Era: What the Radiologist Needs to Know. *Radiographics. 2022 Nov-Dec;42(7):1897-1911. doi: 10.1148/rg.220045. Epub 2022 Aug 26. PMID: 36018786; PMCID: PMC9447369.*
17. [^]Minamimoto R, Kiyomatsu T. Effects of COVID-19 vaccination on FDG-PET/CT imaging: A literature review. *Glob Health Med. 2021 Jun 30;3(3):129-133. doi: 10.35772/ghm.2021.01076. PMID: 34250287; PMCID: PMC8239370.*
18. [^]Cohen D, Hazut Krauthammer S, Wolf I, Even-Sapir E. A sigh of relief: vaccine-associated hypermetabolic lymphadenopathy following the third COVID-19 vaccine dose is short in duration and uncommonly interferes with the interpretation of [18F]FDG PET-CT studies performed in oncologic patients. *Eur J Nucl Med Mol Imaging. 2022 Mar;49(4):1338-1344. doi: 10.1007/s00259-021-05579-7. Epub 2021 Oct 15. PMID: 34651230; PMCID: PMC8516623.*