

v3: 29 May 2022

Review Article

Cutaneous Syncytial Myoepithelioma: a unique variant worth recognizing

Peer-approved: 16 April 2022

© The Author(s) 2024. This is an Open Access article under the CC BY 4.0 license.

Qeios, Vol. 4 (2022)
ISSN: 2632-3834

Muhammad N Mahmood¹

1. Department of Laboratory Medicine and Pathology, University of Alberta, Canada

Cutaneous syncytial myoepithelioma is a recently characterized variant of cutaneous myoepithelioma with a distinct histopathological and immunohistochemical profile. It is more common in men and predominately involves upper and lower extremities. Microscopically, it is a dermal tumor with a characteristic solid syncytial growth pattern displaying positivity with EMA and S100 immunohistochemical stains. Lately, EWSR1-PBX3 fusion has been documented in a vast majority. Although it follows a benign clinical course, its histopathological differential diagnosis includes clinically aggressive neoplasia. This review summarizes the derivation, clinical presentation, histopathological and immunohistochemical features, molecular genetics, pertinent differential diagnosis, and behavior of this unique cutaneous appendageal tumor.

Corresponding author: Muhammad N Mahmood, noshpath97@gmail.com

Introduction

Benign and malignant myoepithelial neoplasms are well documented in several locations, including salivary glands, breast, and lung. In recent decades, benign myoepithelial proliferations of skin have been increasingly identified and categorized as cutaneous myoepithelioma (CM).^{[1][2][3]} CM, a dermal tumor formed by proliferating myoepithelial cells, demonstrates morphological diversity and is considered to form a continuous spectrum shared with benign cutaneous mixed tumor (chondroid syringoma) and myoepithelial carcinoma.^[2]

Within CM, a subset of cases representing a discrete variant designated as cutaneous syncytial myoepithelioma (CSM) has been lately described.^{[3][4]}^{[5][6]} While uncommon and recently delineated, this subgroup has a distinctive histomorphological and immunohistochemical profile. In order to achieve precise categorization and avoid mislabeling this

lesion as a sinister cutaneous neoplasm, familiarity and knowledge of this variant are essential for residents, dermatologists, and pathologists.

Origin & Derivation

Myoepithelium or myoepithelial cells are ectodermal derived modified epithelial cells positioned amid the glandular luminal epithelial cells and the basement membrane. They serve several functions, including contraction in response to cholinergic stimuli to aid extrusion of glandular secretions, support of secretory cells, and production of basement membrane material. Myoepithelial cells are typically slender and spindle-shaped, possessing cytoplasmic processes which engulf the neighboring epithelial cells. As the name implies (i.e., myo-epithelial), they can express attributes of both epithelial and smooth muscle cells, proliferating and differentiating to shape varied morphologies, including spindled, epithelioid, basaloid, plasmacytoid, histiocytoid, and clear cell types.^{[7][8]} Variations such as squamous or chondroid metaplasia can also develop. This diversity in morphology reflects in the heterogeneous

microscopic traits of myoepithelial proliferations. They are situated in different body sites, including salivary glands, breast, lung, prostate, skin, and lacrimal gland.

In skin, they are normally present as an outer discontinuous layer in secretory units of eccrine and apocrine sweat glands, and their existence has been noted in a variety of adnexal tumors.^[9] The proliferation of myoepithelial cells is frequently seen in commonly encountered cutaneous mixed tumors.^[10] Sharing the same spectrum, CM is formed purely by myoepithelial cells and lacks any tubuloductal elements regularly observed in the cutaneous mixed tumor. Myoepitheliomas are usually considered soft tissue neoplasms; however, in skin they are grouped with appendageal tumors. The current World Health Organization classification of skin tumors categorizes them in the benign tumors with apocrine and eccrine differentiation subcategory.^[11] CM is further categorized into a classical variant and a recently described solid syncytial variant named CSM. The characteristics ascribed to CSM were initially presented by Hornick and Fletcher.^[3] Following its initial description, CSM was further characterized in a larger study of 38 cases in 2013.^[4]

Clinical Presentation

Cutaneous syncytial myoepithelioma is recently recognized, and the actual incidence is not precisely known as only limited numbers of cases are reported. It is more prevalent in men (2.5:1, male to female ratio), and though cases are seen over a wide age range, they are generally observed in the third to fifth decades of life (median: 39 years).^[4] It occurs predominantly on the upper and lower extremities (74%), including hands and feet; however, cases on trunk and head-neck areas have also been reported. The clinical presentation of CSM is similar to classical CM, yet it is different from a cutaneous mixed tumor which is more frequent in the head-neck area. CSM typically presents as a solitary, painless, dermal, papular/nodular, or polypoid gradually growing lesion with a size range of 0.3 to 2.7 cm (median: 0.8 cm).^[4] Considering the vast array of clinical differential diagnoses offered in reported cases of CSM, the clinical appearance is non-specific, and the diagnosis is almost exclusively reliant on pathological assessment.

Microscopic Features

On light microscopic examination, CSM displays a non-encapsulated and non-infiltrative delineated outline of growth. It shows a dome-shaped silhouette with a primarily dermal epicenter of growth. Subcutis, which may be superficially encroached, is not characteristically permeated.^{[3][4][6]} The tumor may abut the overlying epidermis inducing mild secondary hyperplasia; however, no ulceration is recorded (shown in Fig. 1).

The proliferation exhibits a solid sheath-like pattern formed by monomorphic appearing ovoid, histiocytoid, or spindled cells (shown in Fig. 2, 3). Short fascicle formation may be present, and multinucleation is generally not seen. The vesicular nuclei demonstrate fine chromatin and distinct small nucleoli, surrounded by eosinophilic syncytial cytoplasm (shown in Fig. 4). They are cytologically bland with no significant hyperchromasia, pleomorphism, apoptosis, or necrosis. The majority of CSM does not display mitotic activity; however, when present, they tend to be sparse ranging from 0 to 4 per 10 HPF (shown in Fig. 5). CSM lacks significant other stromal elements, though fat appearing entrapped in tumor representing adipocytic metaplasia has been repeatedly described (shown in Fig. 6). No ductal differentiation is noted; however, entrapped native skin adnexal elements and occasional small follicular cyst formation are sometimes noticed (shown in Fig. 6). Only rarely, chondroid-osseous differentiation has been focally observed. Associated mild intra-tumoral or peri-tumoral, perivascular infiltrate comprised of lymphocytes, plasma cells, or some histiocytes have been described.

The histopathology of CSM is distinctive and is reproducible between tumors. In comparison, analogous to their counterparts in the salivary glands and soft tissue, the classical variant of CM can reveal a range of variable morphologies.^{[5][12][13]} The classical variant is lobulated with reticular, trabecular, solid, or plexiform growth patterns, showing plump epithelioid, plasmacytoid (hyaline cells), spindled or clear cells arranged in cords or nests, and producing/embedded in chondromyxoid, myxoid or hyaline stroma.

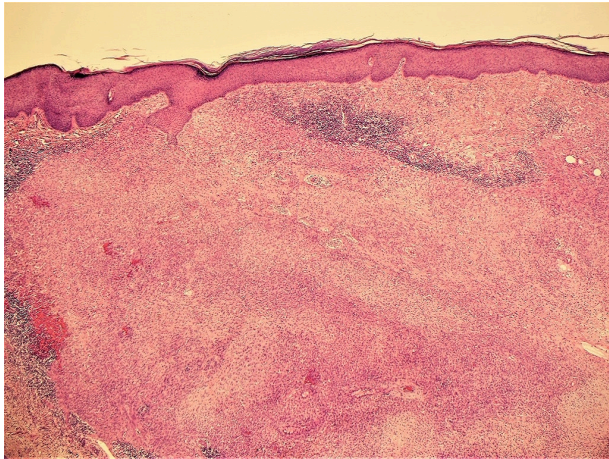


Fig. 1. Dermal epicenter of growth which abuts the overlying epidermis. Mild peritumoral lymphocytic infiltrate is seen (H&E, 40x).

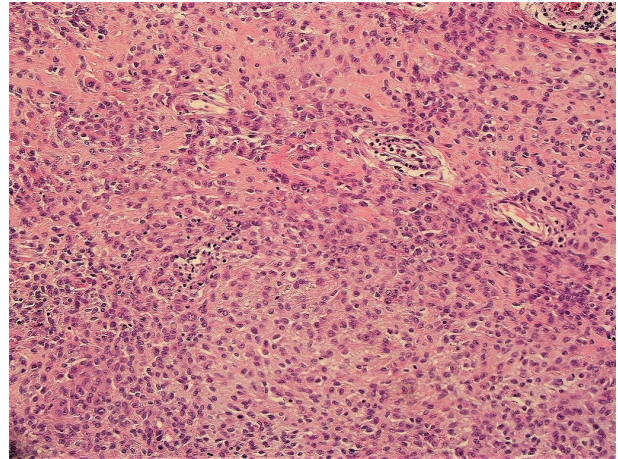


Fig. 3. A closer view of the solid syncytial pattern formed by uniform monomorphic cells (H&E, 200x).

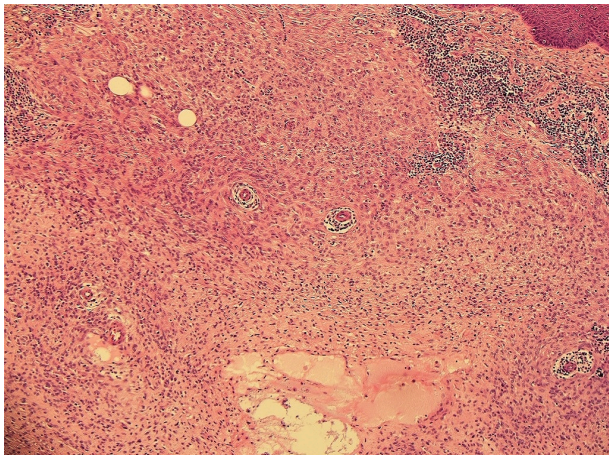


Fig. 2. Sheath-like pattern of dermal growth formed by uniform appearing ovoid and histiocytoid cells. Mild peritumoral lymphocytes and embedded vessels are seen (H&E, 100x).

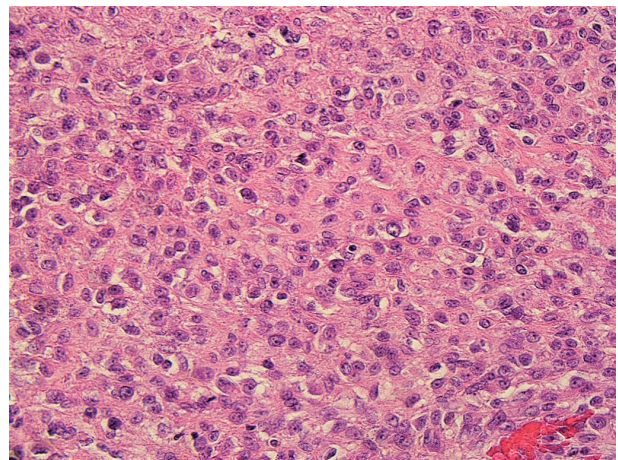


Fig. 4. Vesicular nuclei displaying fine chromatin and nucleoli, surrounded by eosinophilic syncytial cytoplasm (H&E, 400x).

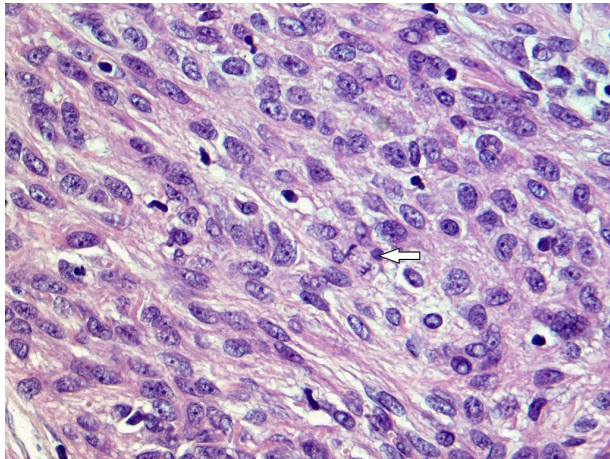


Fig. 5. Cellular area shows mitotic activity (arrow) (H&E, 500x).

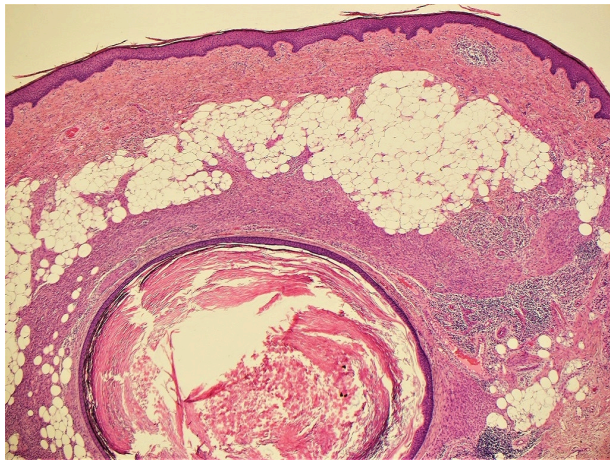

Fig. 6. Adipocytic metaplasia and follicular cyst formation are present (H&E, 40x).

Immunohistochemistry & Genetics

Confirmatory immunohistochemical studies are generally required for the diagnosis of myoepithelioma. As myoepithelium can exhibit both epithelial and myoid differentiation, myoepithelioma can show a heterogeneous immunophenotype with a variable combination of keratins, epithelial membrane antigen (EMA), S100, and myogenic markers like smooth muscle actin (SMA).^{[2][3]} The usual immunolabeling pattern for myoepithelioma is S100, along with at least one epithelial marker. Unlike normal myoepithelium, the proliferating myoepithelial cells in tumors may sometimes lose

immunolabeling by myoid stains, causing the absence of SMA expression in a subset of these tumors.

Cutaneous syncytial myoepithelioma shows a reproducible immunohistochemical profile of EMA and S100 positivity; however, in contrast to myoepithelioma in other sites, most lack keratin expression (shown in Fig. 7, 8). In the largest study thus far, diffuse EMA positivity was registered in all 38 of 38 cases (100%) and diffuse S100 positivity in 33 of 38 cases (87%) of CSM.^[4] In five cases that were negative for diffuse S100 expression, focal staining was still observed. In a more recent investigation, out of 23 cutaneous myoepitheliomas with syncytial growth, 66% were EMA positive, and 87% were S100 positive.^[6] Keratins (including pan-keratin, AE1/AE3, CAM 5.2) were much less frequent, with negative results in 31 of 36 cases (86%). Glial fibrillary acidic protein (GFAP) stain was variable, exhibiting weak multifocal positivity in 14 of 33 cases (about 42%), SMA was positive in 9 of 13 cases (about 69%), and p63 was expressed in 6 of 11 cases (55%).^[4] Desmin was negative in the majority of cases. SOX-10 expression was shown in 3 of 5 cases (60%) of CM, though these cases were classical rather than syncytial subtype.^[4] Some individually reported cases of CSM do state SOX-10 negativity.^[15] HMB-45, Melan-A, and microphthalmia-associated transcription factor (MITF) were negative.^[15] ALK was also negative in these tumors.^[16] Classical variant of CM and CSM share the consistent S100 labeling; however, the classical variety showed a lower percentage of EMA positivity (42%) and a higher rate of cases expressing keratins (about 90%).^[13]

Ewing sarcoma RNA-binding protein 1 (EWSR1) occurs in up to 45% of skin and soft tissue myoepithelial tumors.^[5] Fluorescence-in-situ hybridization for EWSR1 gene rearrangement has confirmed a higher rate of positivity in CSM (14 of 17 cases, 82%).^[4] A novel fusion gene partner has been documented as recent reports disclose EWSR1-PBX3 fusion in a vast majority of CSM.^{[17][18]} Considering the relatively invariable histopathological and immunohistochemical profile of the syncytial variant, the genetic consistency is not unexpected. The importance of gene fusion products is not yet evident in this setting, and they may play a role in the histomorphological appearance of CSM. In comparison, the classical variant of CM has demonstrated several fusion gene partners, and the

cutaneous mixed tumor is linked with pleomorphic adenoma gene 1 (PLAG1) aberrations.^[19]

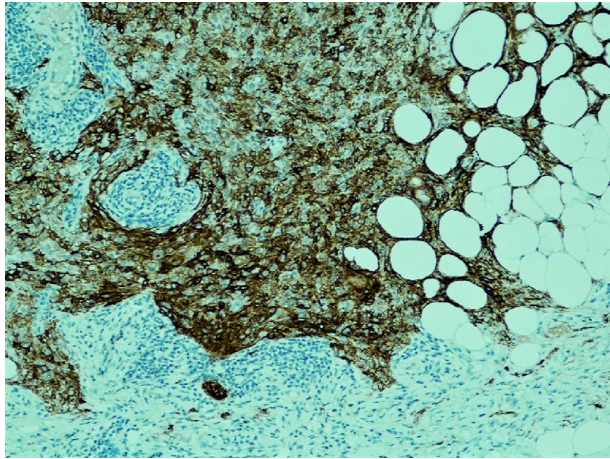


Fig. 7. Diffuse EMA immunohistochemical stain positivity is noted (EMA, 100x).

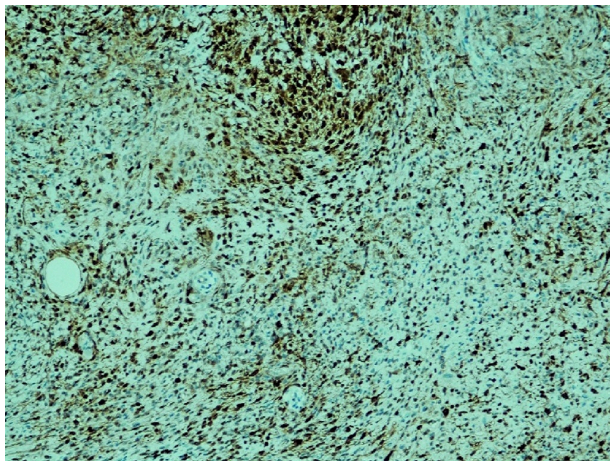


Fig. 8. S100 immunohistochemical stain positivity is noted (S100, 100x).

Pathological Differential Diagnosis

The histopathological and immunohistochemical profile of CSM generates a broad microscopic differential diagnosis. Due to the syncytial growth pattern, the differential is different from what is usually fashioned for the classical variant of CM. The general category is a superficial dermal tumor and includes both benign and malignant neoplasms.^[20] The list of mimickers encompasses lesions belonging to diverse histogenetic groups, including

fibrohistiocytic (epithelioid fibrous histiocytoma, juvenile xanthogranuloma, epithelioid sarcoma), melanocytic (intradermal Spitz nevus, nevoid melanoma, primary dermal melanoma), peripheral nerve sheath tumors (epithelioid schwannoma, epithelioid perineurioma) and uncertain histogenesis (cellular neurothekeoma).

If a pathologist is not familiar with the CSM morphology, it can pose a potential diagnostic pitfall.^[21] Careful inspection of microscopic features and a panel of immunohistochemical stains can aid in establishing the correct diagnosis and rule out clinically significant entities in the differential. Epithelioid fibrous histiocytoma can display the growth of epithelioid cells with eosinophilic cytoplasm in a sheet-like pattern; however, it has collagenous vascularized stroma, shows binucleation, and in general, lacks a spindle-cell component and authentic syncytial architecture. They are also EMA positive and negative for keratins; however, in contrast to CSM, they are ALK-positive and negative for S100, p63, and GFAP stains.^[22] Juvenile xanthogranuloma, which lacks Touton-type giant cells and lipidization (early phase), can mimic CSM. They are positive for histiocytic markers (e.g., CD68K) and are negative for myoepithelial stains. Epithelioid sarcoma displays epithelioid and spindled cytologically atypical cells in a larger nodular growth.^[15] They show deep infiltrative growth, increased mitoses, and central necrosis, sometimes generating a low-power impression of a necrobiotic granuloma. They are also EMA positive; however, compared to CSMs, they express positivity for keratins and CD34, and are negative for S100, GFAP and show loss of SMARCB1 (INI1). Cellular neurothekeoma, an uncommon tumor of uncertain histogenesis with suggested fibrohistiocytic or myofibroblastic origin, is formed by epithelioid to spindled cells arranged in a nested or concentric pattern, lacking the syncytial pattern. They are negative for S100 and EMA stains, though they show positivity for S100A6 and CD63 (NKI-C3) markers.^[23]

S100 positivity in CSM also brings in amelanotic intradermal melanocytic proliferations in the microscopic differential. In particular, a subset of intradermal Spitz nevus can display certain morphological similarities; however, these lesions tend to show nested growth pattern in areas, exhibit maturation upon descent and may have at least a focal junctional component in the epidermis. Primary dermal melanoma and nevoid melanoma may also enter the differential; however, along with several

other differentiating traits, melanoma generally demonstrates a greater degree of cytological atypia and mitotic activity.^[15] Although S100 positivity is shared, CSM is negative for other conventional melanocytic markers (i.e., HMB45, Melan-A, MiTF).

Specific criteria for predicting aggressive or malignant behavior have not been precisely established for cutaneous myoepithelial neoplasms.^[3] If criteria validated for myoepithelial neoplasms of soft tissue are employed, the chief criterion for malignancy is cytological atypia, with neoplastic cells exhibiting enlarged nuclei, prominent nucleoli, and coarse chromatin.^[5] Cases classified as cutaneous myoepithelial carcinoma or cutaneous malignant myoepithelioma are exceptionally rare and tend to display moderate to severe cytological atypia, high mitotic rate, and necrosis, although cases with a lesser degree of cytological atypia have also been

described.^{[24][25]} In comparison, CSM lacks overt cytological atypia, high mitotic count, or necrosis.

Clinical Behavior

Cutaneous syncytial myoepithelioma is a benign tumor that rarely exhibits local recurrence. In 21 patients with available follow-up information, only one patient demonstrated local recurrence after about four years.^[4] In this patient, the initial procedure was a shave biopsy, and both primary and recurrent tumors did not disclose any cytological atypia, increased mitosis, or additional microscopic traits of malignancy. Six patients with positive biopsy margins displayed no evidence of clinical recurrence, and aggressive clinical behavior or distant metastasis was not seen. Complete conservative excision with negative margins is usually recommended for CSM.

<p>Clinical Presentation</p> <ul style="list-style-type: none"> - Sporadic, solitary, painless, slow-growing, papule or nodule - Men > Women, extremities, 3rd to 5th decade, size: 0.8 cm (median)
<p>Microscopic Features</p> <ul style="list-style-type: none"> - Dermal tumor with a solid syncytial growth pattern - Uniform, monomorphic, ovoid, histiocytoid, or spindled cells - Vesicular nuclei, small nucleoli, pale eosinophilic cytoplasm - Adipocytic metaplasia, occasional mitosis
<p>Immunohistochemical Profile</p> <ul style="list-style-type: none"> - EMA+, S100+, SMA+ - Keratins-, Desmin-, ALK-, HMB45-, Melan-A-
<p>Genetic Profile</p> <ul style="list-style-type: none"> - EWSR1-PBX3 fusion
<p>Pathological Differential Diagnosis</p> <ul style="list-style-type: none"> - Epithelioid fibrous histiocytoma, juvenile xanthogranuloma, epithelioid sarcoma - Intradermal Spitz nevus, nevoid melanoma - Epithelioid schwannoma, epithelioid perineurioma, cellular neurothekeoma
<p>Prognosis</p> <ul style="list-style-type: none"> - Benign, rare local recurrence

Table 1. Summary of Cutaneous Syncytial Myoepithelioma

Conclusion

In sum, CSM is a distinct, recently characterized variant of cutaneous myoepithelioma (Table 1). It is more common in men and frequently occurs on extremities. It displays a syncytial growth pattern, EMA and S100 positivity, and has shown EWSR1-PBX3 fusion. Due to the relatively recent induction of this appendageal tumor in the dermatological lexicon, dermatologists, pathologists, and residents in training may be unfamiliar with its morphological appearance and immunohistochemical profile. This lack of awareness can lead to under-recognition of CSM and misdiagnosis as one of its morphological mimics.

References

1. ^aM. Michal, Markku Miettinen. (1999). *Myoepitheliomas of the skin and soft tissues*. *Virchows Archiv*, vol. 434 (5), 393-400. doi:10.1007/s004280050358.
2. ^{a, b, c}Thomas Mentzel, Luis Requena, Steven Kaddu, Luis M. Soares de Aleida, et al. (2003). *Cutaneous myoepithelial neoplasms: clinicopathologic and immunohistochemical study of 20 cases suggesting a continuous spectrum ranging from benign mixed tumor of the skin to cutaneous myoepithelioma and myoepithelial carcinoma*. doi:10.1034/j.1600-0560.2003.00063.x.
3. ^{a, b, c, d, e, f}Jason L Hornick, Christopher D.M Fletcher. (2004). *Cutaneous myoepithelioma: a clinicopathologic and immunohistochemical study of 14 cases*. *Human Pathology*, vol. 35 (1), 14-24. doi:10.1016/j.humpath.2003.08.016.

4. ^{a, b, c, d, e, f, g, h, i}Vickie Y. Jo, Cristina R. Antonescu, Lei Zhang, Paola Dal Cin, et al. (2013). Cutaneous Syncytial Myoepithelioma. doi:10.1097/pas.0b013e3182772bba.
5. ^{a, b, c, d}Vickie Y. Jo, Christopher D. M. Fletcher. (2015). Myoepithelial Neoplasms of Soft Tissue: An Updated Review of the Clinicopathologic, Immunophenotypic, and Genetic Features. *Head and Neck Pathol*, vol. 9 (1), 32–38. doi:10.1007/s12105-015-0618-0.
6. ^{a, b, c}Jose A. Plaza, Thomas Brenn, Catherine Chung, Sadia Salim, et al. (2021). Histomorphological and immunophenotypical spectrum of cutaneous myoepitheliomas: A series of 35 cases. *J Cutan Pathol*, vol. 48 (7), 847–855. doi:10.1111/cup.13942.
7. ^{A, V}Anbazhagan, N Balachander, K. M. K. Masthan, N Aravindha babu. (2015). Myoepithelial cells in pathology. *J Pharm Bioall Sci*, vol. 7 (5), 192. doi:10.4103/0975-7406.155898.
8. ^{A, M}M. Schon, J. Benwood, T. O'Connell-Willstaedt, J.G. Rheinwald. (1999). Human sweat gland myoepithelial cells express a unique set of cytokeratins and reveal the potential for alternative epithelial and mesenchymal differentiation states in culture. doi:10.1242/jcs.112.12.1925.
9. ^{A, N}A Obaidat, K. O Alsaad, D. Ghazarian. (2006). Skin adnexal neoplasms--part 2: An approach to tumors of cutaneous sweat glands. *Journal of Clinical Pathology*, vol. 60 (2), 145–159. doi:10.1136/jcp.2006.041608.
10. ^{A, D}Dmitry V. Kazakov, Irena E. Belousova, Michele Bisceglia, Eduardo Calonje, et al. (2007). Apocrine mixed tumor of the skin ("mixed tumor of the folliculosebaceous-apocrine complex"). *Journal of the American Academy of Dermatology*, vol. 57 (3), 467–483. doi:10.1016/j.jaad.2007.02.029.
11. ^{A, E}Elder DE, Massi D, Scolyer RA, Willemze R, editors. (2018). *WHO classification of skin tumours*. 4th ed. Lyon: IARC; 2018 p.194.
12. ^{A, L}Alós L, Cardesa A, Bombí JA, Mallofré C, Cuchi A, Trasserra J. (1996). Myoepithelial tumors of salivary glands: a clinicopathologic, immunohistochemical, ultrastructural, and flow-cytometric study. *Semin Diagn Pathol*, vol. 13(2):138–47.
13. ^{a, b}Nelson Montalvo, Ligia Redrobán, David Galarza, Iván Ramírez. (2020). Cutaneous Myoepithelioma: An Unusual Tumor in the Hand. *Case Reports in Pathology*, vol. 2020, 1–7. doi:10.1155/2020/3747013.
14. ^{A, A}Agne Naujokas, Yann Charli-Joseph, Beth S. Ruben, Iwei Yeh, et al. (2014). SOX-10 expression in cutaneous myoepitheliomas and mixed tumors. *J Cutan Pathol*, vol. 41 (4), 353–363. doi:10.1111/cup.12279.
15. ^{a, b, c, d}Ahmed K. Alomari, Noah Brown, Aleodor A. Andea, Bryan L. Betz, et al. (2017). Cutaneous syncytial myoepithelioma: A recently described neoplasm which may mimic nevoid melanoma and epithelioid sarcoma. *J Cutan Pathol*, vol. 44 (10), 892–897. doi:10.1111/cup.13005.
16. ^ALeona A Doyle, Adrián Mariño-Enriquez, Christopher DM Fletcher, Jason L Hornick. (2015). ALK rearrangement and overexpression in epithelioid fibrous histiocytoma. *Mod Pathol*, vol. 28 (7), 904–912. doi:10.1038/modpathol.2015.49.
17. ^AVickie Y. Jo, Cristina R. Antonescu, Brendan C. Dicks on, David Swanson, et al. (2019). Cutaneous Syncytial Myoepithelioma Is Characterized by Recurrent EWSR1-PBX3 Fusions. doi:10.1097/pas.0000000000001286.
18. ^AWilliam F. MacKinnon, Michael D. Carter, Julia A. Bridge, Robert D. Tremaine, et al. (2019). EWSR1-PBX3 gene fusion in cutaneous syncytial myoepithelioma. *J Cutan Pathol*, vol. 46 (6), 421–424. doi:10.1111/cup.13450.
19. ^AArmita Bahrami, James D. Dalton, Jeffrey F. Krane, Christopher D. M. Fletcher. (2011). A subset of cutaneous and soft tissue mixed tumors are genetically linked to their salivary gland counterpart. *Genes Chromosomes. Cancer*, vol. 51 (2), 140–148. doi:10.1002/gcc.20938.
20. ^AJUN-HSIUNG LEE, HSUAN-YING HUANG, JUI LAN, CHENG-CHENG HWANG, et al. (2015). Cutaneous syncytial myoepithelioma: A case report with emphasis on the differential diagnosis of problematic dermal tumors. doi:10.3892/ol.2015.3055.
21. ^ACameron Wales, Scott Diamond, Brian Hinds. (2019). Cutaneous Syncytial Myoepithelioma: A Nondescript Skin Tumor With Serious Diagnostic Pitfalls. *Int J Surg Pathol*, vol. 28 (1), 63–67. doi:10.1177/1066896919879755.
22. ^ALeona A. Doyle, Christopher D. M. Fletcher. (2011). EMA positivity in epithelioid fibrous histiocytoma: a potential diagnostic pitfall. doi:10.1111/j.1600-0560.2011.01747.x.
23. ^AJose Antonio Plaza, Carlos Torres-Cabala, Harry Evans, A Hafeez Diwan, et al. (2009). Immunohistochemical Expression of S100A6 in Cellular Neurothecoma: Clinicopathologic and Immunohistochemical Analysis of 31 Cases. doi:10.1097/dad.0b013e3181a13af.c.
24. ^AJin Tanahashi, Kenji Kashima, Tsutomu Daa, Yoshiyuki Kondo, et al. (2007). A case of cutaneous myoepithelial carcinoma. *J Cutan Pathol*, vol. 34 (8), 648–653. doi:10.1111/j.1600-0560.2006.00676.x.

25. [^]Ikuko Hirai, Keiji Tanese, Yoshio Nakamura, Masayuki Amagai, et al. (2019). Case of metastatic cutane

ous myoepithelial carcinoma lacking severe cytological atypia. *J Dermatol*, vol. 47 (3). doi:10.1111/1346-8138.15218.

Declarations

Funding: The author(s) received no specific funding for this work.

Potential competing interests: The author(s) declared that no potential competing interests exist.