

[Open Peer Review on Qeios](#)

[Review] Etiology and pathogenesis of megacolon in children

Michael Levin

Funding: No specific funding was received for this work.

Potential competing interests: No potential competing interests to declare.

Abstract

The definition of "Megacolon" is still subjective since the methods of determination are not based on reliable limits of the norm. The literature review consists of three parts. The first part for analysis, a method was selected that allows to differentiate 3 degrees of megacolon, regardless of age. The second part analyzes children from 1 to 6 years of age, in whom an involuntary delay in defecation leads to overflow of the rectum and, with a subsequent painful attempt at defecation, to a conscious delay. Thus, a vicious circle arises, because of which a functional megacolon (FM) develops. The obstructive nature of FM has been proven, and two variants of its pathogenesis. The third part consisted of patients with ARM. The cause of megacolon is a sharp narrowing of the ectopic anus. The dissection of the stenotic ring in patients with visible fistulas can completely prevent the development of megacolon. After the cutback procedure, boys with perineal fistulas do not experience fecal incontinence, and mild constipation resolves with time. After pull-through surgery, regardless of access, there is severe constipation with megacolon and/or fecal incontinence. In these cases, the violation of fecal retention and defecation is due to the destruction of the ectopic anal canal, without which these functions cannot be restored. A method for determining megacolon and anal canal function in children of different ages is described. This made it possible to establish that acquired megacolon is always of an obstructive nature, either over constriction or because of a dysfunction of the anal canal.

M.D. Levin, MD, PhD, DSc.

Department of Pediatric Radiology, 1st State Hospital, Minsk, Belarus.

Dorot Medical Center for Rehabilitation and Geriatrics, Netanya, Israel.

Amnon VeTamar, 1/2, Netanya, 42202, Israel.

Email: nivel70@hotmail.com; michael.levin@dorot.health.gov.il

Website: <http://www.anorectalmalformations.com>

ORCID: <https://orcid.org/0000-0001-7830-1944>

Keywords: Functional megarectum; chronic constipation; x-ray study; anorectal malformations; anorectal fistula; ectopic anal canal.

Abbreviations

- ARM – anorectal malformations.
- ASARP – anterior sagittal anorectoplasty.
- C – constant.
- FC – functional constipation.
- FM – functional megacolon.
- IAS – internal anal sphincter.
- EAS – external anal sphincter.
- PRM – puborectalis muscle.
- PSARP – posterior sagittal anorectoplasty.
- RPR – rectal-pelvic ratio.

1. Introduction

The definition of "Megacolon" suggests an increase in the size of the colon. To consider the colon enlarged, it is necessary to know its normal size. This is especially difficult, since it is obvious that all anatomical parameters depend on age and height. Currently, there are no generally accepted limits of the norm for the width of the colon and therefore the definition of megacolon is subjective. For example, Cuda et al consider megacolon if the width of the sigmoid colon is ≈ 10 cm [1]. Considering that the normal width of the sigmoid colon in adults is 2.2-2.6 (2.36 \pm 0.03 cm)^[2], this means that the expansion of the intestine from 3 to 10 cm is not mistakenly diagnosed as megacolon. There is no consensus on the pathogenesis of megacolon and its association with chronic constipation. For example, Cuda et al consider constipation to be one of the symptoms of megacolon. It is natural to assume that megacolon results from the retention of feces in the colon. In such cases, functional constipation (FC) and megacolon are indispensable companions. Different authors use different terms to describe the expansion of the colon: megarectum and megacolon. It is known from anatomy that the rectum is always wider than the sigmoid colon. Only in Hirschsprung's disease is the rectosigmoid ratio less than one [3]. With constipation of a different etiology, accompanied by severe chronic constipation, the rectosigmoid ratio may be less than one. But in such cases, the rectum is significantly expanded relative to the norm. This is since the rectum is in the small pelvis and its expansion is limited by the boundaries of the small pelvis, while the sigmoid colon can expand much more, since it is not limited by anatomical boundaries [4]. There are no answers to the following questions: (1) why the rectum expands? (2) can it expand without expanding the sigmoid colon? (3) in what cases can these two definitions be used? This review is also devoted to the analysis of the literature on anorectal malformations (ARM) from the point of view of the development of megacolon. And all the above problems relate to ARM. In addition, there is no consensus on in which cases megacolon is congenital, which leads to intestinal expansion, and how it is affected by different methods of surgical intervention.

2. Analysis of different methods for measuring of the colon and anorectum

2.1. Probably, **rectal-pelvic ratio (RPR)** was the first attempt to made to objectively define megacolon (megarectum)^{[5][6]}. Although Meunier et al, using barium enema method, stated that "It appeared that the barium enema study was not meaningful" ^[5], van der Plas et al repeated it oddly^[6]. The control group comprised six children with recurrent abdominal pain and without rectal fecal impaction. However, they had a high incidence of painful defecation (50%) and straining (30%), so it is impossible to consider them healthy. Barium X-ray was not performed in the control group, and the diameter of the balloon, at which the child felt the need to defecate, cannot be equated with the normal diameter of the rectum. In patients with rectal fecal impaction, 5 ml of barium diluted in 40 ml of water was injected to determine the width of the fecal stone, and not the rectum. The RPR was obtained by dividing the diameter of the rectal width by the diameter of the linea transversa of the pelvis (**Figure 1.A**). The mean RPR in patients was 0.68 (range 0.32-0.83). The mean intrarectal balloon width was obtained in 25 patients and five controls and the results (0.64 (range 0.37-0.75) and 0.52 (range 0.31-0.61)) were not significantly different.

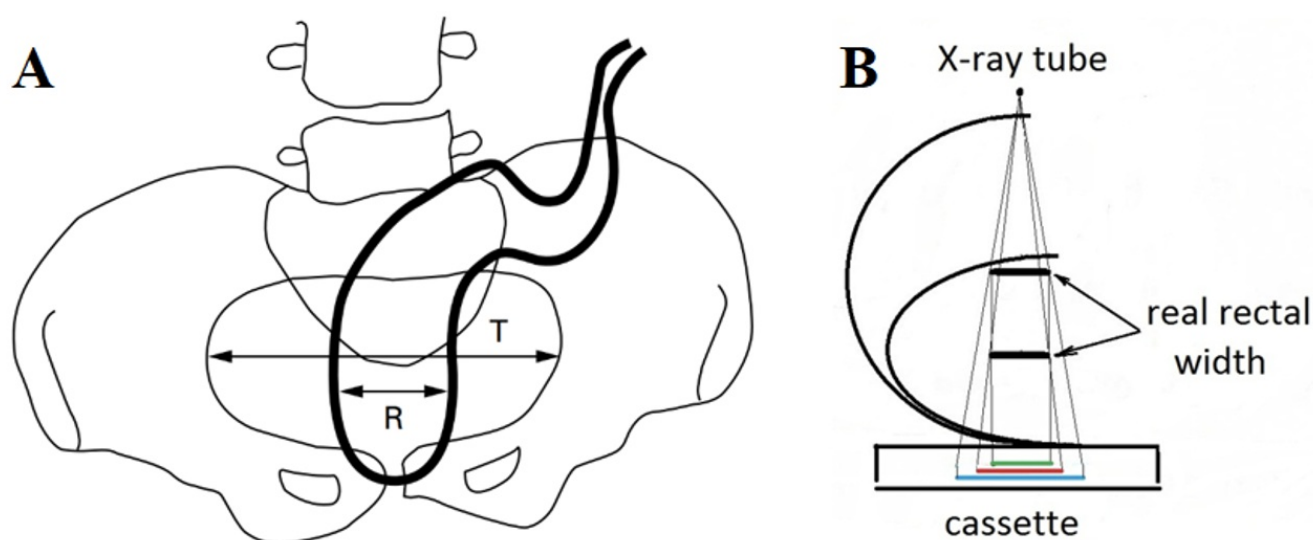


Figure 1.(A) Method for measuring the width of the rectum from van der Plas et al. ^[6]. Explanations in the text. (B). The enlargement of the rectal image on the X-ray depending on the width of the pelvis (Scheme) ^[2]. Green line – the real rectal width; red line – its image in small pelvis; blue line – its image in large pelvis.

Based on the studies, the authors made a logical conclusion: - "With this study, we have not been able to define megarectum in children by radiological and anorectal manometrical investigations". However, in the conclusion, the authors stated: - "An abdominal x ray examination can be performed to identify an enlarged rectum, which we propose to define by a RPR of 0.61 or larger". This conclusion was not consistent with the results of the study. The proposed method revealed the expansion of the large intestine in severe forms of megacolon and therefore, with rare exceptions, was not used in the next 13 years. Another suggestion: - "We propose to use only the term megarectum in children when functioning of rectal wall or nerve supply shows abnormalities on appropriate investigations" ^[6] creates the illusion that the megarectum can be without sigmoid expansion and for its determination, except for measurement additional research

methods are needed. However, numerous articles on the surgical treatment of megacolon report the removal of the expanded rectosigmoid segment [7]. Secondly, subsequent studies have proven the effectiveness of X-ray examination to determine the megarectum [8][9].

2.2. Koppen et al, made the following attempt to determine the border of the normal rectum [10]. To do this, they measured the width of the rectum on the frontal radiograph of children under the age of 6 years during desinvagination with pressurized air insufflation. They did not consider that the tone of the large intestine during intussusception is sharply disturbed, that desinvagination is performed under high pressure, that different parts of the large intestine are superimposed on the frontal image. Thus, they came to the paroxysmal conclusion the true width “r” is 4.7 cm. Because the dimensions on the roentgenogram are larger than the true anatomical dimensions, the value of the “rectal” width on the radiograph at standard shooting conditions would be equal to 6.5 cm (**see Figure 1.B**). Thus, in a study by Koppen et al, the normal width of the rectum in the children of 2-3 years was greater than the upper limit of the norm determined for adults (6.3 cm) [8][11].

2.3. Radiometric method. In our research, we proceeded from the following principles:

1. Since the rectum forms two bends in two projections, it cannot be differentiated on the frontal radiograph, which makes it impossible to measure its width. On a lateral radiograph we measured the maximum width of the vertical portion of the rectum, as well as interval not containing contrast medium between the rectum and a contrast marker near the anus on the posterior contour of the tip of the enema (**Figure 2**). This distance is due to the closed anal canal.

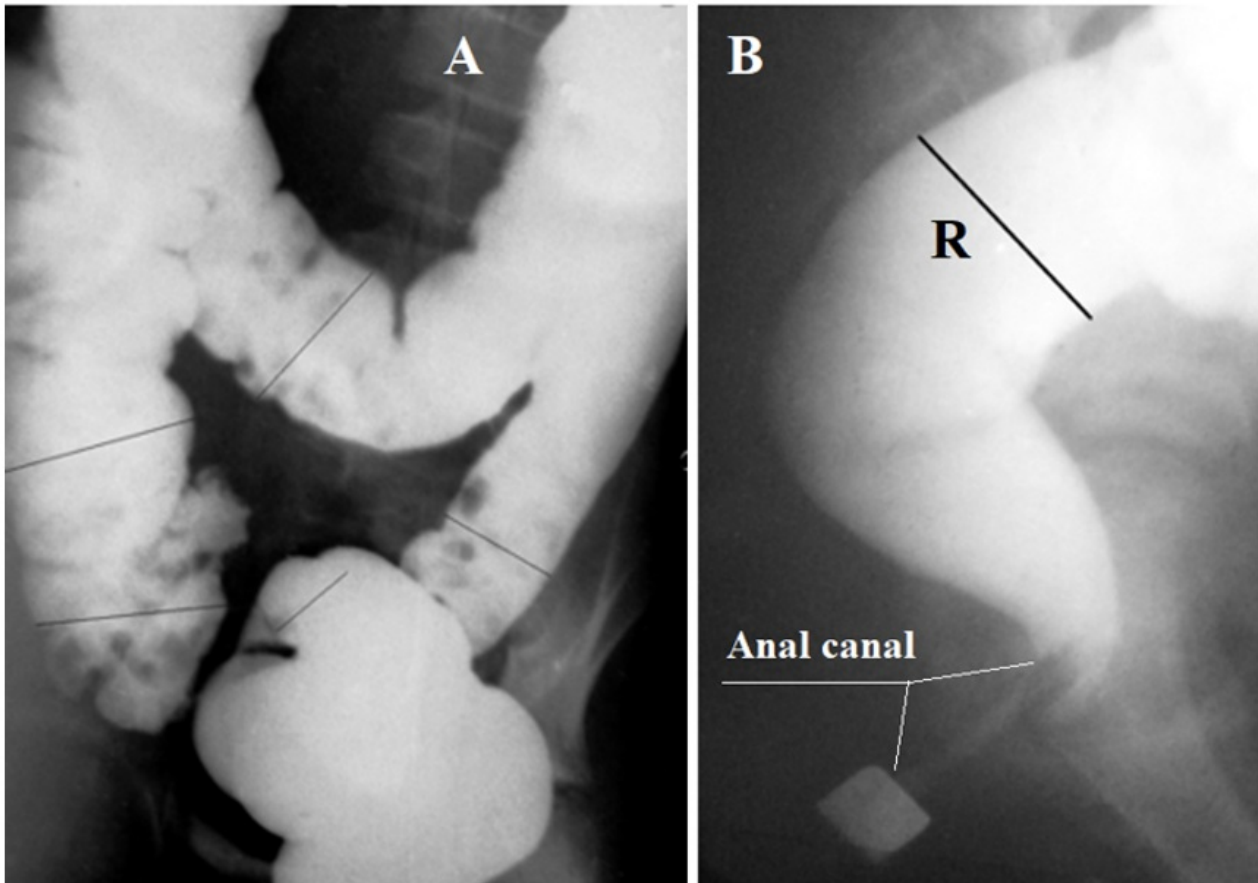


Figure 2. Frontal (A) and lateral (B) radiographs taken during a barium enema. On the frontal radiograph, you can measure all parts of the colon, except for the rectum. Only on the lateral radiograph of the anorectum can one measure the width of the vertical part of the rectum and the length of the anal canal from the rectum to the marker near the anal fossa. Knowing the diameter of the contrast marker, one can calculate the true width of the rectum (R) and the length of the anal canal.

2. In order to measure the width of the bowel, rather than its contents, barium enemas were made after a bowel cleaning.
3. It is necessary to fill the colon under the same hydrostatic pressure to avoid damage to the colon and to ensure that the filling is fast enough. A barium was introduced from the graded bag. The bottom of this bag at the beginning of the study was located 40 cm above the deck of the table. In the first period a barium was introduced into the colon up to the reflux into the terminal ileum. The difference of barium volume in the bag before and after the colon filling corresponds to the colon volume. In practice, we fill the colon up to the splenic angle, because after filling the left half of the colon, the rectum stops increasing in size and its width corresponds to its capacity (**Table 1**).

Table 1. The true width of the rectum and anal canal length in different age groups.

Age	n	Rectal width (cm)	n	Anal canal length (cm)
5 days-11 months	12	1,3-3.0 (2.24±0.09)	7	1.7-2.5 (2.21±0.15)
1-3 years	9	3.0-3.7 (3.21±0.11)	7	2.3-2.8 (2.55±0.10)
4 – 7 years	9	3.0-3.9 (3.43±0.14)	8	2.3-3.6 (3.11±0.10)
8 – 10 years	9	3.2-4.1(3.70±0.06)	8	2.6-3.7 (3.07±0.11)
11 – 15 years	19	3.6-4.6 (39.5±0.07)	18	3.1-3.9 (3.43±0.10)

In children without signs of chronic constipation, we measured all sections of the colon, as shown by the black lines in Figure 2.a. [2]. According to the average indicators for people of different ages, the following graph was built (Figure 3).

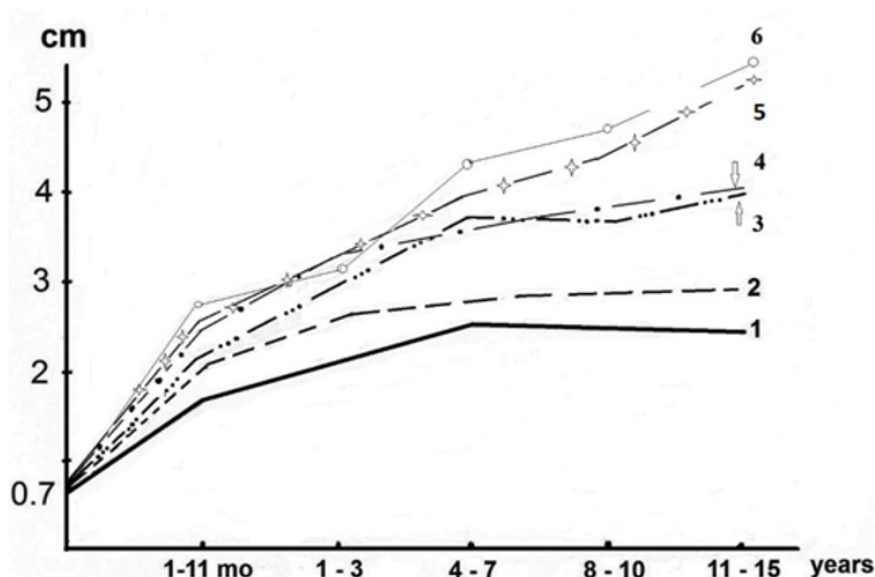


Figure 3. Scheme of expansion of the different parts of the colon and rectum in different age groups: 1-sigmoid colon; 2-descending colon; 3- rectum; 4 - transverse colon; 5 - cecum; 6 - ascending colon [2].

In newborns and children of the first months of life, the width of all sections of the colon is the same. It increases with age disproportionately and always, in each case, retains this proportion.

To compare the different studies as well as studies of the same patient at different ages, we calculate the constant (C), which is the integral characteristic of the colon value.

It is calculated using the following formula:

$$C = \frac{V \times R \times \kappa}{h}$$

Where: **C** – constant, **V** – colon volume (ml).

- **R** – rectal width (cm).
- **κ** – projection distortion factor, which is the ratio of the true width of the marker to its image on the radiograph;
- **h** – patient height (cm).

In healthy children, "Constant" was in the range of 17-31, regardless of age. Megacolon determined if «Constant», exceeds 31. It has been possible to differentiate megacolon varying degrees depending on the constant (C): 1st degree - (C = 31- 45); 2nd degree - (C = 45-60) and 3rd degree - C > 60. For the first time on the radiographs the length of the anal canal has been measured, allowing to determine the state of the PRM.

3. Functional megacolon

Functional megacolon (FM) refers to a disease accompanied by chronic constipation and enlargement of the colon, in the absence of an organic cause (Hirschsprung disease, secondary megacolon, including anorectal malformations, acquired constrictions, Chagas disease, myxedema, spinal lesions). It is known under various names: idiopathic megacolon [12][13], chronic idiopathic constipation [14], anorectal achalasia [15]. Currently, this specific disease is called functional constipation, which also includes a variety of diseases accompanied by chronic constipation, which causes confusion among both pediatricians and surgeons. All authors refer to the pediatric Rome IV criteria (functional disorders of chronic constipation) [16]. The decisions of Rome IV, which are taken by vote, have no scientific value. This is evidenced by the following excerpt: - "The pathophysiology of functional disorders of chronic constipation is not completely understood, although the prevailing hypothesis pertains to a disorder of gut–brain interaction with various factors of relevance, either alone or in combination – these include visceral hypersensitivity, abnormalities in sensory/motor function, delayed colonic transit, and altered central perception" [16]. First, it contradicts all studies of previous generations [11][12][13][14][15]. Secondly, this statement cannot be proved and refuted since it is not substantiated by scientific facts. Thirdly, on this basis it is impossible to build diagnostics and treatment.

Our study is based on the experience of diagnosing and treating 279 children aged 1 to 15 years with functional megacolon (FM), who were treated at the Belarusian Center for Pediatric Surgery in 1980–1985. [17]. In all patients the diagnosis of FM was established based on the barium enema method described above. We divided all patients into 3 groups depending on the main clinical symptom.

3.1. In the 1st group there were 95 patients (M:F - 48:47) with an average age of 5.2 years with complaints of chronic constipation. In 27 children, constipation began from birth, and in the rest from 1 to 5 years (average 2.5 years). In most patients, the feces were large in diameter, and defecation was plentiful. The severity of megacolon is presented in Table 2. In 18% of patients, megacolon was absent. These were children under 4 years of age with a recent onset of constipation.

3.2. In the second group there were 129 patients with an average age of 7.5 years (M:F - 2:1). The main complaint was daytime fecal incontinence. Chronic constipation was in each of them. It appeared at an average age of 3.5 years.

Encopresis arose at a mean age of 5.4 years. After a cleansing enema, the soiling disappeared and reappeared when the stool is held. Each of them had megacolon predominantly 2nd and 3rd degree. In 5% of cases, penetration of barium into the upper part of the anal canal was observed, the length of which was within the normal range. This testified to the weakness of the puborectalis muscle (PRM), which could not press the posterior wall of the anal canal to the tip of the enema [18]. In 23% of patients, a significant shortening of the anal canal was observed, which indicated of the PRM failure. This condition is referred to in the literature as Descending perineum syndrome (DPS), which is manifested by incontinence of feces [19][20][21] (Figure 4).

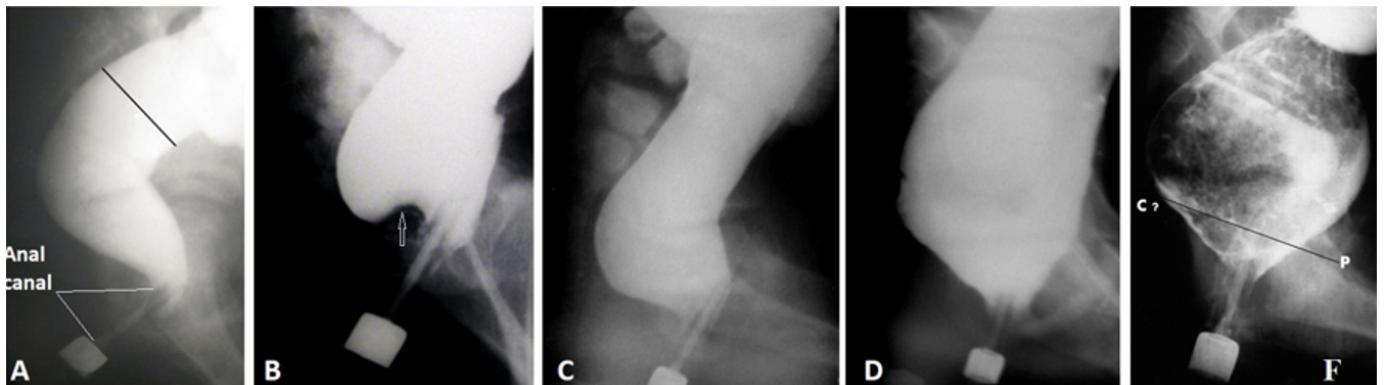


Figure 4. Lateral radiographs of the anorectum in patients with FM at different stages of megacolon development and PRM damage. **(A)** In a 13-year-old patient without constipation, the vertical and horizontal branches of the rectum are determined. On radiographs B-F, the horizontal branch of the rectum is absent due to rectal dilatation. **(B)** A 3-year-old patient has concavity at the base of the rectum (arrow) because of PRM edema. It gives the impression of an elongation of the anal canal. This is the initial phase of FM. **(C)** In a 4-year-old patient, the penetration of barium into the upper part of the anal canal behind the enema tip is determined due to the weakness of the PRM. **(D)** In a 12-year-old patient, a sharp expansion of the rectum is accompanied by the same sharp shortening of the anal canal due to insufficiency of PRM. This is a picture of the descending perineal syndrome, which is often characterized by fecal incontinence. **(F)** The mechanism of anorectal obstruction is shown. The peristaltic wave creates a large force to push a large diameter fecal stone through the anal canal, through which is not able to pass this stone. As a result of the efforts of the rectum, the stone bougienages and stretches the muscles of the pelvic floor, which leads to stretching and weakening of the PRM.

3.3. The third group included 55 patients with a mean age of 8.8 years (M:F-22:33). They were admitted for examination for recurrent abdominal pain. Constipation was reported in only 33 case histories. In 4 patients, constipation was combined with encopresis. In 5 cases, occasionally there was an unformed stool with mucus. In some patients, the feces had an unusually large diameter, but in some it was in the form of sheep's feces. The constant was calculated in 38 cases. The degree of megacolon was markedly less than in the other groups (Table 2).

Table 2. Dependence of the degree of megacolon and the state of PRM on the main clinical symptoms, age, and sex of patients.

Groups	Average age. yrs.	M:F	Degree of megacolon (%)				PRM weakness	DPS
			No	First	Second	Third		
1 st - 95	5.2	48:47	18	39	33	10	5	0
2 nd - 129	7.9	86:43	0	19	40	41	18	23
3 rd - 55	8.8	22:33	13	50	24	13	3	0

Although in 13% of patients the constant was within the normal range, the sigmoid colon was significantly elongated. In it, narrowed or spastic segments were combined with segments much wider than the maximum normal parameters. Slow colon filling during barium enema due to intermittent spastic contractions indicated of high colon tone. Only in one case the PRM was weakened.

Comparison of indicators in the three described groups shows two options for the development of the disease. It always begins with constipation, which eventually leads to the development of megacolon (group 1). In the absence or insufficiently effective treatment, the number of patients with megacolon grade 2 and 3 is increasing. After about two years, a significant proportion of patients develop fecal incontinence, which is explained by weakness or complete insufficiency of PRM (group 2). There are 2 times more males in this group than females. In 13% patients of the 3rd group, megacolon was absent at the time of the study, but the lengthening and segmental expansion of the sigmoid colon indicated that in the earlier period the sigmoid colon was expanded and lengthened (**Figure 5**). Most of the patients had first degree megacolon, and there were no patients with PRM insufficiency. In this group, the majority were females. The clinical and radiological picture indicated an increase in the tone of the colon and the presence of signs of nonspecific inflammation (colitis), which was the cause of recurrent abdominal pain.

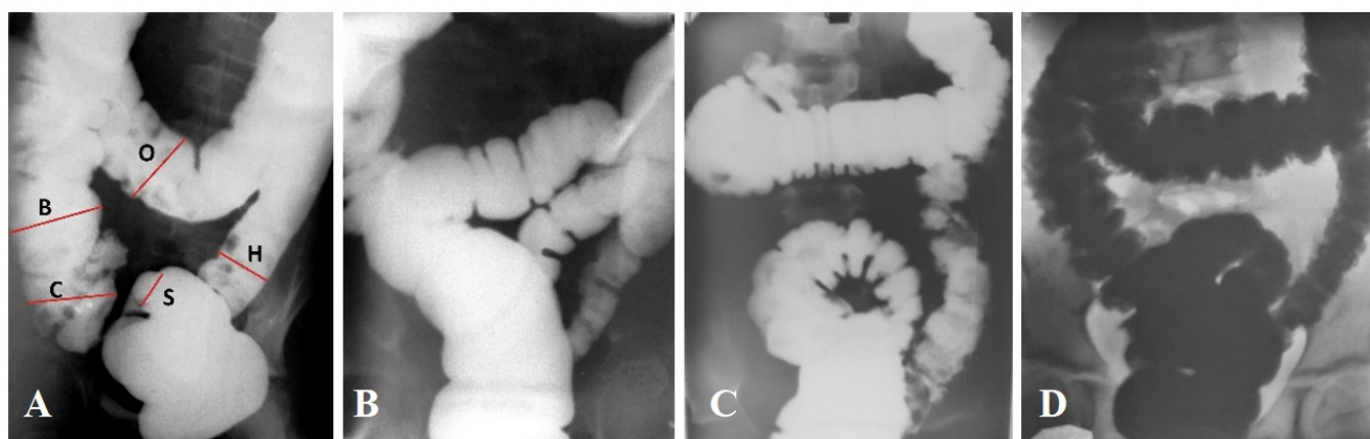


Figure 5. To the pathogenesis of FM in patients of the 3rd group. **(A)**. Barium enema in a patient without colon pathology. The rectum is not visible and cannot be measured. Normal ratio of diameters of different departments. The sigmoid colon is the narrowest and at the age of over 5 years is always in the small pelvis. **(B)**. In a patient with FM, the expansion of the rectum and sigmoid colon is determined. The sigmoid colon is elongated and located in the abdominal cavity. **(C)**. Due to multiple spasms, it was not possible to fill the entire large intestine. All sections of the colon have a normal diameter, except for the sigmoid colon, which extends beyond the pelvis, narrow sections are replaced by wide ones. Very fine asymmetrical haustration. **(D)**. All departments are of normal size, except for the sigmoid colon. The fuzziness (fluffiness) of the contours of the intestine is determined, indicating an inflammatory process.

The pronounced sex difference between groups can be explained by the fact that girls are more open for mothers and receive pathogenetic treatment earlier. Boys complain late when they have a sharp increase in the volume of the colon and damage to the muscles of the pelvic floor (group 2). The third group represents a variant of a favorable outcome, despite abdominal pain. Three factors contribute to the normalization of the stool. First, with age, the width of the anal canal increases, which increases the likelihood of restoration of the passage of feces. Secondly, the example of Hirschsprung's disease shows that a serious violation of the passage of feces causes enterocolitis [22]. Smith and Gill described a clinical syndrome of prestenotic enteritis and enterocolitis consisting of abdominal distention and pain, intermittent diarrhea, and constipation. They considered that "The pathogenesis of this enteritis and enterocolitis apparently is related to partial mechanical obstruction of the bowel with proximal dilatation, stagnation, and capillary stasis [23]. This nonspecific inflammatory process, which was observed in patients of the 3rd group, causes an increase in tone colon, which helps to reduce the size of the intestines, including the rectum, and improves the evacuation of feces. Thirdly, the use of stimulant laxatives also increases intestinal tone, which leads to the same favorable result. However, it is important to stress that the untoward effects which may result from laxative abuse could be greater than those of constipation [14][24][25].

Based on the analysis of the literature and our own research, we came to the following conclusions:

1. The primary stage of the pathogenesis of FM is the discrepancy between the wide fecal masses in the rectum and the throughput of the anal canal, i.e., we are talking about anorectal outlet obstruction.
2. Elongation and expansion of the sigmoid colon, thickening of the colonic wall with histological changes in it, colonic slow transit, and pressure changes in different parts of the colon are secondary to anorectal obstruction. They are proportional to the degree of megacolon.
3. Megarectum is always accompanied by expansion and lengthening of the sigmoid colon. This term can only be used when measuring the rectum, but it cannot be used to describe an illness.
4. Fecal incontinence (encopresis) occurs with grade 3 megacolon because of stretching and weakness PRM (DPS).

4. Megacolon in anorectal malformations

In the article by Brent and Stephens, histological studies of the rectosigmoid junction in children with ARM within a few hours after birth are given. They believed that "The muscle cell dimensions of the viscus at birth indicates that the enlargement was not caused by the stimulus of increased work load prior to birth. Those enlargements present at birth are presumably developmental aberrations of expansion or overgrowth of the cloaca" [26]. Therefore, they suggested the term "primary rectal ectasia as the connotation for this special entity as distinct from megarectum developing to secondary obstruction. In such cases during defect correction, excision or perhaps trimming, of the dilated segment was recommended [26].

Birth defects are structural changes present at birth. Congenital anorectal defects should be divided into two types. A

genetically determined loss of function that is not restored after birth, as suggested by Brent and Stephens [2]. Congenital anorectal disruption of structure and function may occur during fetal development because of increased work of the rectum, which these authors excluded. The first option does not require explanation, as it is an axiom. So let's move on to the second type.

4.1. A narrow ectopic anus leads to the development of megacolon

It is known that (1) almost all ARMs are characterized either by the absence of a fistula or by its sharp narrowing, which disrupts the emptying of the rectum. Animal experiments have shown (2), that the fetus, which urinates routinely, also defecates routinely into the amniotic cavity, even in the absence of distress [27][28]. This was also confirmed by ultrasound examination of pregnant women [29][30]. Kimble et al in 1999 first linked these two phenomena: «Dilation of the rectosigmoid portion of the distal bowel found in newborn infants with anorectal malformations supports the hypothesis that fetal colonic peristalsis and defaecation is a normal physiological process» [31].

Thus, from a theoretical point of view, the expansion of the rectum and the enlargement of muscle cells in newborns with ARM are due to increased work load prior to birth, and not to impaired cloacal development. Based on the histological studies of Brent and Stephens, these changes are reversible after restoration of normal bowel movements [26]. Therefore, the recommendation about excision or perhaps trimming, of the dilated segment is unfounded.

It should be emphasized that we know about muscle fiber enlargement from the Brent and Stephens study, but there is not a single study that proves that newborns with ARM have a wider rectum than healthy newborns. Mitani et al used a rectal pelvic ratio [7]. However, as shown above, this method does not distinguish normal from abnormal.

As literature analysis shows, preservation of the rectum and anal canal leads to better functional outcomes. The European Consortium states that "According to present knowledge, the "fistula" in ARM represents an ectopic anal canal and should be preserved as far as possible to improve the chance for fecal continence" [32]. For example, a comparison of the results of treatment of ARM with perineal fistula in boys showed a significant advantage of the cutback procedure (**Table 3**) compared to posterior sagittal anorectoplasty (PSARP) [33]. It is important that after the cutback procedure no fecal incontinence is observed at all, and constipation gradually disappears [34].

Table 3. The results of the cutback procedure

Authors	Results		
	Good (%)	Fair (%)	Poor (%)
Ackroyd et al [35]	98	0	2
Kyrklund et al [34]	85	15	0
De la Fuente [36]	90	8	2
Nixon [37]	90	?	?

Stenström et al long-term outcomes were studied after PSARP. In the median age 8 years "Among those with a perineal fistula, incontinence occurred in 42% of the females and in 10% of the males whereas constipation occurred in 62% of the females and 35% of the males" [33]. **Figure 6** shows how a megacolon appears due to a narrow ectopic anus.

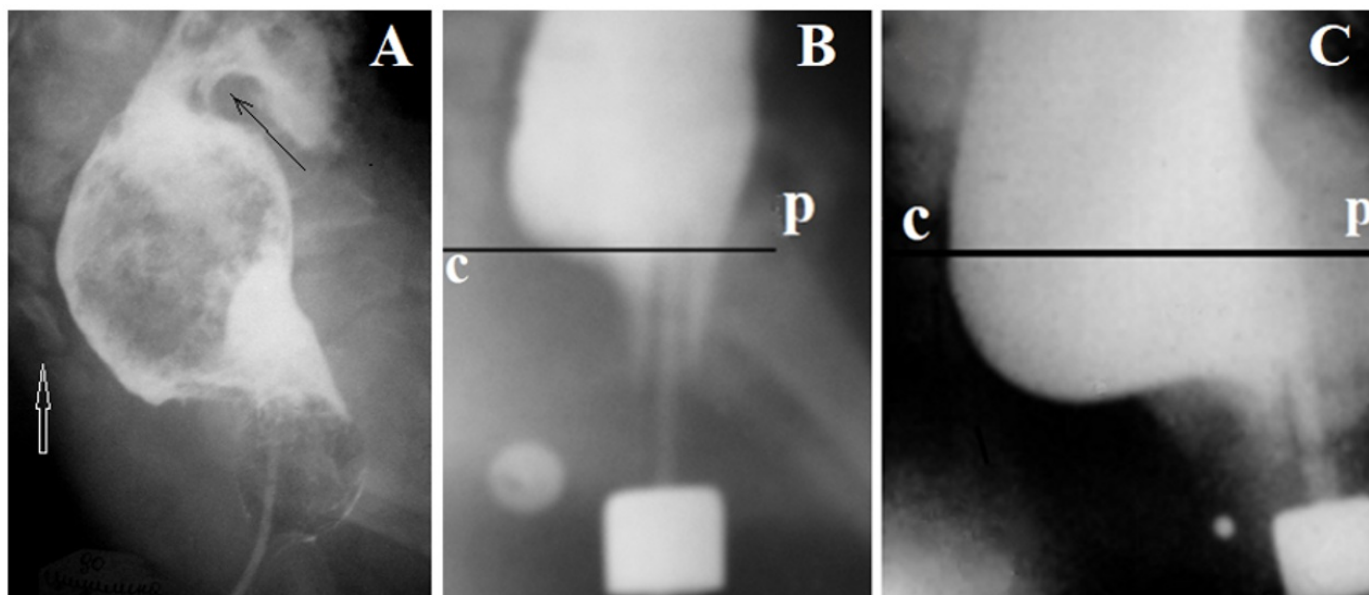


Figure 6. Lateral radiographs of the anorectum of patients with ARM with visible fistulas. **(A).** The Foley catheter was inserted into the rectum through the perineal fistula. A contrast agent was introduced into the rectum and the balloon was inflated to a diameter of 2 cm. The catheter was pulled into the anal canal until it stops. The balloon is stuck over a narrow fistula. The peristaltic wave (black arrow) pushes the fecal stone, which leads to stretching of the pelvic muscles below the last coccygeal vertebra (white arrow) and shortening of the anal canal. **(B-C).** Radiographs of the same girl with a vestibular fistula at different ages. P-C is the pubococcygeal line. The true diameter of the contrast marker strung on the tip of the enema is 1.6 cm. It is located near the fistula orifice. **(B).** At the age of 8 month the permanent contraction of the ectopic anal canal was observed during the barium enema. Its length is 2.5 cm, which corresponds to the age norm. The width of the rectum is 3.4 cm, which is greater than the maximum normal limit (3 cm) (megarectum). Barium penetrates the anal canal behind the tip of the enema. This shows the weakness of the PRM, which does not pull the posterior wall of the anal canal forward. **(C).** At the age of 1.5 years, she had severe constipation and soiling. The width of the rectum is 5.5 cm, which significantly exceeds the maximum limit of the norm for this age (3.7 cm). A megarectum is combined with a significant shortening of the anal canal. Its length is 1.9 cm (the minimal limit is 2.3 cm). Conclusion. An ARM with vestibular ectopy, megarectum, and descending perineum syndrome.

An analysis of the literature indicates that the ectopic opening on the perineum and the vestibule of the vagina is always represented by a narrow rigid ring at the site of penetration of the subcutaneous tissue and skin. Although the degree of constriction varies, it always interferes with normal defecation and sooner or later leads to the development of megacolon. Therefore, transection of the rigid ring should be performed as early as possible to prevent the development of megacolon and damage to the PRM [35][34][36][37][38].

4.2. Pathological anatomy anorectum after pull-through surgery

We need to understand why boys with a perineal fistula do not have fecal incontinence after the cutback procedure, and the constipation gradually resolves [34], but after PSARP among those with a perineal fistula, incontinence occurs in 42%

of the females and in 10% of the males whereas constipation occurs in 62% of the females and 35% of the males [33].

To understand the huge difference between the results of cutback procedure and pull-through surgery, some circumstances should be explained. 1) We compare the results of treatment only for perineal fistulas, because only in this type of ARM these treatments are used. 2) We do not distinguish between different approaches, since the results of treatment with PSARP, ASARP and laparoscopic assisted anorectoplasty do not significantly depend on the approach [39][40].

4.3. Pathological physiology of ARM with visible fistulas

An ectopic anal canal is characterized by normal function of the internal anal sphincter (IAS), puborectalis muscle (PRM), as well as the deep and superficial parts of the external anal sphincter (EAS), which, due to nerve connections, are involved in the reflexes of the fecal retention and defecation. In all types of ARMs, except for congenital anal stenosis, there is no function of the very short subcutaneous portion of the EAS, which shortly contracts during intra-abdominal pressure rises, such as when coughing or rising from a seated position. Of great importance is the contraction of levator plates, the contraction of which opens the anal canal along its entire length to facilitate the passage of feces during defecation [41][42].

If maintaining an ectopic anal canal at low types of ARMs with a cutback procedure leads to good functional results, and constipation resolves over time. So why do the same patients develop severe chronic constipation after PSARP?

With pull-through surgery, regardless of an approach, a functioning anal canal is destroyed. IAS is excised under the pretext that it is a fistula or rectal pouch. The PRM intersects together with the deep and superficial parts of the EAS. The denervated and bled rectum is isolated from the surrounding tissues and placed at the site of the excised IAS. The levator plates torn from the rectum do not open the anal canal during defecation attempts. The crossing of invisible neural connections permanently turns off the stool retention and defecation reflexes. Thus, a functioning ectopic anal canal turns into a non-functioning perineal fistula. Chronic constipation is caused by fecal retention over a poorly passable outlet channel. As a result, fecal masses are retained in the rectum and the left half of the colon, causing the expansion of these departments (megarectum and megacolon). In cases where the outlet channel between the rectum and the anus is wide enough and does not interfere with the emptying of the rectum, then instead of chronic constipation, the patient suffers from fecal incontinence.

The present study confirms the conclusion of the European Consortium that ARMs represent an ectopic anal canal that should be preserved as far as possible to improve the chance for fecal continence. All pull-through operations lead to the destruction of the anal canal, and this is what leads to severe chronic constipation and megacolon.

Conclusion

A method for determining megacolon and anal canal function in children of different ages is described. This made it

possible to establish that acquired megacolon is always of an obstructive nature, either over constriction or because of a dysfunction of the anal canal.

References

- ^a Cuda T, Gunnarsson R, de Costa A. Symptoms and diagnostic criteria of acquired Megacolon - a systematic literature review. *BMC Gastroenterol*. 2018 Jan 31;18(1):25. <http://doi.org/10.1186/s12876-018-0753-7>.
- ^{a, b, c, d, e} Levin MD. Radiological anatomy of the colon and rectum in children. *Gastroenterology & Hepatology*. 2019; 10 (2):82-6. (Open access).
- ^a Kim HJ, Kim AY, Lee CW, et al. Hirschsprung disease and hypoganglionosis in adults: radiologic findings and differentiation. *Radiology*. 2008 May;247(2):428-34. <http://doi.org/10.1148/radiol.2472070182>.
- ^a Levin MD. Diagnosis and pathophysiology of Hirschsprung's disease. *Pelviperrineology* 2021;40(2):96-102. <http://doi.org/10.34057/PPj.2021.40.02.006>. (Open access).
- ^{a, b} Meunier P, Louis D, Jaubert de Beaujeu M. Physiologic investigation of primary chronic constipation in children: comparison with the barium enema study. *Gastroenterology*. 1984 Dec;87(6):1351-7.
- ^{a, b, c, d} van der Plas RN, Benninga MA, Staalman CR, et al. Megarectum in constipation. *Arch Dis Child*. 2000 Jul;83(1):52-8. <http://doi.org/10.1136/adc.83.1.52>.
- ^{a, b} Mitani Y, Kubota A, Goda T, et al. Laparoscopic-Assisted Total Resection and Endorectal Pull-Through Technique for Congenital Megarectum with Anorectal Malformation. *J Pediatr Surg*. 2023 Jul;58(7):1269-1273. <http://doi.org/10.1016/j.jpedsurg.2023.01.061>.
- ^{a, b} Gladman MA, Dvorkin LS, Scott SM, et al. A novel technique to identify patients with megarectum. *Dis Colon Rectum*. 2007 May;50(5):621-9. <http://doi.org/10.1007/s10350-006-0805-x>.
- ^a Gladman MA, Knowles CH. Novel concepts in the diagnosis, pathophysiology and management of idiopathic megabowel. *Colorectal Dis*. 2008 Jul;10(6):531-8; discussion 538-40. <http://doi.org/10.1111/j.1463-1318.2007.01457.x>.
- ^a Koppen IJ, Yacob D, Di Lorenzo C, et al. Assessing colonic anatomy normal values based on air contrast enemas in children younger than 6 years. *Pediatr Radiol*. 2017; 47(3): 306–312. <http://doi.org/10.1007/s00247-016-3746-0>.
- ^{a, b} Levin MD. Reaction to Koppen et al., 'Assessing colonic anatomy normal values based on air contrast enemas in children younger than 6 years'. *Pediatr Radiol*. 2018 Oct;48(11):1674-1677. <http://doi.org/10.1007/s00247-018-4181-1>.
- ^{a, b} Gladman MA, Scott SM, Lunniss PJ, et al. Systematic review of surgical options for idiopathic megarectum and megacolon. *Ann Surg*. 2005 Apr;241(4):562-74. <http://doi.org/10.1097/01.sla.0000157140.69695.d3>.
- ^{a, b} Villanueva MEP, Lopez MPJ, Onglao MAS. Idiopathic megacolon and megarectum in an adult treated with laparoscopic modified Duhamel procedure. *BMJ Case Rep*. 2021 Jun 29;14(6):e240209. <http://doi.org/10.1136/bcr-2020-240209>.
- ^{a, b, c} Shafik A. Constipation. Pathogenesis and management. *Drugs*. 1993 Apr;45(4):528-40. <http://doi.org/10.2165/00003495-199345040-00005>.
- ^{a, b} Bourdelat D, Barbet JP, Gross P. Constipation de l'enfant. Intérêt de la sphinctéromyectomie anorectale [Constipation in children. Value of anorectal sphincteromyectomy]. *Chirurgie*. 1994-1995;120(1):48-52.

16. ^{a, b} Aziz I, Whitehead WE, Palsson OS, et al. An approach to the diagnosis and management of Rome IV functional disorders of chronic constipation. *Expert Rev Gastroenterol Hepatol*. 2020 Jan;14(1):39-46. <http://doi.org/10.1080/17474124.2020.1708718>.
17. [^] Levin MD. Funktsiona'lnyĭ megakolon u detei [Functional megacolon in children]. *Pediatriia*. 1989; (8):22-7. Russian. (PubMed).
18. [^] Levin MD. [Descending perineum syndrome in children: Pathophysiology and diagnosis]. *Vestn Rentgenol Radiol*. 2015 Sep-Oct; (5):27-35. PubMed.
19. [^] Chaudhry Z, Tarnay C. Descending perineum syndrome: a review of the presentation, diagnosis, and management. *Int Urogynecol J*. 2016 Aug;27(8):1149-56. <http://doi.org/10.1007/s00192-015-2889-0>.
20. [^] Wang XJ, Chedid V, Vijayvargiya P, et al. Clinical Features and Associations of Descending Perineum Syndrome in 300 Adults with Constipation in Gastroenterology Referral Practice. *Dig Dis Sci*. 2020 Dec;65(12):3688-3695. <http://doi.org/10.1007/s10620-020-06394-0>.
21. [^] Levin MD. Pathophysiology and diagnosis of descending perineum syndrome in children. *Pelviperineology* 2018; 37: 52-56 <http://www.pelviperineology.org>. (Open access).
22. [^] Gershon EM, Rodriguez L, Arbizu RA. Hirschsprung's disease associated enterocolitis: A comprehensive review. *World J Clin Pediatr*. 2023 Jun 9;12(3):68-76. <http://doi.org/10.5409/wjcp.v12.i3.68>.
23. [^] Smith EI, Gill CC. Prestenotic enteritis and enterocolitis in children: Description of a syndrome and review of five cases. *South Med J*. 1975 Apr;68(4):426-427.
24. [^] Bischoff A, Brisighelli G, Dickie B, et al. Idiopathic constipation: A challenging but manageable problem. *J Pediatr Surg*. 2018 Sep;53(9):1742-1747. <http://doi.org/10.1016/j.jpedsurg.2017.09.022>.
25. [^] Levin MD. Why and when does an enema provoke abdominal pain? Reaction to the article by Peña et al. *J Pediatr Surg*. 2021 Jan 26;S0022-3468(21)00079-8. <http://doi.org/10.1016/j.jpedsurg.2021.01.029>.
26. ^{a, b, c} Brent L, Stephens FD. Primary rectal ectasia. A quantitative study of smooth muscle cells in normal and hypertrophied human bowel. *Prog Pediatr Surg*. 1976;9:41-62.
27. [^] Kizilcan F, Karnak I, Tanyel FC, et al. In utero defecation of the nondistressed fetus: a roentgen study in the goat. *J Pediatr Surg*. 1994 Nov;29(11):1487-90. [http://doi.org/10.1016/0022-3468\(94\)90152-x](http://doi.org/10.1016/0022-3468(94)90152-x).
28. [^] Ciftçi AO, Tanyel FC. In utero defecation: a new concept. *Turk J Pediatr*. 1998 Jan-Mar;40(1):45-53.
29. [^] Ramón y Cajal CL, Martínez RO. Defecation in utero: a physiologic fetal function. *Am J Obstet Gynecol*. 2003 Jan;188(1):153-6. <http://doi.org/10.1067/mob.2003.107>.
30. [^] Ramón Y Cajal CL, Martínez RO. In-utero defecation between weeks 14 and 22 of gestation: stools are whitish. *Ultrasound Obstet Gynecol*. 2004 Jan;23(1):94-5. <http://doi.org/10.1002/uog.239>.
31. [^] Kimble RM, Trudinger B, Cass D. Fetal defaecation: is it a normal physiological process? *J Paediatr Child Health*. 1999 Apr;35(2):116-9. <http://doi.org/10.1046/j.1440-1754.1999.00314.x>.
32. [^] Amerstorfer EE, Schmiedeke E, Samuk I, et al. Clinical Differentiation between a Normal Anus, Anterior Anus, Congenital Anal Stenosis, and Perineal Fistula: Definitions and Consequences-The ARM-Net Consortium Consensus. *Children (Basel)*. 2022 Jun 3;9(6):831. <http://doi.org/10.3390/children9060831>.
33. ^{a, b, c} Stenström P, Kockum CC, Emblem R, et al. Bowel symptoms in children with anorectal malformation - a follow-up

- with a gender and age perspective. *J Pediatr Surg.* 2014 Jul;49(7):1122-30. <http://doi.org/10.1016/j.jpedsurg.2013.10.022>.
34. ^{a, b, c, d}Kyrklund K, Pakarinen MP, Taskinen S, et al. Bowel function and lower urinary tract symptoms in males with low anorectal malformations: an update of controlled, long-term outcomes. *Int J Colorectal Dis.* 2015 Feb;30(2):221-8. <http://doi.org/10.1007/s00384-014-2074-9>.
35. ^{a, b}Ackroyd R, Nour S. Long-term faecal continence in infants born with anorectal malformations. *J R Soc Med.* 1994 Nov;87(11):695-6.
36. ^{a, b}de la Fuente AQ, Arance MG, Cortés L. [Low ano-rectal malformations. *An Esp Pediatr.* 1979 Aug-Sep;12(8-9):603-6.
37. ^{a, b}Nixon HH. Anorectal anomalies: with an international proposed classification. *Postgrad Med J.* 1972 Aug; 48(562): 465–470. <http://doi.org/10.1136/pgmj.48.562.465> 12.
38. [^]Levin MD. [The pathological physiology of the anorectal defects, from the new concept to the new treatment]. *Eksp Klin Gastroenterol.* 2013; (11):38-48. Russian. (PubMed).
39. [^]Gupta CR, Bhoj T, Mohta A, et al. Comparison of clinical outcome and anal manometry following laparoscopic-assisted anorectoplasty and posterior sagittal anorectoplasty in patients with high and intermediate anorectal malformation: A randomised controlled trial. *Afr J Paediatr Surg.* 2022 Jul-Sep;19(3):160-163. http://doi.org/10.4103/ajps.AJPS_176_20.
40. [^]Zhou Y, Xu H, Ming A, et al. Laparoscopic-Assisted Anorectoplasty for Rectovestibular Fistula: A Comparison Study with Anterior Sagittal Anorectoplasty. *Eur J Pediatr Surg.* 2022 Oct;32(5):408-414. <http://doi.org/10.1055/s-0041-1740157>.
41. [^]Levin MD. Anatomy and physiology of anorectum: the hypothesis of fecal retention, and defecation. *Pelviperrineology* 2021;40(1):50-57. <http://doi.org/10.34057/PPj.2021.40.01.008>.
42. [^]Levin MD. Anorectal Malformations with Visible Fistulas. Theoretical Substantiation of a New Version of the Cutback Procedure. *Qeios, CC-BY 4.0 · Article, August 30, 2023.* <https://doi.org/10.32388/D048J0>.