

[Open Peer Review on Qeios](#)

# Low Donor Site Morbidity Supports the Use of Infraumbilical Flaps for Head and Neck Reconstruction: A Retrospective Cohort Study

Giordana Bettini<sup>1</sup>, Giorgia Saia<sup>2</sup>, Piero Franco<sup>2</sup>, Stefano Valsecchi, Laura Tognin<sup>3</sup>, Enrico Alexandre, Alberto Bedogni<sup>2</sup>

<sup>1</sup> University-Hospital of Padova

<sup>2</sup> University of Padua

<sup>3</sup> University of Parma

**Funding:** No specific funding was received for this work.

**Potential competing interests:** No potential competing interests to declare.

## Abstract

**Background:** Currently, the standard design of the skin component of abdominal soft-tissue flaps recommended for head and neck reconstruction encompasses the upper and lower periumbilical region to include the maximum number of myocutaneous perforators. Yet, this flap design precludes the harvest of bilateral flaps and the use of the contralateral area in case of flap failure. **Aim:** We aimed at proving the long-term safety of infraumbilical abdominal free flaps in terms of abdominal wall integrity.

**Methods:** Consecutive subjects who underwent reconstruction of composite cervico-facial defects with infraumbilical free flaps between 2008 - 2020 were enrolled. After surgery, patients were followed up at three-month intervals to evaluate the incidence of any complications at the donor site.

**Results:** 25 patients underwent reconstruction with free flaps from the lower abdomen. A total of 35 abdominal flaps were performed; ten patients underwent bilateral flap harvest. Marginal abdominal skin necrosis occurred in 3 patients. Abdominal bulge occurred in one case; neither hernia nor abdominal wall weakness was encountered at a median follow-up of 12 months. **Conclusions:** The infraumbilical region is a safe donor area of free flaps for head and neck reconstruction that preserves abdominal wall firmness and provides a satisfactory cosmetic result at the donor site.

**Giordana BETTINI, MD<sup>1,2</sup>, Giorgia SAIA, MD<sup>1,2</sup>, Piero FRANCO, MD<sup>3</sup>, Stefano VALSECCHI, MD<sup>4</sup>, Laura TOGNIN, MD<sup>5</sup>, Enrico ALEXANDRE, MD<sup>6</sup>, Alberto BEDOGNI, MD<sup>1,2</sup>**

<sup>1</sup> *Unit of Maxillofacial Surgery, Department of Neuroscience, University of Padova, Via Giustiniani 2 – 35128, Padova, Italy. G.B., [giordana.bettini@unipd.it](mailto:giordana.bettini@unipd.it); G.S., [giorgia.saia@unipd.it](mailto:giorgia.saia@unipd.it); A.B., [alberto.bedogni@unipd.it](mailto:alberto.bedogni@unipd.it).*

<sup>2</sup> *Regional Center for the Prevention, Diagnosis and Treatment of Medication and Radiation-related Bone Diseases of the Head and Neck, Azienda Ospedale-Università Padova, Via Giustiniani 2 – 35128, Padova, Italy.*

<sup>3</sup> *Orthopaedic Clinic - CTO, University of Florence, Largo Piero Palagi, 1 – 50139, Florence, Italy. P.R., [piero.franco@unifi.it](mailto:piero.franco@unifi.it).*

<sup>4</sup> Unit of Maxillofacial Surgery, S. Anna Hospital, Via Ravona, 20 – 22042, Como, Italy. S.V. [stefano.valsecchi@asst-lariana.it](mailto:stefano.valsecchi@asst-lariana.it).

<sup>5</sup> Unit of Maxillofacial Surgery, Azienda Ospedaliera-Universitaria of Parma, Viale A. Gramsci, 14 – 43126, Parma, Italy. L.T., [laura.tognin@unipr.it](mailto:laura.tognin@unipr.it).

<sup>6</sup> Unit of Otolaryngology, Department of Neurosciences, University of Padova, Via Giustiniani 2 – 35128, Padova, Italy. E.A., [alexandre.enrico@gmail.com](mailto:alexandre.enrico@gmail.com).

**Corresponding author:** Dr. Bettini Giordana, Unit of Maxillofacial Surgery, Department of Neuroscience-DNS, University of Padova, Via Giustiniani 2 - 35128, Padova, Italy.

Phone: +39 049 821 2039; Fax: +39 049 821 2111; e-mail: [giordana.bettini@unipd.it](mailto:giordana.bettini@unipd.it)

**Running head:** Donor site in infraumbilical flaps.

**Keywords:** Deep Inferior Epigastric Artery perforator flap; Rectus Abdominis myocutaneous flap; donor site morbidity; infraumbilical region; Head and Neck cancer; abdominoplasty.

## Synopsis

The cohort study addressed the infraumbilical design of free flaps for head and neck defects reconstruction based on the observations that the inferior abdominal wall provided a bilateral harvest of large volume tissues, a contralateral backup option in case of first flap failure, associated with donor site direct closure and minimal morbidity.

## 1. Introduction

The abdominal wall has become an increasingly popular donor site for head and neck reconstruction. Several studies demonstrated the feasibility of different perforator flaps from the abdominal region as a suitable donor site to well fit defects with varied sizes and shapes in head and neck reconstruction.<sup>[1][2][3]</sup>

Usually, the skin component of the Transverse/Vertical Rectus Abdominis myocutaneous flap (TRAM/VRAM) and Deep Inferior Epigastric Artery Perforator (DIEAP) flap used for reconstructive purposes in the cervicofacial area, is selectively designed to cover the periumbilical area of the lower and upper abdomen to include the dominant perforators, hence harvesting highly vascularized flaps.<sup>[4]</sup>

Initially, it was a common belief that multiple perforators provided better vascularization of the flap. Various studies instead proved that flap survival is mainly determined by the distance between the main perforators and the midline. The latter

statement is particularly true when considering the viability of zone 4.<sup>[5]</sup>

Therefore, the flap is now routinely pedicled by only one or two medial row perforators that emerge from the medial branch of the deep inferior epigastric artery in the paraumbilical area, where the skin component is safely designed.<sup>[4][6]</sup>

Different skin paddle designs extending over the entire abdominal wall (vertically, horizontally, or obliquely oriented) have been successfully described to increase the amount of viable tissue harvested based on periumbilical perforators.<sup>[7][8]</sup>

However, in case of large defects requiring bilateral flaps, the harvest of a periumbilical skin paddle is generally associated with poor aesthetic outcomes. These result from worse abdominal contour and a less concealable scar when compared to the harvest of a flap in the inferior aspect of the abdomen.<sup>[7]</sup>

We assessed the long-term safety of abdominal soft-tissue free flaps harvested from the infraumbilical region in terms of abdominal wall integrity and cosmetic result with the aim of proving its reliability also for head and neck reconstruction purposes.

## 2. Patients and Methods

### 2.1. Study design and setting

A multicenter retrospective cohort study on consecutive patients who underwent reconstruction of composite defects of the Head and Neck region with infraumbilical abdominal free flaps was performed at the Units of Maxillofacial Surgery of Padua and Verona (Italy). The study was conducted in accordance with the Declaration of Helsinki and the international standards of Good Clinical Practice and all patient gave their informed consent.

### 2.2. Patients

Consecutive subjects who underwent primary or delayed reconstruction of major head and neck soft tissue defects with abdominal perforator free flaps from the infraumbilical area were eligible for the study.

### 2.3. Data collection and variables

The clinical charts of the patients treated at our Units between January 2008 and January 2020 were reviewed. Relevant clinical data were extracted and entered into an electronic spreadsheet form. The following data were collected from the clinical charts: age, sex, reason for surgery (diagnosis), date of surgery, type of flap harvest, side of the flap harvest, size of the skin flap component, type of abdominal wall closure; cervicofacial defect type and size were also recorded.

### 2.4. Surgery

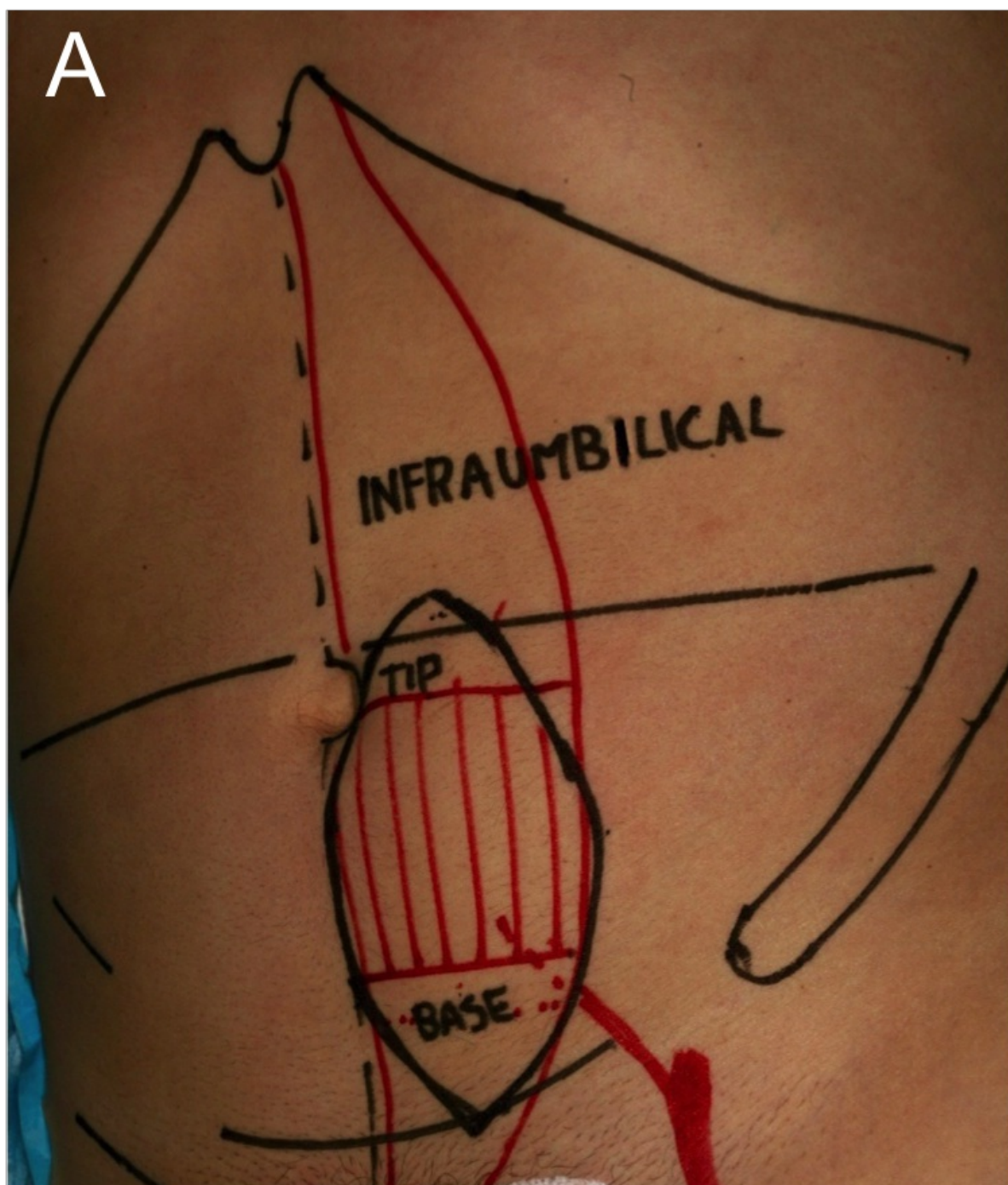
All cases treated at the recruiting centers had been routinely discussed at the institutional multidisciplinary head and neck

oncology board that included the oncologist, the radiotherapist, the radiologist, and the head and neck surgeons. Thereafter, the ablative and reconstructive treatment options were assessed by experienced head and neck microsurgeons (A.B., S.V.) and discussed with the patients and their relatives. Surgical procedures were performed by the same operators (A.B., S.V.) in all cases. During the preoperative examination, every suitable and sizeable perforator found at the level of or below the umbilicus could be included in the infraumbilical flap design. At the beginning of our experience, contrast-enhanced CT scans of the upper and lower abdomen taken at the time of whole-body CT assessment for metastatic disease were used to identify the perforator. These latter were also probed with a portable Doppler to select the dominant perforator and marked on the abdominal skin. Starting in 2015, computed tomographic angiography (CTA) was routinely performed to increase the reliability of perforator identification.<sup>[9][10][11]</sup>

In cases of a single infraumbilical DIEAP flap harvest for coverage of medium-sized defects of the cheek and the cervical region, the flap was centered on the site with the most suitable perforator as detected with CTA; the skin from zone 1-2 are usually well furnished by a single perforator from the medial row. Nevertheless, such a limited amount of tissue can be also based on a lateral perforator. When the entire inferior abdominal skin (zone 1-4) was required for massive neck defect reconstruction, we used flow-through intra-flap anastomosis between DIEAP pedicles.<sup>[12]</sup> When simultaneous reconstruction of different anatomical and functional areas of the cervicofacial region (e.g. tongue and cheek) required two different flaps (DIEAP and a VRAM flap), site selection of the DIEAP prevailed and VRAM came accordingly.

At the time of surgery, linear dimensions of the planned defect size and shape were preoperatively assessed to properly mark the area of the skin component of the flap on the lower aspect of the abdomen. High-definition intraoperative pictures of the planned abdominal flap design were obtained after skin marking.

The skin paddle was designed in the lower abdomen based on periumbilical perforators in the area beneath the umbilicus. For the unilateral harvest of flaps, the abdominal skin paddle was oriented vertically. Typically, the skin island is comprised between the umbilicus and the suprapubic crease. In muscle-containing flap (e.g., VRAM), the skin paddle was centered over the carrier rectus muscle. (Figure 1a)

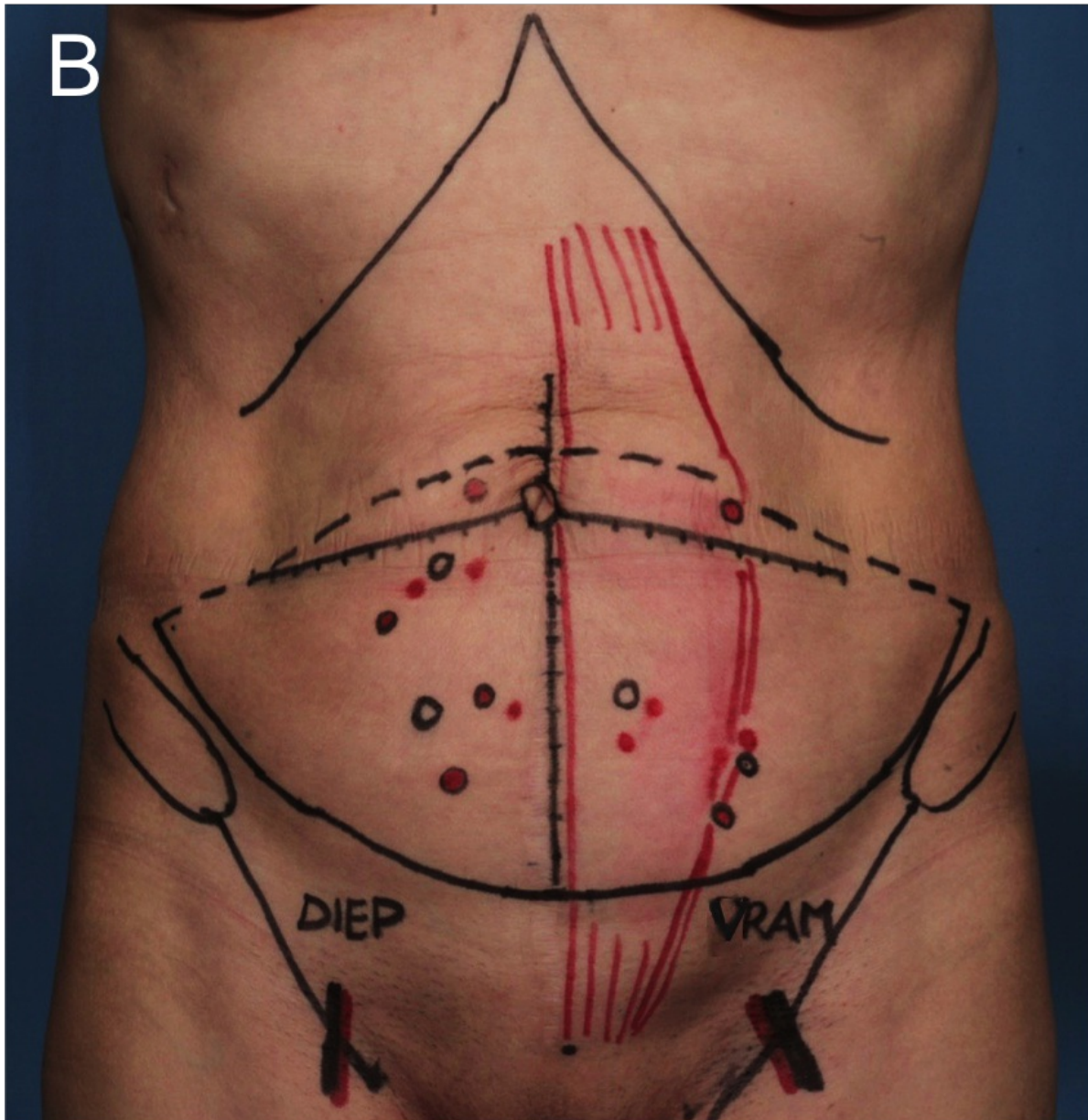


**Figure 1. Skin paddle design of infraumbilical abdominal flaps. (A)** Preoperative skin markers of left infraumbilical VRAM flap designed after standard anatomical landmarks tracking (intercostal inferior border, line crossing the umbilicus, iliac crest, linea alba, and the pubic symphysis in black colored reference lines). The skin paddle was outlined along the linea alba centered on the carrier RA muscle (red grid) and extending over the lower abdominal wall between the umbilicus and the pubis. The superior aspect of the skin incision was marked shortly encompassing the umbilicus line to eventually correct an ear-dog deformity.

For the bilateral harvest of flaps, the abdominal skin paddles were designed to cover both sides of the inferior aspect of the anterior abdominal wall, with the patient in the supine position and the knees slightly flexed.<sup>[13]</sup>



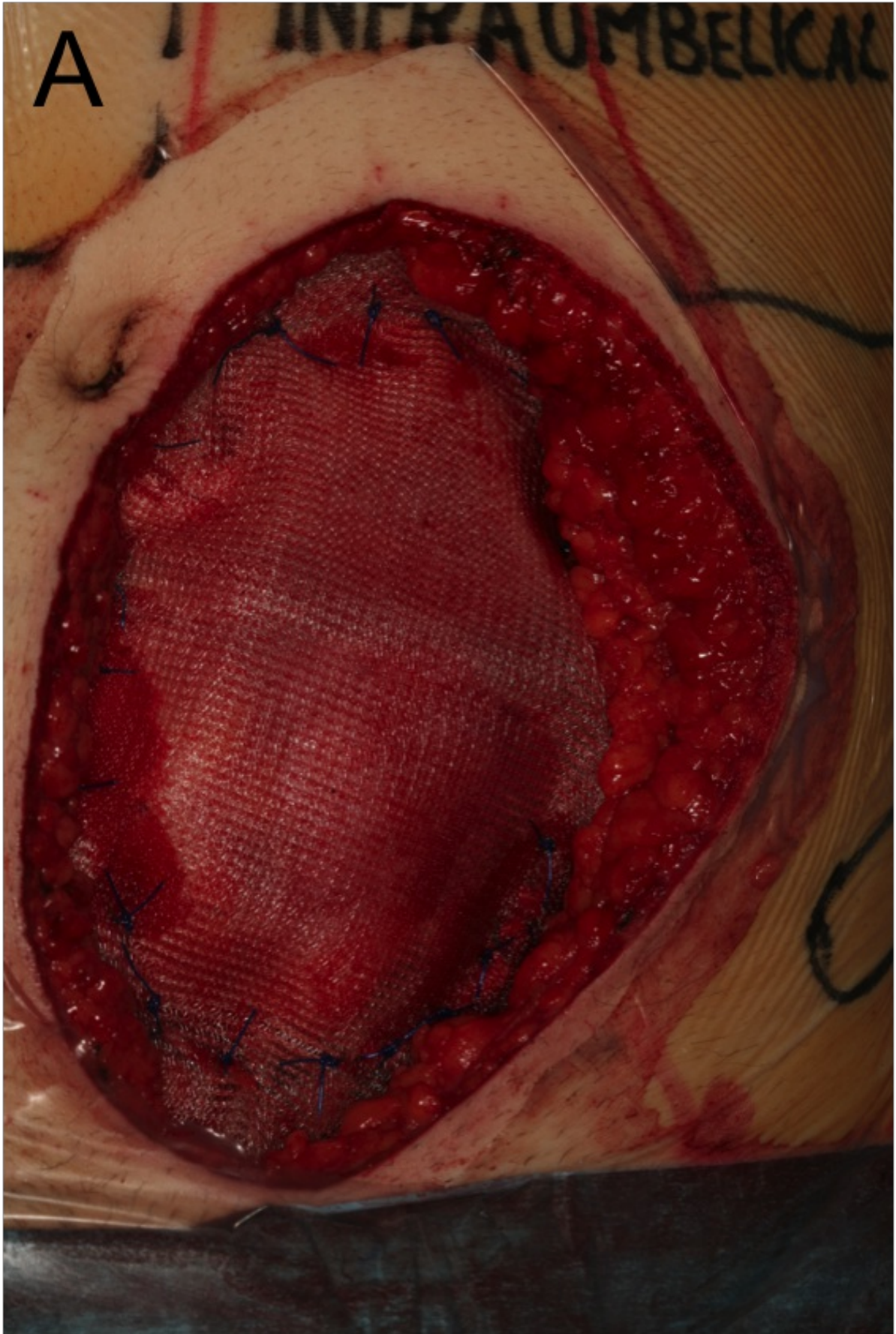
Typically, the lower incision is transversely placed at the suprapubic crease and above the inguinal ligament up to the anterior superior iliac spines (ASIS). The upper incision is placed above the umbilicus and gently curves laterally to reach the ASIS. (Figure 1b)



**Figure 1.** Skin paddle design of infraumbilical abdominal flaps. (B) Preoperative skin markers of bilateral infraumbilical flap (simultaneous right DIEAP and left VRAM) after standard anatomical landmarks tracking (see above). Probe detection of two-sided main pedicles and paraumbilical perforators was also outlined (main and minor vessels in black and red circles respectively).

When a VRAM flap was planned, a full-width harvest of the RA muscle and anterior rectus sheet above the arcuate line was performed. Careful dissection of the deep inferior epigastric pedicle down to its origin from the iliac vessels provided

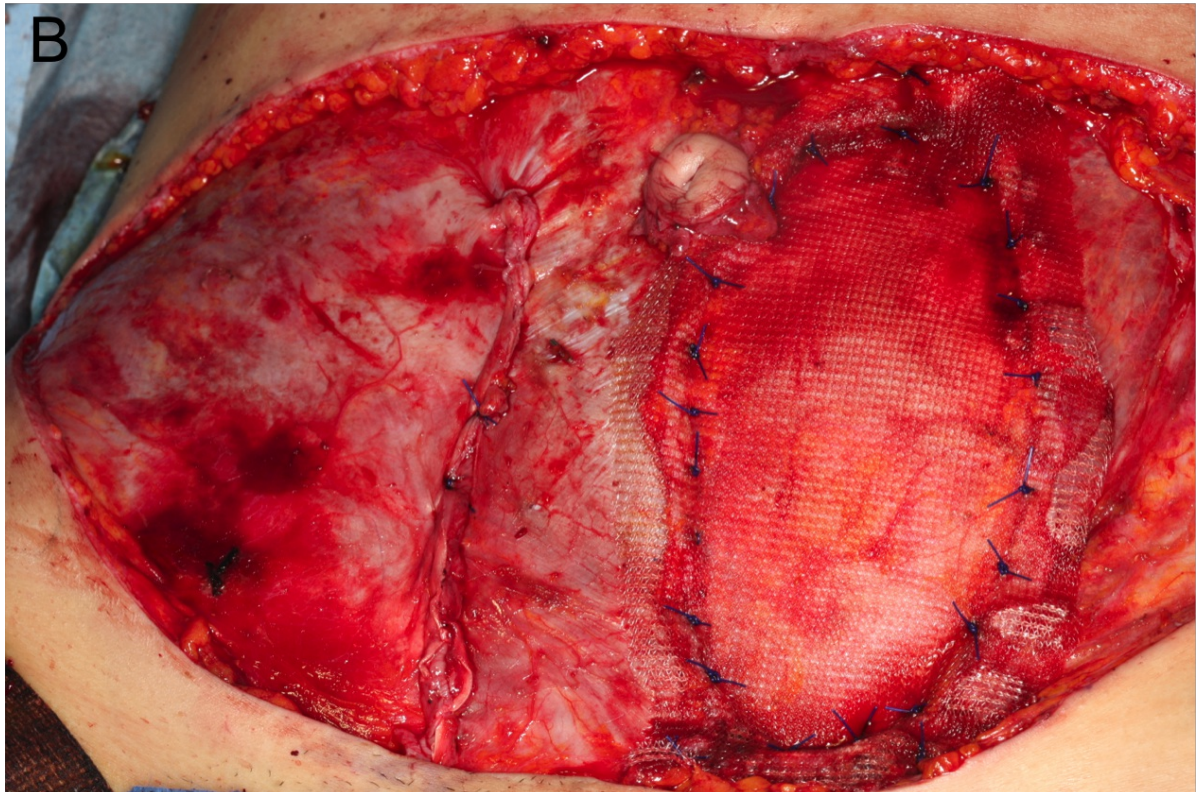
a pedicle 8 to 10 cm long. Strengthening of the abdominal wall was achieved with the use of a synthetic non-absorbable mesh (2/0 nylon suture) to repair the muscle defect. (Figure 2a)



**Figure 2. Abdominal wall reconstruction. (A)** RA muscle repair with propylene mesh in the same patient in figure 1A undergoing a left VRAM flap.

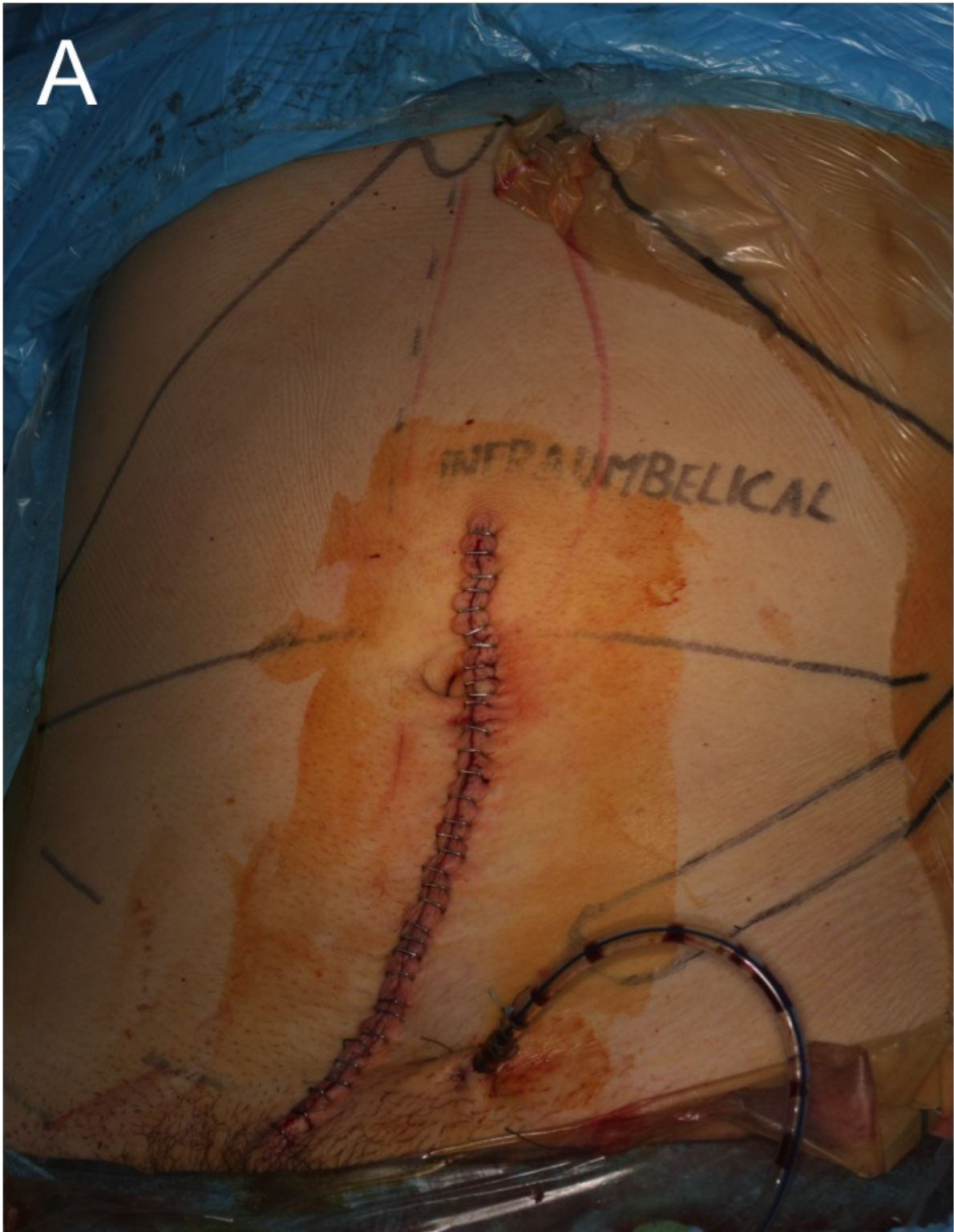

When a DIEAP flap was planned, the anterior rectus sheet was opened at the selected perforator that was traced through the muscle, splitting the RA muscle fibers and preserving the intercostal nerves. The superficial inferior epigastric vein (SIEV) was always included as an outlet for venous congestion. A tension-free coaptation of the rectus sheet was achieved with a running large caliber non-absorbable suture. (Figure 2b)



**Figure 2. Abdominal wall reconstruction. (B)** Direct closure (2/0 non-absorbable) of the anterior sheet (right side) and propylene mesh repair of RA muscle defect (left side) after the simultaneous elevation of a right DIEAP and a left VRAM infraumbilical flap respectively.

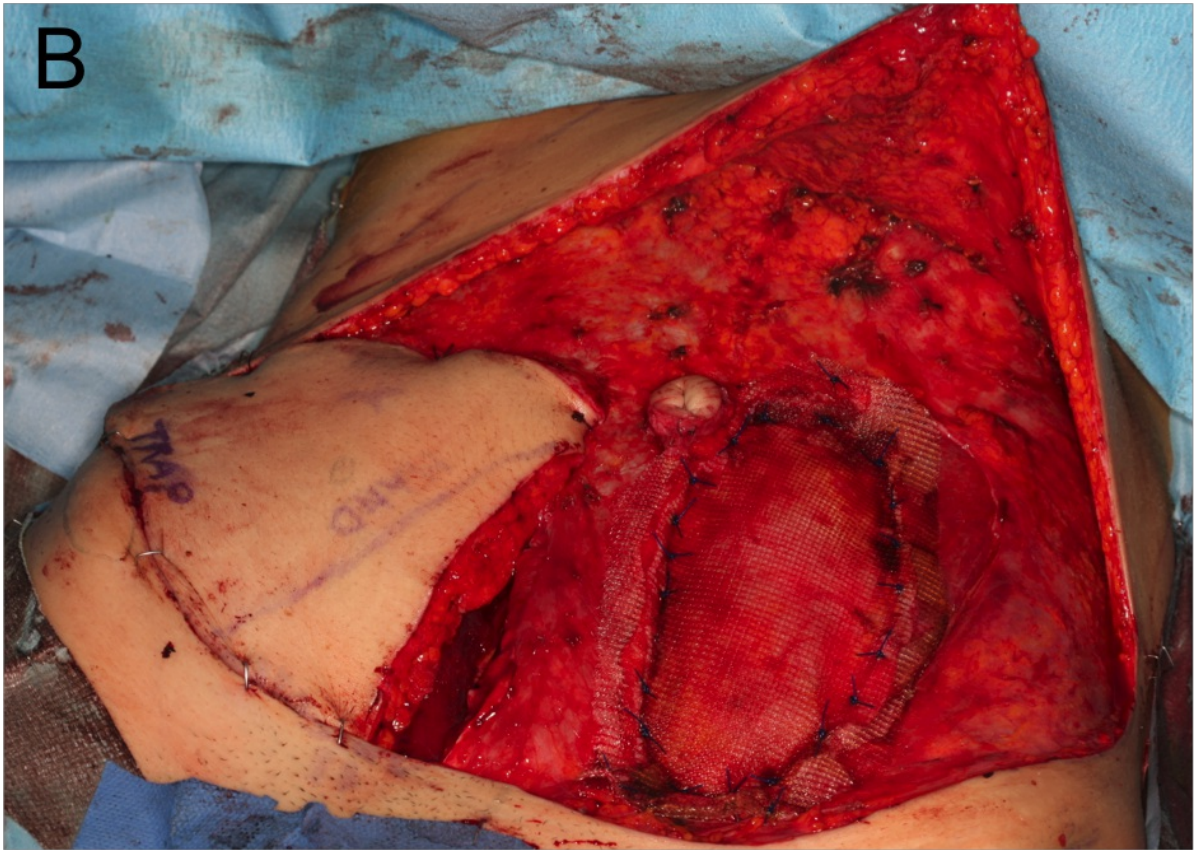
Direct skin closure resulting in a linear vertical scar was achieved in all cases of unilateral harvest of flaps. (Figure 3a)



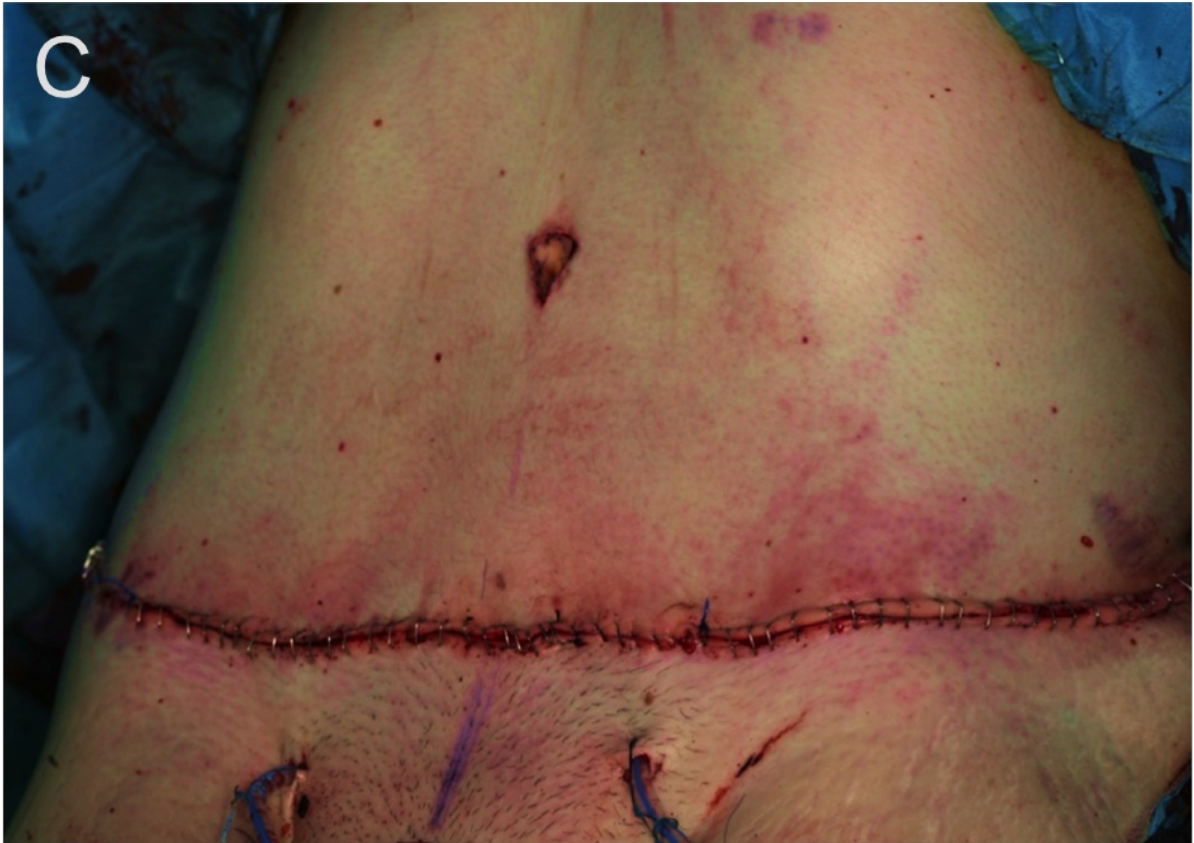**Figure 3. Abdominal wound closure.** (A) The final scar that follows the unilateral harvest of VRAM/DIEAP flaps normally extends 1-2 cm above the umbilicus, as the result of direct skin closure.

Standard abdominoplasty with umbilical repositioning was performed in all cases of bilateral harvest of flaps after surgical drain insertion. (Figure 3b-3c)





**Figure 3. Abdominal wound closure. (B)** Bilateral infraumbilical flap elevation with mesh closure of RA defect after VRAM flap inset (left side) and DIEAP flap still on site (right side). Abdominal wall superficial layers (skin, fat, and muscles) are carefully dissected for abdominoplasty preparation.



**Figure 3. Abdominal wound closure.** (C) Final result after standard abdominoplasty and umbilical repositioning in the same patient.

## 2.5. Postoperative follow-up

After surgery, postoperative systemic complications, donor-site complications, need for abdominal re-operative surgery were recorded; free flap viability at the recipient site, need for additional salvage surgery in case of flap failure, and length of hospital stay were collected.

The histopathological report of the tissue specimens was reviewed, and the ultimate cancer diagnosis was classified according to the current TNM staging system.

All cancer patients received a consultation at the institutional multidisciplinary head and neck oncology board to consider further indications for adjuvant treatments and oncological follow-up.

At discharge, outpatient clinical follow-up was started every 3 months over the first year, every 6 months over the second year, and annually thereafter. Data on cancer-free disease survival, abdominal wall integrity, and abdominal wound repair were retrieved from the patient follow-up charts and digital pictures from the local database of the recruiting centers. Pain intensity at the donor site using a visual analogue scale (VAS) ranging from 0 (no pain) to 10 (unbearable pain) was recorded at discharge and at each follow-up visit.



At each visit, all patients were asked about any physical impairment related to abdominal wall weakness, and the donor site was inspected for any sign of anterior wall laxity and unsightly scars.

## 2.6. Study outcome

The main outcome of the study was the occurrence of donor site complications in short (within 1-month), medium (6-month), and long-term follow-up (up to the latest follow-up). Complications were categorized as minor or major.

Abdominal bulging and hernia formation were defined as major complications, regardless of the need for reparative surgery. Physical examination and abdominal ultrasonography were performed to confirm the diagnosis.

Complicated abdominal wound healing with surgical site infection/skin dehiscence was classified as minor when successfully managed with medications or local flap transposition. Cases requiring major reparative surgical interventions or repeated additional surgical procedures to correct abdominal skin unfavorable outcomes were considered major complications.

Abdominal wall firmness was determined by the absence of muscle hypotonia with complete resumption of daily activities.

The final appearance of the abdominal wall was inspected for the presence of an overall symmetrical abdominal contour and stable infraumbilical scar healing without unfavorable skin remnants. A scoring system graded 1-3 was used to define poor, satisfactory, and good results, respectively.

Different physicians (G.B., G.S., P.F., T.L.) from those who had performed surgery evaluated donor site functional and aesthetic results at each scheduled postoperative visit and recorded them on an individual case report form.

The recipient site was also inspected for flap failure that was categorized as complete in presence of total flap necrosis, and partial in cases of incomplete skin loss (variable extent).

## 2.7. Statistical analysis

Continuous variables are reported as median (50th percentile) and interquartile range (IQR, 25th and 75th percentiles). Discrete variables are reported as the number and proportion of subjects with the characteristic of interest. Statistical analysis was performed using Stata 16.1 (Stata Corporation, College Station, TX, USA).

# 3. Results

## 3.1. Patients

Between January 2008-January 2020, 25 consecutive patients underwent reconstruction of soft tissue defects of the cervicofacial region with free flaps harvested from the lower abdomen. The baseline features of the study population are given in Table 1.

The patients were 11 men and 14 women with a median (IQR) age of 56 (47; 65) years. The most frequent diagnosis was oral squamous cell carcinoma (n= 21, 84%), of these 6 patients had recurrent malignancies following surgery and radiation treatment at primary cancer diagnosis. Isolated tongue defects (total glossectomy) were treated in 8 cases, whereas the remaining 17 patients needed reconstruction of composite hard and soft tissue defects in the cervicofacial region.

A total of 35 abdominal infraumbilical free flaps were performed and 10 patients underwent bilateral flap harvest. The average soft tissue defect size was 11x8 cm (maximum defect size 12x8 cm) after total glossectomy, and 18x9 cm (maximum defect size 34x14 cm) in patients who underwent resection of cervico-facial skin respectively. The pedicle length, measured as the distance between the origin from the iliac vessels and the entry point of the pedicle in the soft-tissue flap ranged between 10 and 18cm, depending on the type of flap (VRAM vs DIEAP).

Flap necrosis occurred in 4 cases (1 VRAM, 3 DIEAP) that required salvage microsurgical reconstructive procedures. In four cases of bilateral DIEAP elevation, partial skin necrosis (10 to 40% volume in one case) required additional tissue transfer (2 free flaps, 1 temporalis flap) in three patients. In the remaining patient secondary healing was achieved.

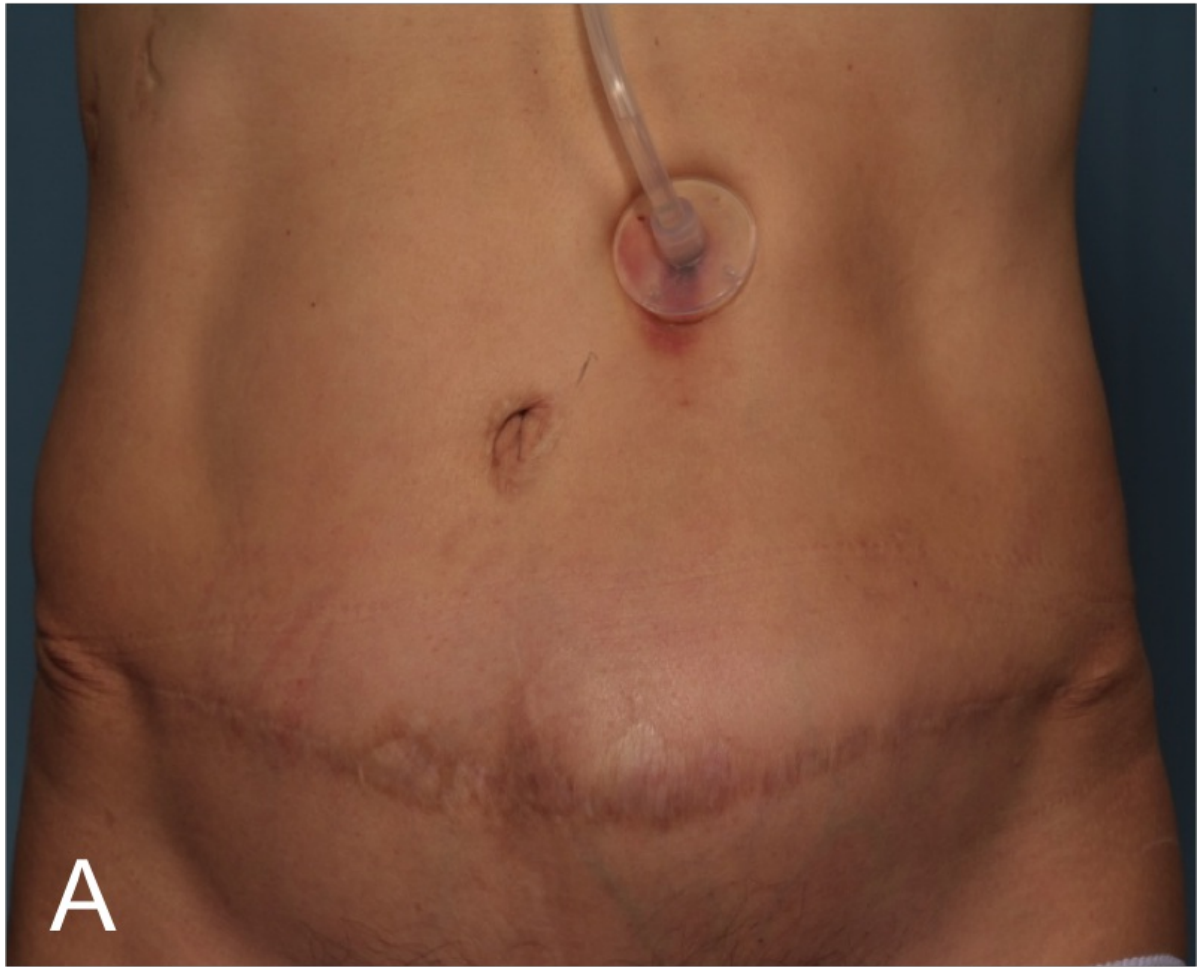The median hospital stay was 32 days (IQR 26; 46), and the median follow-up was 12 months (IQR 6; 27). One patient died 1 month after surgery for severe systemic complication following acute respiratory distress, and seven more patients died of cancer-related disease during the follow-up. The 1-year overall survival rate of the study population was 52%. (Table 2)

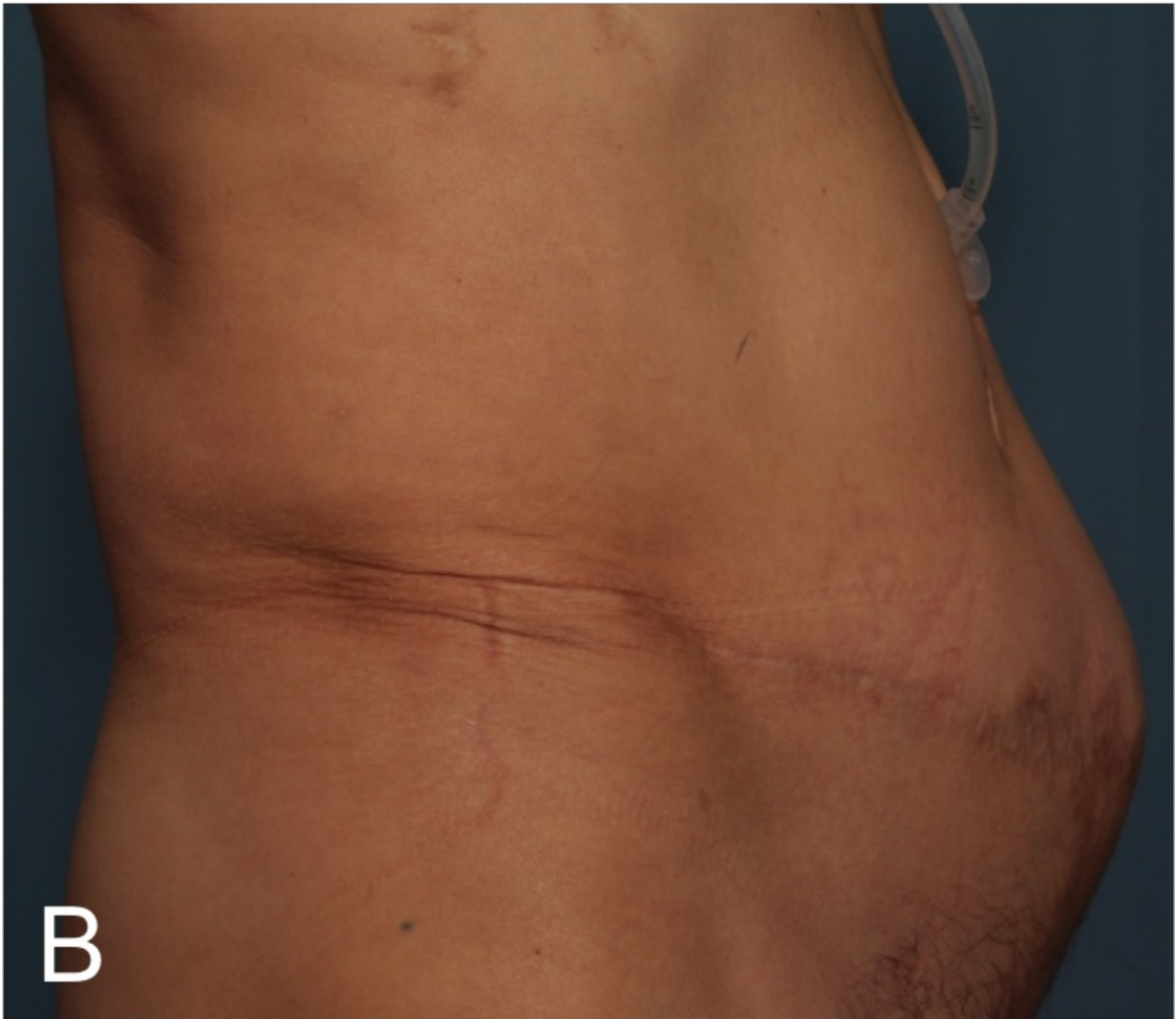
### 3.2. Perioperative donor site complications

Partial necrosis of the repositioned umbilicus occurred in one patient, and superficial abdominal seroma formation in another one that healed spontaneously in both cases. Two patients experienced marginal abdominal skin necrosis. In one case surgical correction of the necrosis required a local rotation flap, while in the other case healed with mechanical debridement of non-viable tissue and topical therapies. The median (IQR) post-operative pain score recorded by VAS at the donor site was 0 (0; 1).

### 3.3. Postoperative donor site complications

The overall rate of postoperative abdominal complications (major/minor) was 11%. Complete resumption of daily activities was achieved within 1 month in all patients. Neither hernia nor abdominal wall weakness was observed for the duration of the follow-up, except for one patient who developed abdominal bulging 1 year after surgery, following a two-sided flap harvest (combined VRAM/DIEAP flaps). The latter complication did not require surgical repair and remained stable over time. (Figure 4a-4b)

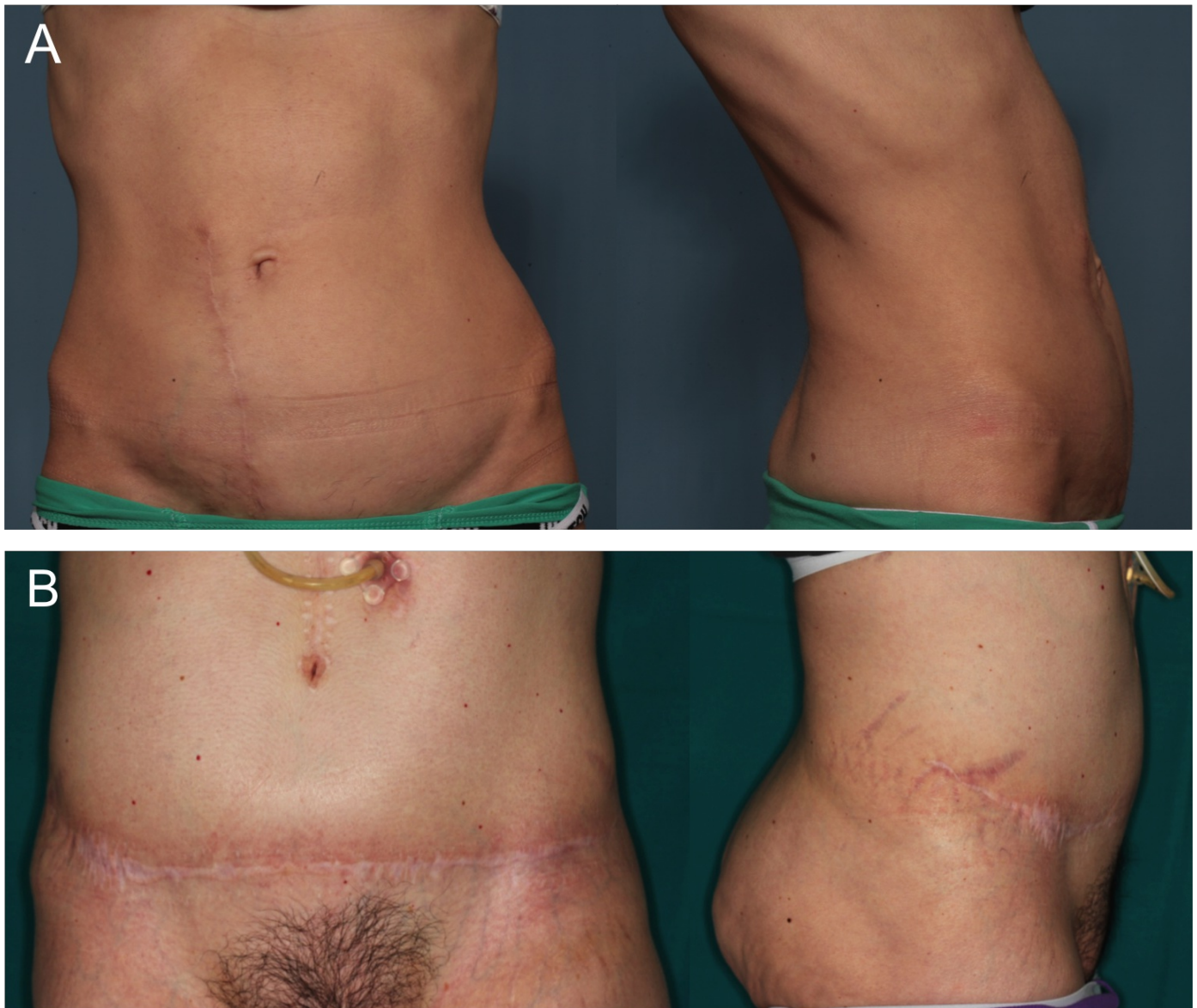




**Figure 4. Abdominal bulge.** Frontal (A) and lateral view (B) of the patient who developed at 1-year abdominal rectus diastasis with bulging after the simultaneous harvest of a right DIEAP and a left VRAM. Despite the unfavorable abdominal result, the condition was not associated with pain or musculoskeletal and urogynecological problems for the entire duration of the follow-up and did not require surgical repair.

The final appearance of the abdominal wall was judged good (grade 3) in all but two patients. (Figure 5a-5b)





**Figure 5. Donor site long-term follow-up. (Panel A)** Frontal and lateral view of the abdomen of a woman who underwent a right infraumbilical VRAM harvest. The abdominal wall contour is acceptable as compared with the contralateral untreated side with the skin scar entirely located in the lower abdomen. **(Panel B)** Abdominoplasty long-term result after the harvest of a bilateral infraumbilical DIEAP flap in frontal and lateral view.

#### 4. Discussion

The results of the present study demonstrate the safety of the infraumbilical abdominal region following the harvest of composite soft-tissue flaps, both in terms of functional and cosmetic results. The harvest of bilateral flaps with the inclusion of a segment of RA muscle above the arcuate line does not endanger the strength of the abdominal wall, provided that accurate reconstruction of the missing layers is accomplished.

The main study limitation is the retrospective nature of the data collected. However, consecutive cases were enrolled with different defects and flap sizes accordingly.

Another potential limitation is the unavailability of postoperative instrumental assessment of abdominal muscle integrity

and dynamics. This is, however, largely due to the fact that we enrolled mostly advanced-stage cancer patients (primary or recurrent malignancy) who were recommended for adjuvant therapies and/or long-term supportive care after surgery.

The reconstruction of head and neck defects is often challenging for the functional implications of the three-dimensional composite framework of the cervicofacial area and usually requires a great amount of donor tissues.

Abdominal perforator flaps based on DIEA vascular territory have become an important donor source of a large volume of vascularized tissues that can be tailored to the defective recipient site in the cervicofacial area.<sup>[1][3][14][15]</sup>

TRAM/VRAM flap is commonly used to reconstruct subtotal/total glossectomy defects providing highly versatile tissues supporting the restoration of bulky defects.<sup>[16][17][18]</sup> Instead, DIEAP adipo-cutaneous flaps can be used to cover large cutaneous defects of the cheek and the neck.<sup>[2][7][19][20]</sup>

The standard design of the abdominal perforator flaps (TRAM/VRAM and DIEAP) encompasses the upper and lower aspect of the abdomen in the periumbilical area, thus including the dominant perforators to increase flap viability.<sup>[6][21]</sup>

Location of the most suitable perforator can be done with handheld doppler, colour doppler (duplex) ultrasonography, computed tomography angiography (CTA), and magnetic resonance angiography (MRA).<sup>[11]</sup>

Despite limited data, preoperative CTA seems to perform better than ultrasound with its increasing use for perforator detection.<sup>[10]</sup> For this reason, starting in 2015, we included preoperative CTA in our algorithm of perforator selection.

The skin component of the VRAM/TRAM flap can be oriented vertically, obliquely, or transversely to include large tissue volumes, comprising the RA muscle, for reconstructive purposes.

Nevertheless, the traditional paraumbilical flap is usually associated with poor aesthetic outcomes, resulting from a scar that exceeds the umbilicus in the upper abdomen.<sup>[7]</sup>

In our study, the infraumbilical harvest of abdominal perforator flaps showed a number of advantages over the standard technique. First, in the case of large volume defects, simultaneous harvest of bilateral adipo-cutaneous and muscle-containing flaps was feasible, without impacting the abdominal wall firmness. Closure by standard abdominoplasty could be achieved in all patients undergoing bilateral flap harvest.

Interestingly, the harvest of a RA muscle flap component (DIEAP chimeric flap or VRAM flap) from the infraumbilical region without exceeding the arcuate line provided enough tissue length and width for successful restoration of mylohyoid muscle-like structure and prevented gravity sagging of the oral floor in all cases of total glossectomy defect. Secondly, in case of flap failure following the unilateral harvest of an infraumbilical flap, the contralateral side of the abdomen was readily available for the harvest of a new flap with the same features. The abdominal skin scar of the failed flap could be resected and donor site closure achieved with standard abdominoplasty technique.

On the contrary, violation of both the upper and lower abdominal skin when using standard abdominal flap design precludes the use of the contralateral side in case of flap failure.

Third, the infraumbilical approach, in both transverse and vertical design (unilateral or bilateral flaps), allowed for a more concealable scar located in the inferior aspect of the abdomen.

Fourth, the infraumbilical flap harvest did not preclude the insertion of a gastrostomy tube, even though tummy tuck donor site closure was accomplished.

Lastly, the pedicle length was appropriate in all cases for the reconstructive purpose, including secondary reconstruction of large soft-tissue defects in vessel-depleted neck due to tumor extirpation and radiotherapy, even though the dominant perforator was selected beneath the umbilicus.

In our study, the rate of postoperative abdominal complications is in line with other studies reporting the donor site morbidity of standard periumbilical flap harvest (range 3.5-20%),<sup>[22][23][24]</sup> showing that the infraumbilical harvest of free flaps with a RA muscle component is at least as safe as the standard approach. Obesity seems to increase the risk of both flap-related and donor-site complications in the western population following breast reconstruction using cutaneous and myocutaneous flaps.<sup>[25]</sup> This could be of some concern also when choosing the abdominal wall as the free flap donor region in head and neck cancer patients, especially females. Despite we did not record the individual BMI of the study population, we cannot confirm any obesity-associated donor site complications. In fact, the only long-term donor site complication (abdominal bulging) occurred in a slim female cancer patient and was caused by tearing of the anterior rectus sheet following DIEAP harvest. Instead, partial/total necrosis of the flap occurred in 2 of the 3 obese patients included in the study cohort. The link between obesity and failure of adipo-cutaneous abdominal flaps was not the aim of the present study, but further attention should be paid in future studies to address this possible association.

Of importance, the pedicle length of the infraumbilical flaps was appropriate in all cases for the reconstructive purpose, including secondary reconstruction of large soft-tissue defects in vessel-depleted neck due to tumor extirpation and radiotherapy.

## 5. Conclusions

In conclusion, our study supports the hypothesis that the infraumbilical area is a safe and reliable donor region of free flaps for the reconstruction of composite defects of the head and neck.

Placing the abdominal flaps entirely in the lower abdomen does not impact the abdominal wall firmness and provides satisfactory functional and morphological results at the donor site.

### Abbreviations:

VRAM: Vertical Rectus Abdominis myocutaneous flap

TRAM: Transverse Rectus Abdominis myocutaneous flap

DIEAP: Deep Inferior Epigastric Artery Perforator flap

ASIS: anterior superior iliac spines

SIEV: Superficial Inferior Epigastric vein

**Ethical Statement:** The study was conducted in accordance with the Declaration of Helsinki. Institutional ethical review and approval were waived due to the retrospective design of the study and not involving any identifying information of any patients during medical records review.

**Data Availability Statement:** The significant data are specified in the paper. The other data not presented in this study are available on request from the corresponding author. The data are not publicly available due to privacy restrictions.

**Conflicts of Interest:** The authors declare no conflict of interest.

**Authors' Contributions:** All authors have read and agreed to the edited version of the manuscript and take responsibility for the integrity of the data and the accuracy of the data analysis. Conceptualization, G.B., A.B., and S.V.; Methodology, G.B., A.B., and G.S.; Validation, G.B. and A.B.; Investigation, P.F., L.T., and E.A.; Formal analysis, G.B. and P.F.; Resources: G.B., A.B., and S.V.; Data curation, P.F., L.T., and E.A.; Writing—original draft preparation, G.B.; Writing—review and editing, A.B. and E.A.; Supervision, G.S. and S.V.

**Funding:** This research did not receive any specific grant from funding agencies in the public, commercial, or not-for-profit sectors.

**Informed Consent Statement:** All patients involved in the study gave their written consent for participation.

## References

1. <sup>a, b</sup>Neligan PC. Head and neck reconstruction. *Plast Reconstr Surg.* 2013;131(2):260-9. doi:10.1097/PRS.0b013e3182778938.
2. <sup>a, b</sup>Beausang ES, McKay D, Brown DH, et al. Deep inferior epigastric artery perforator flaps in head and neck reconstruction. *Ann Plast Surg.* 2003;51(6):561–3. doi:10.1097/01.sap.0000096447.93223.bf.
3. <sup>a, b</sup>Frederick JW, Sweeny L, Carroll WR, Peters GE, et al. Outcomes in head and neck reconstruction by surgical site and donor site. *Laryngoscope.* 2013;123(7):1612–7. doi:10.1002/lary.23775.
4. <sup>a, b</sup>Boyd JB, Taylor GI, Corlett R. The vascular territories of the superior epigastric and the deep inferior epigastric systems. *Plast Reconstr Surg.* 1984;73(1):1-16. doi:10.1097/00006534-198401000-00001.
5. <sup>a</sup>Blondeel PN. One hundred free DIEP flap breast reconstructions: a personal experience. *Br J Plast Surg.* 1999;52(2):104-11. doi:10.1054/bjps.1998.3033.
6. <sup>a, b</sup>Rozen WM, Ashton MW, Taylor GI. Reviewing the vascular supply of the anterior abdominal wall: redefining



- anatomy for increasingly refined surgery. *Clinical Anatomy*. 2008;21(2):89–98. doi:10.1002/ca.20585.
7. <sup>a, b, c, d</sup>Masià J, Sommaro M, Cervelli D, Vega C, et al. Extended deep inferior epigastric artery perforator flap for head and neck reconstruction: a clinical experience with 100 patients. *Head Neck*. 2011;33(9):1328–34. doi:10.1002/hed.21628.
  8. <sup>^</sup>Kotti B. Optimizing the pedicled rectus abdominis flap: revised designs and vascular classification for safer procedures. *Aesthetic Plast Surg*. 2014;38(2):387-94. doi:10.1007/s00266-014-0273-y.
  9. <sup>^</sup>Wade RG, Watford J, Wormald JCR, et al. Perforator mapping reduces the operative time of DIEP flap breast reconstruction: A systematic review and meta-analysis of preoperative ultrasound, computed tomography and magnetic resonance angiography. *J Plast Reconstr Aesthet Surg*. 2018;71(4):468-77. doi:10.1016/j.bjps.2017.12.012.
  10. <sup>a, b</sup>Haddock NT, Dumestre DO, Teotia SS. Efficiency in DIEP flap breast reconstruction: the real benefit of computed tomographic angiography imaging. *Plast Reconstr Surg*. 2020;146(4):719-23. doi:10.1097/PRS.00000000000007148.
  11. <sup>a, b</sup>Kiely J, Kumar M, Wade RG. The accuracy of different modalities of perforator mapping for unilateral DIEP flap breast reconstruction: A systematic review and meta-analysis. *J Plast Reconstr Aesthet Surg*. 2021;74(5):945-56. doi:10.1016/j.bjps.2020.12.005.
  12. <sup>^</sup>Mahajan AL, Waes CV, D'Arpa S, et al. Bipedicled DIEAP flaps for reconstruction of limb soft tissue defects in male patients. *J Plast Reconstr Aesthet Surg*. 2016;69(7):920-7. doi:10.1016/j.bjps.2016.03.015.
  13. <sup>^</sup>Blondeel PN, Van Landuyt K, Monstrey S. Surgical-technical aspects of the free DIEP flap for breast reconstruction. *Oper Tech Plast Reconstr Surg*. 1999;6(1):27-37. doi:10.1016/S1071-0949(99)80017-1.
  14. <sup>^</sup>Futran ND, Mendez E. Developments in reconstruction of mid-face and maxilla. *Lancet Oncol*. 2006;7(3):249-58. doi:10.1016/S1470-2045(06)70616-7.
  15. <sup>^</sup>Kang SY, Spector ME, Chepeha DB. Perforator based rectus free tissue transfer for head and neck reconstruction: New reconstructive advantages from an old friend. *Oral Oncol*. 2017;74: 163-70. doi:10.1016/j.oraloncology.2017.06.029.
  16. <sup>^</sup>Haddock NT, DeLacure MD, Saadeh PB. Functional reconstruction of glossectomy defects: The vertical rectus abdominus myocutaneous neotongue. *J Reconstr Microsurg*. 2008;24(5):343–50. doi:10.1055/s-2008-1080537.
  17. <sup>^</sup>Lopez–Arcas JM, Arias J, Moran MJ, et al. The deep inferior epigastric artery perforator (DIEAP) flap for total glossectomy reconstruction. *J Oral Maxillofac Surg*. 2012;70(3):740–7. doi:10.1016/j.joms.2011.02.098.
  18. <sup>^</sup>Cappiello J, Piazza C, Taglietti V, et al. Deep inferior epigastric artery perforated rectus abdominis free flap for head and neck reconstruction. *Eur Arch Otorhinolaryngol*. 2012;269(4): 1219-24. doi:10.1007/s00405-011-1749-x.
  19. <sup>^</sup>Woodworth BA, Gillespie MB, Day T, et al. Muscle-sparing abdominal free flaps in head and neck reconstruction. *Head Neck*. 2006;28(9):802-7. doi:10.1002/hed.20393.
  20. <sup>^</sup>Zhang B, Li D-Z, Xu Z-G, et al. Deep inferior epigastric artery perforator free flaps in head and neck reconstruction. *Oral Oncol*. 2009;45(2):116-20. doi:10.1016/j.oraloncology.2008.04.005.
  21. <sup>^</sup>Patel NP, Matros E, Cordeiro PG. The use of the multi-island vertical rectus abdominis myocutaneous flap in head and neck reconstruction. *Ann Plast Surg*. 2012;69(4):403-7. doi:10.1097/ SAP.0b013e3182400ed8.
  22. <sup>^</sup>Derrick CW, Charles YT, Dam JA, et al. Inclusion of mesh in donor-site repair of free TRAM and muscle-sparing free TRAM flaps yields rates of abdominal complications comparable to those of DIEAP flap reconstruction. *Plast Reconstr*

*Surg.* 2010;126(2):367-74. doi:10.1097/PRS.0b013e3181de1b7e.

23. <sup>^</sup>Man LX, Selber C, Serletti JM. Abdominal wall following free TRAM or DIEP flap reconstruction: A meta-analysis and critical review. *Plast Reconstr Sur.* 2009;124(3):752-64. doi:10.1097/PRS.0b013e31818b7533.
24. <sup>^</sup>Rietjens M, De Lorenzi F, Andrea M, et al. Technique for minimizing donor-site morbidity after pedicled TRAM-flap breast reconstruction: outcomes by a single surgeon's experience. *Plast Reconstr Surg Glob Open.* 2015;3(8):e476. doi:10.1097/GOX.0000000000000451.
25. <sup>^</sup>Kyeong-Tae L, Goo-Hyun M. Effects of obesity on postoperative complications after breast reconstruction using free muscle-sparing Transverse Rectus Abdominis myocutaneous, Deep Inferior Epigastric perforator, and Superficial Inferior Epigastric artery flap: A systematic review and meta-analysis. *Ann Plast Surg.* 2016;76(5):576-84. doi:10.1097/SAP.0000000000000400.