

[Open Peer Review on Qeios](#)

# Diffuse Neurocysticercosis in a Survivor of Tuberculosis

Prashant Ahlawat<sup>1</sup>, Prateek Upadhyay<sup>1</sup>, Tulika Garg<sup>1</sup>

<sup>1</sup> Government Medical College and Hospital

**Funding:** No specific funding was received for this work.

**Potential competing interests:** No potential competing interests to declare.

## Abstract

Neurocysticercosis (NCC) is a prevalent parasitic infection of the central nervous system (CNS) caused by *Taenia solium* larvae. It is commonly found in developing countries with a high incidence of both NCC and CNS tuberculosis. In cases where patients have a history of pulmonary tuberculosis, the lesions arising from NCC can be misdiagnosed as tuberculomas. Furthermore, when papilledema (a sign of raised intracranial pressure) is present, CNS tuberculosis is often considered a more probable diagnosis compared to NCC. While NCC is common, disseminated cysticercosis is rare. In this article, we present a case of diffuse neurocysticercosis and discuss relevant management approaches.

**Prashant Ahlawat, MD**, *Department of General Medicine, Government Medical College & Hospital, Chandigarh, Chandigarh, IND (Correspondence at [ahlawatprashant97@gmail.com](mailto:ahlawatprashant97@gmail.com))*

**Prateek Upadhyay, MD**, *Department of Anaesthesia and Intensive Care, Government Medical College & Hospital, Chandigarh, Chandigarh, IND*

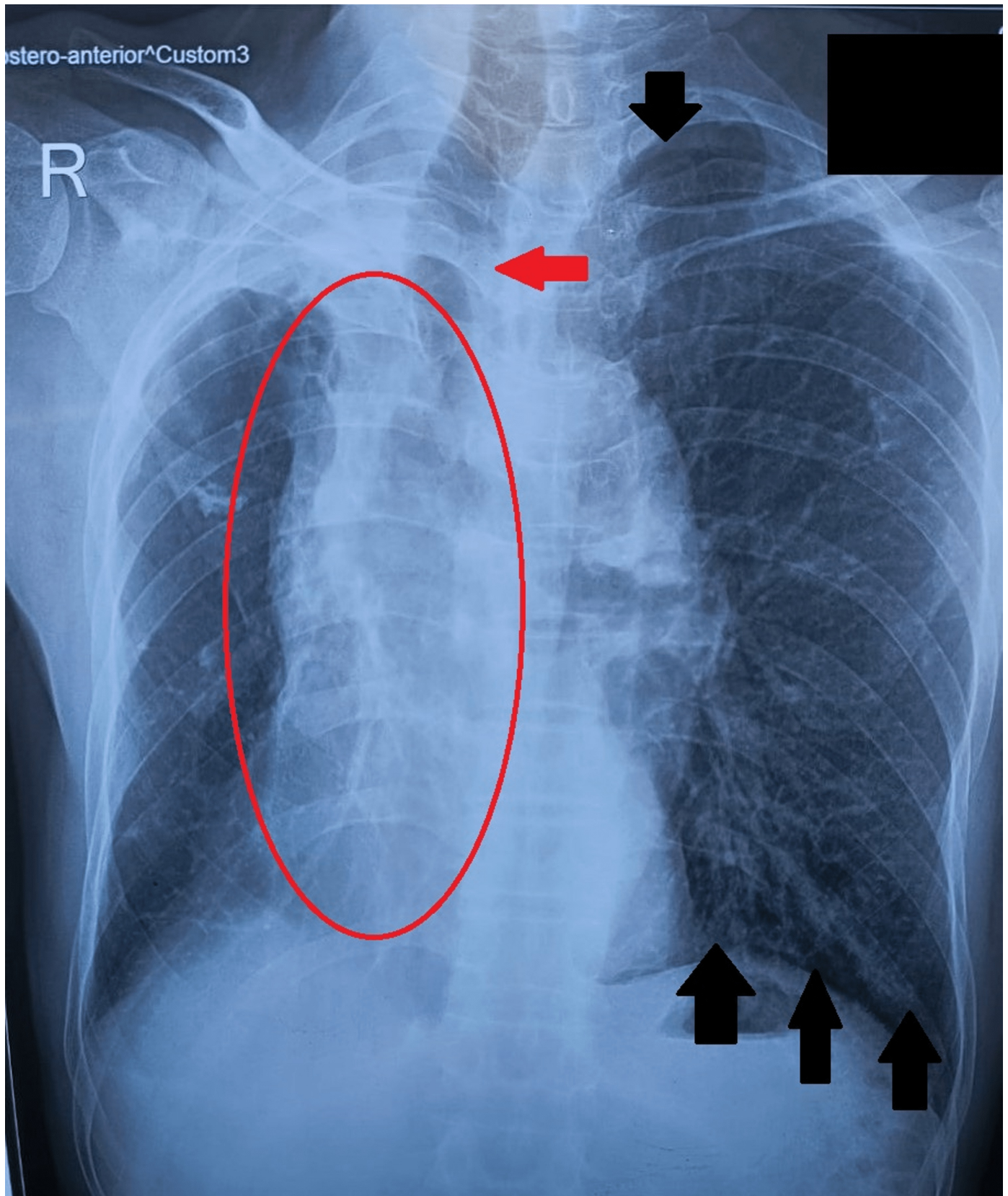
**Tulika Garg, MBBS**, *Department of General Medicine, Government Medical College & Hospital, Chandigarh, Chandigarh, IND*

## Introduction

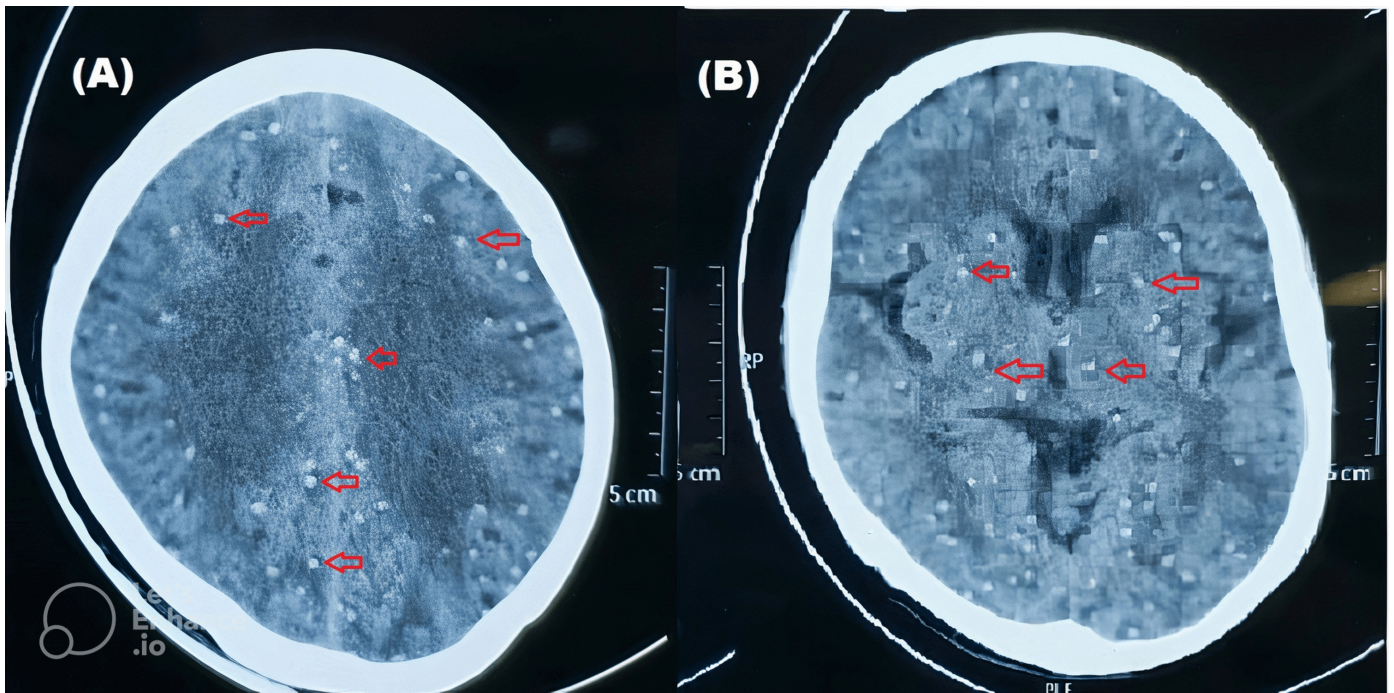
Neurocysticercosis (NCC) is the most prevalent parasitic infestation of the central nervous system worldwide, caused by *Taenia solium* larvae. It is a leading cause of acquired epilepsy in developing countries [1]. NCC presents with a diverse range of clinical symptoms, making it challenging to accurately diagnose and stage. The disease is pleomorphic, complicated by various interconnected factors, such as the size and number of cysticerci, their developmental stage, and their localization within the brain. Clinical manifestations of NCC commonly include headaches, seizures, and localized neurological impairments. Involvement of the eyes, subcutaneous tissues, and brain parenchyma is also frequently observed [2].

## Case Presentation

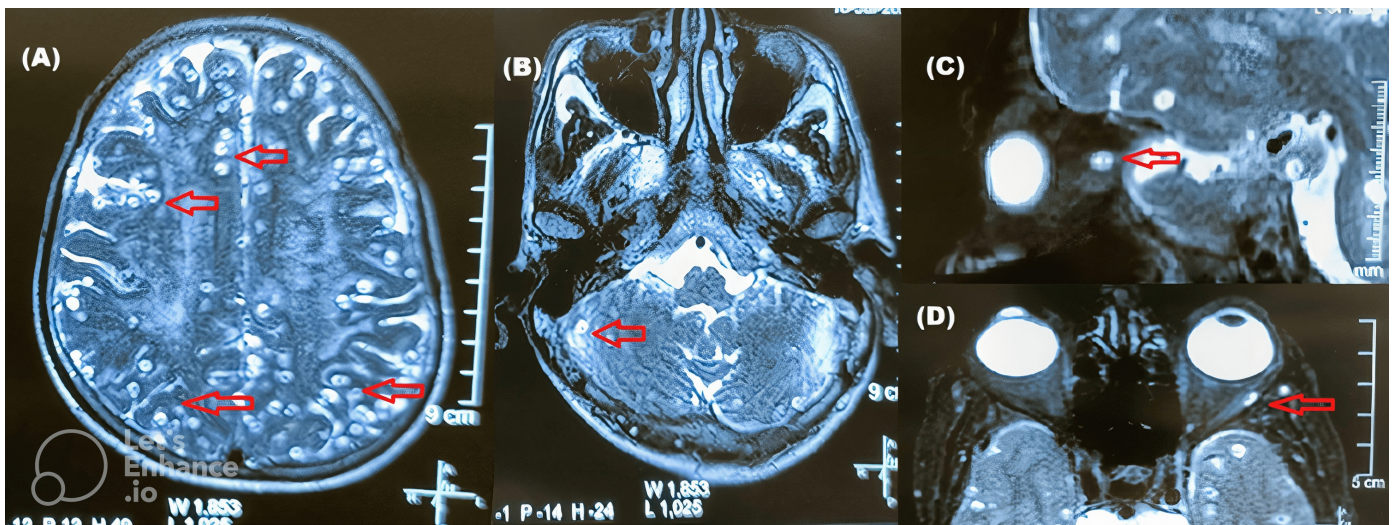
A 60-year-old male presented with abnormal body movements lasting for two minutes, involving the entire body and accompanied by up-rolling of the eyes, loss of consciousness, and urinary incontinence. Consciousness was regained after approximately two hours, and the patient denied experiencing headaches or blurry vision. Twenty-five years prior, the patient had received treatment for pulmonary tuberculosis for about six to eight months. A chest X-ray revealed lesions frequently encountered as sequelae of treated pulmonary tuberculosis (Figure 1). Non-contrast computed tomography (NCCT) of the head showed a starry sky appearance (Figure 2). Cerebrospinal fluid examination revealed an acellular profile, with raised total protein (126 mg/dl) and no adenosine deaminase. Other investigations, including complete blood counts, renal function tests, and liver function tests, were within normal limits. Upon further inquiry into personal history, the patient reported a history of pork consumption during social occasions. Magnetic resonance imaging (MRI) of the brain, spine, and orbit revealed neurocysticercosis of the CNS in various stages of development (vesicular, colloid vesicular, and nodular calcified stages), along with myocysticercosis. T2 hyperintense lesions with suppression on Fluid-Attenuated Inversion Recovery (FLAIR) images were observed in the conus medullaris, right temporalis and masseter muscles, bilateral parotid glands, and tongue muscles (Figure 3). The patient was successfully managed with antiepileptics and steroids and subsequently discharged.



**Figure 1.** Chest X-ray on presentation suggestive of old treated pulmonary tuberculosis with rightwards shifting of trachea (red arrow), right lung volume loss (encircled), and compensatory hyper-inflation of left lung (black arrows).



**Figure 2.** Non Contrast Computed Tomography (NCCT) of head (A) and (B) are different level of CT cuts showing multiple small calcifications (marked) resembling starry sky appearance.



**Figure 3.** Magnetic Resonance Image (MRI) scan of brain and orbits

(A) and (B) showing areas of cystic encephalomalacia (arrows) with surrounding gliosis and sulcal widening in bilateral basifrontal region (including cerebellum) and right anterior temporal lobe. (C) and (D) Orbital involvement in neurocysticercosis.

## Discussion

In regions where neurocysticercosis is endemic, particularly in Asia, Latin America, and Africa, it is the most common cause of adult-onset epilepsy [3]. The clinical course of NCC ranges from asymptomatic to fatal disease and can involve the parenchyma, intraventricular system, or subarachnoid space within the CNS. Although less common, ocular and spinal involvement can also occur, leading to pleomorphic clinical symptoms based on the location, quantity, and stage of

the cysts during presentation. Epilepsy is more frequently encountered in patients with parenchymal NCC, although it can also occur in cases with cysts in the cerebral sulci.

Seizures related to cysticercosis often occur when a dying cyst triggers an inflammatory response. Approximately 50 to 70 percent of patients with epilepsy experience recurrent seizures, which may be the only symptom of the disease in many cases [4]. Although seizures are the most typical clinical symptom of parenchymal NCC, focal neurological symptoms have also been noted, typically correlating with the quantity, size, and location of the parasites in patients with parenchymal disease. Intracranial hypertension, termed cysticercotic encephalitis, can develop in people with parenchymal NCC [5]. Management of this condition involves the use of mannitol and corticosteroids to reduce intracranial pressure and inflammation. In some cases, a decompressive temporal craniotomy may be necessary. However, antiparasitic medications are not recommended in cases of cysticercotic encephalitis as they may exacerbate swelling and inflammation.

A small percentage of NCC cases (less than five percent) involve the spinal cord [6]. Intramedullary involvement is more common than intramedullary involvement. Intramedullary cysts are most frequently found in the thoracic spine and typically result in a slow onset of myelopathy, similar to cases with intramedullary tumors [7]. Leptomeningeal NCC and extramedullary cysts usually result from subarachnoid infection spreading from the basilar cisterns. Cysts may be isolated or clustered together, extending along the entire length of the spinal canal. The stage of parasite development affects the neuroimaging of parenchymal NCC. During the vesicular stage, the cysticerci present as cystic lesions within the brain parenchyma, characterized by a thick, hypointense wall with noticeable perilesional edema on MRI [8]. Calcified cysticerci are small hyper-dense nodules seen on CT scans without enhancement after the administration of contrast. MRI is generally unable to reveal these lesions unless they are accompanied by perilesional edema and contrast enhancement. Hydrocephalus is the most frequent CT finding in subarachnoid NCC, a typical side effect of fibrous arachnoiditis [7]. MRI is the most effective method to visualize leptomeningeal enhancement at the base of the brain [9]. Neuroimaging appearances of cerebrovascular issues are generally difficult to distinguish from cerebral infarcts or other causes. Ventricular cysts appear as cystic lesions on CT scans, but MRI is better suited to visualize them as their signal characteristics are distinct from cerebrospinal fluid when using FLAIR techniques. Ventricular cysts may move inside the ventricular chambers in response to head movements, a phenomenon better seen with MRI than with CT (the "ventricular migration sign") [10].

Intramedullary cysts or pseudo-reticular forms within the spinal canal may be observed on CT scans of individuals with spinal NCC (leptomeningeal cysts). On MRI, intramedullary cysticerci present as ring-enhancing lesions that may contain an eccentric scolex-representing hyperintense nodule. Myelography is still useful in identifying patients with spinal leptomeningeal cysticercosis, as it reveals several filling deficiencies in the column of contrast material corresponding to each cyst [11]. Leptomeningeal cysts may be migratory, changing positions in response to the patient's movements [12].

Antiparasitic drugs, such as Praziquantel and Albendazole, can kill between 60 and 85 percent of brain parenchymal cysticerci when used against *T. solium* cysticerci [13]. Most studies suggest that administering albendazole results in a higher cyst reduction. Seizures may worsen between the second and third days of antiparasitic treatment due to

inflammation following cysticerci destruction. Corticosteroids are typically administered in combination with antiparasitic drugs to reduce edema resulting from inflammation. It is important to note that while steroids do not affect the plasma level of albendazole, they can affect praziquantel levels [14]. The treatment of perilesional edema related to calcified lesions has not been established. Steroids can manage symptoms, but there is limited evidence on whether using them would prevent edema from recurring. Methotrexate has been used to suppress the host inflammatory response in patients with recurrent perilesional edema requiring long-term steroid treatment [15]. Cysticidal medications are not recommended for patients with cysticercotic encephalitis, as they may worsen intracranial hypertension. Instead, corticosteroids and mannitol are used at appropriate doses to reduce edema [1].

Treatment plans for ventricular disease should be individualized. The fourth, third, and lateral ventricles have all been reported to be treated with anthelmintics [16]. Patients with hydrocephalus must have a shunt implanted before beginning medical treatment [17]. Surgery has been the primary treatment for this type of NCC [18]. Flexible neuroendoscopy is increasingly being used for the removal of accessible subarachnoid cysts and cysts trapped in the lateral, third, and fourth ventricles [19]. However, endoscopic removal may not be feasible for cysts that appear enhanced on MRI.

## Conclusion

Neurocysticercosis is a preventable disease with proper food preparation and sanitation practices. Patients often present with seizure episodes, and it affects all age groups, resulting in significant morbidity and mortality, particularly in developing countries. A comprehensive patient history and timely neuroimaging are essential to prevent misdiagnosis of neurocysticercosis as a tuberculosis sequel. Medical professionals managing NCC should be aware of potential confounding factors in diagnosis and the various treatment modalities available.

## Declarations

- Consent was obtained by all participants in this study.
- No conflict of interest
- No financial support was received from any organization for the submitted work
- There are no other relationships or activities that could appear to have influenced the submitted work.

## References

1. <sup>a, b</sup>Del Brutto OH. Neurocysticercosis. *Semin Neurol*. 2005;25:243-51. doi:10.1055/s-2005-917661
2. <sup>^</sup>Del Brutto OH, García HH. *Taenia solium* Cysticercosis--The lessons of history. *J Neurol Sci*. 2015;359:392-5. doi:10.1016/j.jns.2015.08.011
3. <sup>^</sup>Bryceson ADM. NEUROCYSTICERCOSIS: A CLINICAL HANDBOOK. *Brain*. 1999;122:372-3. doi:10.1093/brain/122.2.372

4. <sup>^</sup>Del Brutto OH, Santibañez R, Noboa CA, Aguirre R, Díaz E, Alarcón TA. *Epilepsy due to neurocysticercosis: analysis of 203 patients. Neurology.* 1992;42:389-92. doi:10.1212/wnl.42.2.389
5. <sup>^</sup>Rangel R, Torres B, Del Bruto O, Sotelo J. *Cysticercotic encephalitis: a severe form in young females. Am J Trop Med Hyg.* 1987;36:387-92. doi:10.4269/ajtmh.1987.36.387
6. <sup>^</sup>Ahmad FU, Sharma BS. *Treatment of intramedullary spinal cysticercosis: report of 2 cases and review of literature. Surg Neurol.* 2007;67:74-7. doi:10.1016/j.surneu.2006.03.034
7. <sup>a, b</sup>Bandres JC, White AC Jr, Samo T, Murphy EC, Harris RL. *Extraparenchymal neurocysticercosis: report of five cases and review of management. Clin Infect Dis.* 1992;15:799-811. doi:10.1093/clind/15.5.799
8. <sup>^</sup>García HH, Del Brutto OH. *Imaging findings in neurocysticercosis. Acta Trop.* 2003;87:71-78. doi:10.1016/s0001-706x(03)00057-3
9. <sup>^</sup>Martinez HR, Rangel-Guerra R, Elizondo G, et al. *MR imaging in neurocysticercosis: a study of 56 cases. AJNR Am J Neuroradiol.* 1989;10:1011-1019.
10. <sup>^</sup>Rangel-Guerra RA, Herrera J, Elizondo G, Gonzalez-Morantes J. *Neurocysticercosis. Arch Neurol.* 1988;45:492. doi:10.1001/archneur.1988.00520290018006
11. <sup>^</sup>Antoniuk SA, Bruck I, Dos Santos LH, et al. *Seizures associated with calcifications and edema in neurocysticercosis. Pediatr Neurol.* 2001;25:309-11. doi:10.1016/s0887-8994(01)00324-1
12. <sup>^</sup>Santín G, Vargas J. *Roentgen study of cysticercosis of the central nervous system. Radiology.* 1966;86:520-8. doi:10.1148/86.3.520
13. <sup>^</sup>Takayanagui OM, Jardim E. *Therapy for neurocysticercosis. Comparison between albendazole and praziquantel. Arch Neurol.* 1992;49:290-4. doi:10.1001/archneur.1992.00530270106026
14. <sup>^</sup>Vazquez ML, Jung H, Sotelo J. *Plasma levels of praziquantel decrease when dexamethasone is given simultaneously. Neurology.* 1987;37:1561-2. doi:10.1212/wnl.37.9.1561
15. <sup>^</sup>Sotelo J, Guerrero V, Rubio F. *Neurocysticercosis: a new classification based on active and inactive forms. A study of 753 cases. Arch Intern Med.* 1985;145:442-5. doi:10.1001/archinte.1985.00360030074016
16. <sup>^</sup>Zee CS, Segall HD, Destian S, Ahmadi J, Apuzzo ML. *MRI of intraventricular cysticercosis: surgical implications. J Comput Assist Tomogr.* 1993;17:932-9. doi:10.1097/00004728-199311000-00015
17. <sup>^</sup>Cuetter AC, Garcia-Bobadilla J, Guerra LG, Martinez FM, Kaim B. *Neurocysticercosis: focus on intraventricular disease. Clin Infect Dis.* 1997;24:157-64. doi:10.1093/clinids/24.2.157
18. <sup>^</sup>Colli BO, Martelli N, Assirati JA Jr, Machado HR, de Vergueiro Forjaz S. *Results of surgical treatment of neurocysticercosis in 69 cases. J Neurosurg.* 1986;65:309-15. doi:10.3171/jns.1986.65.3.0309
19. <sup>^</sup>Anandh B, Mohanty A, Sampath S, Praharaj SS, Kolluri S. *Endoscopic approach to intraventricular cysticercal lesions. Minim Invasive Neurosurg.* 2001;44:194-6. doi:10.1055/s-2001-19928