

# Sujok Triorigin Therapy For Chalazion: Case Reports

Intansari Nurjannah<sup>1</sup>

<sup>1</sup> Universitas Gadjah Mada

**Funding:** No specific funding was received for this work.

**Potential competing interests:** No potential competing interests to declare.

## Abstract

**Background:** Chalazion is a health problem of the eyelids and is usually caused mainly by a blockage in the ducts of the sebaceous glands.

**Methods:** Therapeutic protocol instructions were made by the researcher in the form of pictures sent to the patient. Patients also reported their progress to the researcher. There were two cases of chalazion: one patient (male) with a chalazion in the right eyelid, and one case (female) with a chalazion in the left eyelid.

**Result:** The chalazion became deflated in the male patient on day 3, while in the female patient, it was on day 4.

**Conclusion:** Sujok Triorigin Therapy was used to treat chalazion.

**Intansari Nurjannah\***

*Professor, Department of Mental Health and Community Nursing, Faculty of Medicine, Public Health and Nursing, Universitas Gadjah Mada, Indonesia*

**\*Correspondence:**

Jln. Farmako Sekip Utara, Yogyakarta 55281

E-Mail: [intansarin@ugm.ac.id](mailto:intansarin@ugm.ac.id)

Phone: +62 82227997622

**Keyword:** Sujok, Triorigin Therapy, Chalazion, problem of eyelids.

## 1. Introduction

Chalazion occurs due to the obstruction of the sebaceous gland duct, and it is a chronic condition in which there is inflammation of the sebaceous glands of the eyelids <sup>[1]</sup>. The main parts of the sebaceous gland involved are the

meibomian glands of the eyelids which may eventually trigger various lesions on the eyelids [2]. Chalazion is a disorder of the eyelids that can occur at any age [3].

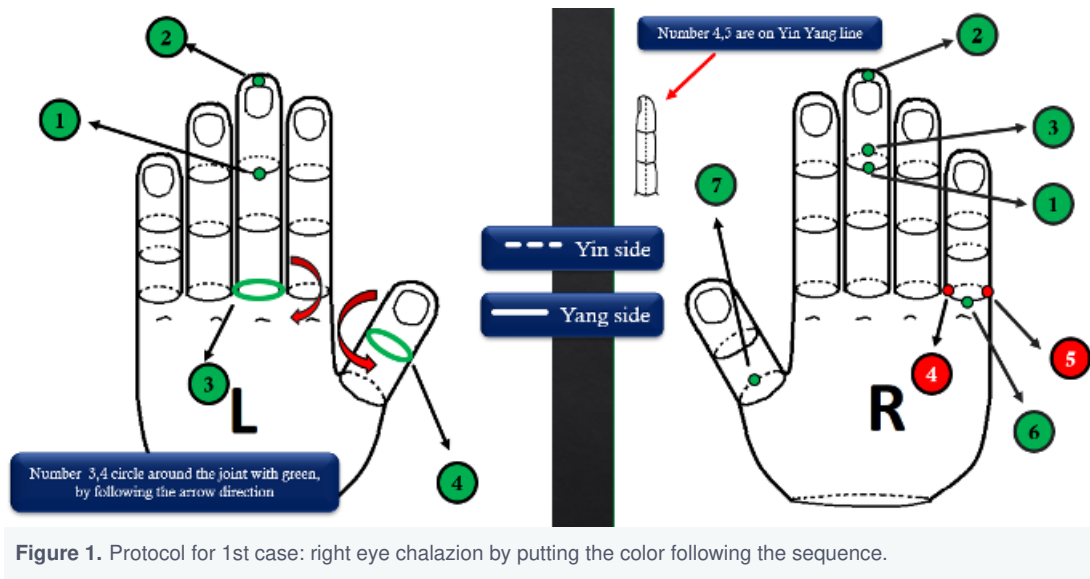
Chalazion could also be a non-infectious condition and only a blockage in the sebaceous gland duct. Other causes related to chalazion can be associated with viral conjunctivitis [4]. The symptoms of a chalazion begin with a red, soft and swollen eyelid that eventually becomes a painless lump [5]. Research shows that the incidence of chalazion increased significantly in the San Francisco Bay Area and Los Angeles Country when mask use was associated with the COVID-19 pandemic [6].

This case report article demonstrates that non-surgical therapy with Triorigin Therapy using the color method can overcome chalazion cases.

## 2. Case Presentation

This case report involves two patients who had chalazion problems. The researchers did not meet directly with patients but used social media (Telegram) to communicate with them. The researchers responded to requests for a treatment protocol beginning with an assessment by asking about the history and symptoms, including which eye area had a chalazion. After that, the researchers gave a color therapy protocol with Triorigin therapy (Triorigin Therapy is one type of different method in Sujok therapy) and sent the protocol to the patients, who performed the therapy and took photos of the affected eye area before and after therapy, and then sent them to the researchers. Permission to publish these two cases was granted after the patients recovered, and both patients agreed to have their cases (both information and pictures) published anonymously.

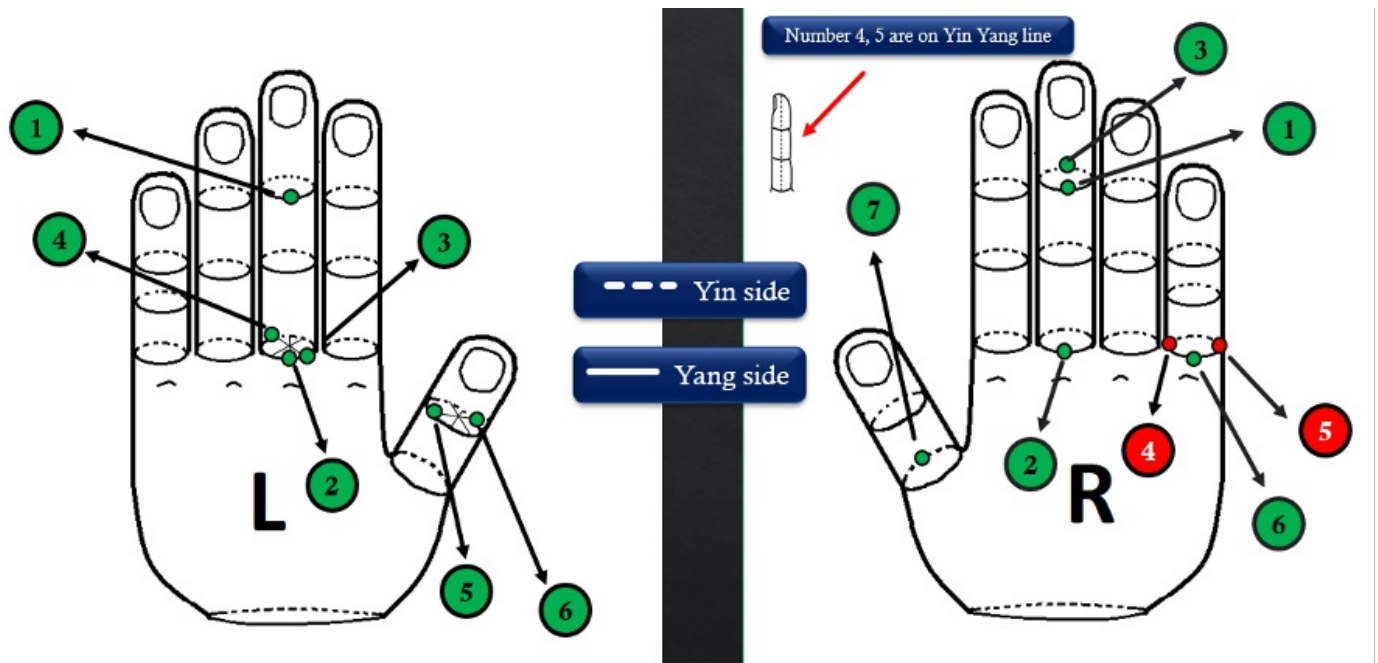
The first case involved a 40-year-old male with a problem under his right upper eyelid, approximately 5 mm to 7 mm. The symptoms were a visible swelling with red and yellowish color, which caused his eyes to water and sometimes blurred his vision, with stickiness in the eyes that pushed on the eyeball. After undergoing surgery twice in 5 years, the lesion reappeared. In this first case, the patient kept applying the color therapy (Fig. 1) for three days whenever it was washed away by water. The second case involved a 45-year-old female with an area of chalazion on the left eye. The symptoms included swelling with mild irritation and a mild left-side headache for 1 week, starting 6 months ago. Although she underwent surgery, the lesion kept coming back. She applied the color therapy (Fig. 2) for four days. For the first two days, treatment was just done twice a day but was continued four times a day for another 2 days.



The explanation of Figure 1 can be seen in Table 1. The code F refers to Finger, J for Joint, and P for Point, while Ne refers to Neutro, He refers to Hetero, Ho refers to Homo, and No refers to Neuto.

**Table 1.** Protocol for right eye chalazion on right and left hand

| The protocol's aim: to clear blockage on sebaceous gland by sedating Homo in sebaceous gland of right eye – therapy applied on right hand. |      |                                               |                                                                                         |                       |
|--------------------------------------------------------------------------------------------------------------------------------------------|------|-----------------------------------------------|-----------------------------------------------------------------------------------------|-----------------------|
| Step                                                                                                                                       | Code | Location                                      | Explanations                                                                            | Number in the picture |
| A                                                                                                                                          | Ne-F | Middle finger                                 | Neuro Finger as unit of neutro type of Triorigin Models - all body system- neutro type  |                       |
| B                                                                                                                                          | He-J | Upper joint                                   | Hetero Joint (upper joint) as Triorigin model lying at the base of Triorigin Sequence   |                       |
| C                                                                                                                                          | Ne-P | Point on the back side of finger              | Rent to head                                                                            | 1                     |
| D                                                                                                                                          | Ne-F | Middle finger                                 | Open as a head                                                                          |                       |
| E                                                                                                                                          | No-J | Nail                                          | Is the right side of face between eyebrow and chin                                      |                       |
| F                                                                                                                                          | Ne-P | Point on the top of finger                    | Rent to area in which right eye is located                                              | 2                     |
| G                                                                                                                                          | Ne-F | Middle finger                                 | Area in which right eye is located                                                      |                       |
| H                                                                                                                                          | He-J | Upper joint                                   | Skin of area in which right eye is located                                              |                       |
| I                                                                                                                                          | No-P | Point on the front side (palm side) of finger | Rent to sebaceous gland                                                                 | 3                     |
| J                                                                                                                                          | No-F | Little finger                                 | Is sebaceous gland                                                                      |                       |
| K                                                                                                                                          | Ho-J | Lower joint                                   | Is chosen as target of therapy as the disease characteristic is homo disease            |                       |
| L                                                                                                                                          |      |                                               | ↓ Ho (Sedate Homo) with red                                                             | 4                     |
|                                                                                                                                            |      |                                               | ↑ He (Tonify Hetero) with red                                                           | 5                     |
|                                                                                                                                            |      |                                               | ↓ Ne (Tonify Neutro) with green                                                         | 6                     |
|                                                                                                                                            |      |                                               | ⊥ (Controller) with green                                                               | 7                     |
| The protocol's aim: to reduce swelling on area of right eye – applied to left hand                                                         |      |                                               |                                                                                         |                       |
| Step                                                                                                                                       | Code | Location                                      | Explanations                                                                            | Number in the picture |
| A                                                                                                                                          | Ne-F | Middle finger                                 | Neuro Finger as unit of neutro type of Triorigin Models - all body system- neutron type |                       |
| B                                                                                                                                          | He-J | Upper joint                                   | Hetero Joint as Triorigin model lying at the base of Triorigin Sequence                 |                       |
| C                                                                                                                                          | Ne-P | Point on the back side of finger              | Rent to head                                                                            | 1                     |
| D                                                                                                                                          | Ne-F | Middle finger                                 | Open as head                                                                            |                       |
| E                                                                                                                                          | No-J | Nail                                          | Is right side of face between eyebrow and chin                                          |                       |
| F                                                                                                                                          | Ne-P | Point on the top of nail                      | Rent to area in which right eye is located                                              | 2                     |
| G                                                                                                                                          | Ne-F | Middle finger                                 | Area in which right eye is located                                                      |                       |
| H                                                                                                                                          | Ho-J | Lower joint                                   | Is chosen as target of therapy as the disease characteristic is homo disease            |                       |
| I                                                                                                                                          |      |                                               | ↓IV (Sedate humidity energy)                                                            | 3                     |
|                                                                                                                                            |      |                                               | ↑I (Tonify wind energy)                                                                 |                       |
|                                                                                                                                            |      |                                               | ⊥ (Controller)                                                                          | 4                     |
|                                                                                                                                            |      |                                               | ↓I V (Sedate humidity energy)                                                           |                       |
|                                                                                                                                            |      |                                               | ↑I (Tonify wind energy)                                                                 |                       |



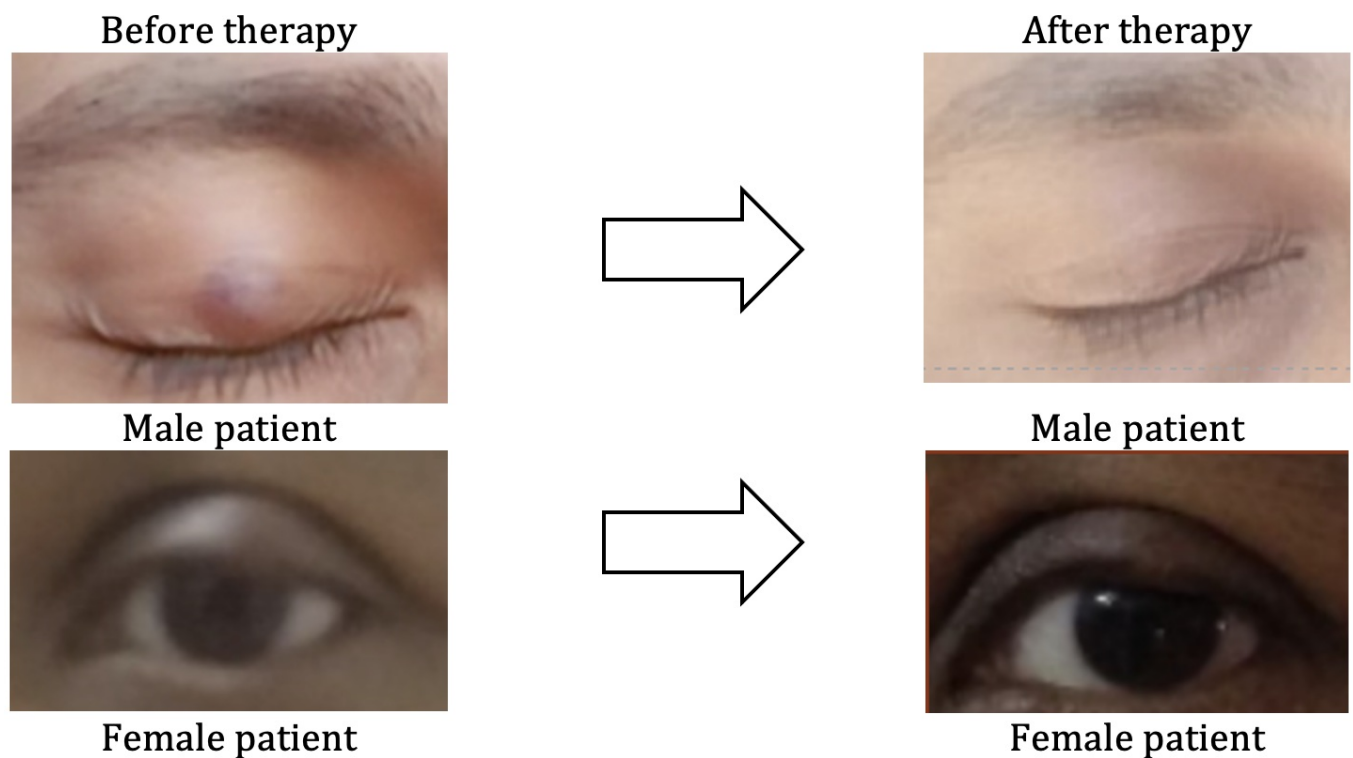
**Figure 2.** Protocol for 2nd case: left eye chalazion by putting the color following the sequence.

The explanation of Figure 2 can be seen in Table 2.

**Table 2.** Protocol for right eye chalazion on right and left hand

| The protocol's aim: to clear blockage on sebaceous gland of left eye by sedating Homo in sebaceous gland of left eye – applied on right hand |      |                                  |                                                    |                       |
|----------------------------------------------------------------------------------------------------------------------------------------------|------|----------------------------------|----------------------------------------------------|-----------------------|
| Step                                                                                                                                         | Code | Location                         | Explanations                                       | Number in the picture |
| A-D                                                                                                                                          |      |                                  | The same as table 1                                |                       |
| E                                                                                                                                            | Ho-J | Lower joint of finger            | Is left side area of face between eyebrow and chin |                       |
| F                                                                                                                                            | Ne-P | Point of the back side of finger | Rent to area in which left eye is located          | 2                     |
| G                                                                                                                                            | Ne-F | Middle finger                    | Area in which left eye is located                  |                       |
| H - L                                                                                                                                        |      |                                  | The same as table 1                                |                       |
| The protocol's aim: to reduce swelling on area of left eye – applied on left hand                                                            |      |                                  |                                                    |                       |
| Step                                                                                                                                         | Code | Location                         | Explanations                                       | Number in the picture |
| A-D                                                                                                                                          |      |                                  | The same as Table 1                                |                       |
| E                                                                                                                                            | Ho-J | Lower joint                      | Area left side of face between eyebrow and chin    |                       |
| F                                                                                                                                            | Ne-P | Point on the back side of finger | Rent to area in which left eye is located          | 2                     |
| G                                                                                                                                            | Ne-F | Middle finger                    | Area in which left eye is located                  |                       |
| H                                                                                                                                            |      |                                  | The same as table 3                                |                       |
| I                                                                                                                                            |      |                                  | ↓IV (Sedate humidity energy)                       | 3                     |
|                                                                                                                                              |      |                                  | ↑I (Tonify Wind energy)                            | 4                     |
|                                                                                                                                              |      |                                  | ⊥ (Controller)                                     |                       |
|                                                                                                                                              |      |                                  | ↓I V (Sedate humidity energy)                      | 5                     |
|                                                                                                                                              |      |                                  | ↑I (Tonify Wind energy)                            | 6                     |

### 3. Result and Discussion



**Figure 3.** The result of therapy

The phenomena associated with chalazion from a Triorigin point of view can be explained as follows. Chalazion occurs because there is a blockage in the sebaceous gland that causes swelling. These two phenomena (blocking as a cause and swelling as a result) need to be overcome using the Triorigin principle, where one hand is used to treat the cause (namely the primary hand) and another hand is used to deal with the effects (swelling). Because both patients are right-handed persons, the therapy to overcome the blockage in the sebaceous gland was done on the right hand.

Basically, everything in the universe can be categorized in a Triorigin model which consists of four types of energy, namely Neuto (No), Hetero (He), Homo (Ho), and Neutro (Ne). Each energy has its own characteristics, and including humans, they consist of 4 components: Soul (Neuto), Mind (Hetero), Body (Homo), and Life (Neutro) [7]. This classification continues so that in the end, it becomes various classifications of certain body parts which are called Triorigin models for certain dimensions of the body [8]. One of the Triorigin models used for the above therapy is the Triorigin Model Structural system combined with the Triorigin Model Layer system. The researchers chose the classification that leads to the sebaceous glands with the Single Hand Pattern choice of therapy. The Single Hand Pattern is a model where each hand can represent an entire area of the body.

The steps in the flow of therapy follow the principles of therapy, which consist of [8]: [1] determining the characteristics of the problem, for example, energy characteristics; then [2] determining the target area of therapy; and [3] doing 'renting'. Renting is a term to open a pathway to the target area to be treated [7][8]. In color therapy, renting is done by placing a green dot in the place of the 'gate' to open the pathway. The flow of the renting is a cycle, from the finger, joint, and point, and back again to the finger [7][8], and so on until it reaches the final target of therapy. In both cases, for therapy on the

right hand, this renting is done in steps C, F, and I. Each renting that has been done will open the finger according to the point at which the renting is applied.

Fingers are divided into four types, namely Hetero finger (index finger), Neutro finger (middle finger), Homo finger (ring finger), and Neuto finger (little finger). Thus, if we rent at the Hetero point, the Hetero finger (index finger) will open (be selected), and this same rule also applies to the other points. This selected finger is part of the renting cycle (finger-joint-point) to reach the target area [4]. Each finger is also divided into 4 joints: the upper joint is the Hetero joint, the middle joint is the Neutro joint, the lower joint is the Homo joint, and the nail is the Neuto joint. In each joint, there are also 4 points: the Hetero point, Neutro point, Homo point, and Neuto point. After arriving at the area targeted for therapy, this is where the therapy formula is applied [5].

The blockage in Triorigin belongs to the homo disease category, so the therapy is done by using the principle of sedation therapy at the Homo point with the red color, tonifying the axis of the Homo point with red as well, namely Hetero, tonifying the Neutro, and the last step is the controller, which is the standard operating procedure for each therapy protocol, made both with green [9]. As for the left hand, therapy is done to target the swelling by sedating humidity. In Six Ki [10], swelling represents humidity.

For the second case, because the case is on the left eye, the difference is that when it reaches the head, the selected facial area is on the left side of the face, and the next path is the same as in the first case. In addition, in the left hand, for the second case, the method of sedating humidity is different from the left hand in the first case, but basically, this method gives the same effect.

The limitation of this case study report is that no data came from the results of the patients' medical reports, while all chalazion specimens, whether they occur for the first time or have been repeated, should be examined for histopathology [2]. Although it seems easy to diagnose chalazion, it can trigger benign, premalignant, and malignant lesions [2]. Even if there are other examination results, the Triorigin therapy protocol will also be adjusted to the disease character. Therefore, the therapeutic protocol that has been used above can only be used for conditions where there is a blockage of the sebaceous glands and cannot be used for conditions with other causes of chalazion.

## Conclusion

The Triorigin therapy was successful in overcoming the chalazion problem. However, research with more rigorous designs is needed in the future.

## Acknowledgements

Thanks to all participants who were willing to share their experience.



## Conflict of Interest

There is no conflict of interest regarding these case reports.

## References

1. <sup>a, b</sup>Malekahmadi M.; Farrahi F.; Tajdini A. Serum vitamin A levels in patients with chalazion. *Medical Hypothesis, Discovery and Innovation in Ophthalmology*. 2017;6(3),63.
2. <sup>a, b, c, d</sup>Özdal PÇ.; Codère F.; Callejo S.; Caissie A.; Burnier M. Accuracy of the clinical diagnosis of chalazion. *Eye*. 2004,18(2),135-8.
3. <sup>a, b</sup>Unal M. Chalazion treatment. *Taylor & Francis*; 2008. p. 397-8.
4. <sup>a, b</sup>Mansour.; Chan C.; Crawford M.; Tabbarah Z.; Shen D.; Haddad W, et al. Virus-induced chalazion. *Eye*. 2006, 20(2), 242-6.
5. <sup>a, b</sup>Chang M.; Park J.; W, Kyung S, E. Extratarsal presentation of chalazion. *Int Ophtalmol*. 2017;37:1365-7.
6. <sup>^</sup>Silkiss RZ.; Paap MK.; Ugradar S. Increased incidence of chalazion associated with face mask wear during the COVID-19 pandemic. *American journal of ophthalmology case reports*. 2021,22,101032.
7. <sup>a, b, c</sup>Park J, W. *Triorigin Acupuncture*. 1 V, editor. Jaipur, India: Smile Academy; 2008.
8. <sup>a, b, c, d</sup>Nurjannah I.; Shidqi A, Isa. *The 2nd Book Series of Su Jok Triorigin Therapy - App Version (Combination of Correspondence System, Triorigin Sequence, Triorigin Model and Six Ki)*. Yogyakarta: Self-Publishing; 2022.
9. <sup>^</sup>Nurjannah I.; Shidqi A, Isa. *Aplikasi Sistem Pengobatan Berdasarkan Teori Triorigin (Buku ke-1: Triorigin Sequence)*. Yogyakarta: Mocomedia; 2021.
10. <sup>^</sup>Park J, W. *The Six Ki Energy Teory Illustrated Hand Book*. Jaipur, India: Smile Academy Pvy Ltd; 2022.