

[Open Peer Review on Qeios](#)

[Case Study] Targeting the Warburg Effect with Glucose Mutation Theory in Post-Cystectomy, Chemotherapy-Contraindicated Cases: A Case Study of a 72-Year-Old Female Treated with Glucosodiene Over a 20-Day Period

Amr Ahmed¹, Maher Akl²

¹ Ministry of Health Saudi Arabia

² Mansoura University

Funding: No specific funding was received for this work.

Potential competing interests: No potential competing interests to declare.

Abstract

This manuscript delves into the intricate landscape of bladder cancer, highlighting the challenges of early detection and the nuanced considerations involved in chemotherapy decision-making based on patient-specific factors. The Maher Akl's groundbreaking Glucose Mutation Theory, presenting Glucosodiene as a promising breakthrough. The case presentation meticulously details the journey of a 72-year-old woman diagnosed with high-grade papillary urothelial carcinoma, spanning from initial diagnosis to postoperative outcomes. In the face of Bacillus Calmette-Guérin (BCG) therapy failure, Glucosodiene emerges as a safe and reliable alternative, offering a novel and effective treatment avenue, especially in cases where traditional chemotherapy is contraindicated. This approach advocates for Glucosodiene as a primary therapeutic option after the shortcomings of conventional treatments, instilling confidence in its efficacy and safety, particularly for cases deemed ineligible for chemotherapy.

Amr Ahmed

The public health department, Riyadh First Health Cluster, Ministry of Health, Saudia Arabia.

ORCID iD: 0000-0003-3477-236X

Maher Monir. Akl

Department of Chemistry, Faculty of Science, Mansoura University, 35516, Mansoura, Egypt.

ORCID iD: 0000-0001-5480-1688

*Correspondence

Maher Monir. Akl

Department of Chemistry, Faculty of Science,
Mansoura University, 35516, Mansoura, Egypt.

Phone: +201020432031

E-mail: maherakl555@gmail.com

ORCID iD: 0000-0001-5480-1688

Keywords: Bladder Cancer, Chemotherapy, Chemotherapy Ineligible Cases, Total Cystectomy, Glucose Mutation Theory, Glucosodiene.

Introduction

Bladder cancer, a malignant neoplasm originating in the urothelial lining of the bladder, presents a significant public health concern due to its elevated incidence and potential for metastasis to adjacent structures, notably the lymph nodes. The insidious nature of this malignancy lies in its proclivity to often remain asymptomatic in the early stages, resulting in delayed diagnosis and diminished treatment efficacy. Histopathologically diverse, bladder cancer primarily manifests as transitional cell carcinoma, showcasing aggressive behavior and proclivity for recurrence. The hazardous dissemination of bladder cancer to the pelvic lymph nodes underscores the paramount importance of early detection and intervention to mitigate the risk of metastatic progression, thereby enhancing patient outcomes and prognosis. ^{[1][2]} A comprehensive understanding of the intricate molecular pathways implicated in bladder cancer pathogenesis is imperative for devising targeted therapeutic strategies that may attenuate neoplastic potential, contributing to the overall management of this formidable disease. ^{[3][4]}

The administration of chemotherapy represents a pivotal facet in cancer treatment; however, the inherent risks associated with this therapeutic modality necessitate a nuanced consideration of patient-specific factors. ^[5] Health practitioners encounter a complex landscape of contraindications that preclude patients from undergoing chemotherapy either prior to surgical intervention or in the postoperative phase. These contraindications encompass a spectrum of health impediments, from compromised organ function to severe immunodeficiency.

Factors such as pre-existing comorbidities, advanced age, and the overall health status of the patient contribute to the intricate decision-making process surrounding chemotherapy eligibility. Striking a delicate balance between the potential benefits of chemotherapy and the risks posed by underlying health conditions becomes imperative. ^{[6][7]} In navigating this intricate terrain, healthcare providers must meticulously assess each patient's medical history, thoroughly considering contraindications, to tailor treatment strategies that optimize therapeutic outcomes while mitigating potential adverse effects. This critical evaluation ensures a personalized and targeted approach to cancer management, safeguarding patient well-being amid the complex interplay of chemotherapy and individual health dynamics. ^[8] Despite these formidable challenges, Maher Akl's groundbreaking theory of glucose mutation, forming the basis for the development of the drug Glucosodiene, instills confidence in its potential. Glucosodiene emerges as a promising drug agent targeting the Warburg effect across tumors reliant on anaerobic glucose metabolism. ^[9] Positive outcomes have been reported, notably in a case study of a patient with metastatic triple-negative breast cancer affecting the bones, who experienced significant

improvement within a 15-day treatment period with Glucosodiene. ^[10] In this study, our objective is to assess the impact of Glucosodiene on cases where conventional chemotherapeutic interventions are restricted, particularly post-tumor resection surgeries. This approach aims to provide a safe alternative to traditional chemotherapy, mitigating the emergence and progression of cancer stem cells.

Case Presentation

Patient Information

The patient, a 72-year-old lady of Caucasian and Arab descent, has been diagnosed with bladder cancer and associated urothelial neoplasms. This initial examination represents the findings from the initial assessment preceding the planned surgical resection. The diagnosis indicates a high-grade papillary urothelial carcinoma according to the WHO/ISUP 2016 classification, with chorion infiltration and no observed vascular emboli. TNM classification AJCC 2017: pT1 NX Mx.

Clinical findings timeline

The 72-year-old female patient, without a family history of tumors, presented with unusual symptoms, notably the onset of hematuria **on January 18, 2023**. Subsequently, the case progressed to a clinical examination, necessitating an initial assessment through ultrasound **on January 23, 2023**. The abdominal-pelvic ultrasound revealed normal liver size, gallbladder without stones, and both kidneys displaying good corticomedullary differentiation without dilation of excretory cavities. Adrenal glands were free, and there was no ascitic fluid accumulation, deep abdominal lymphadenopathy, or identified masses. However, the bladder exhibited a semi-filled state with homogenous liquid content and focal irregular wall thickening, particularly marked in the left posterolateral aspect measuring 38/23mm. The conclusion highlighted multifocal, irregular, and budding tumor-associated wall thickening in the bladder, with fine peripheral calcifications. Notably, no associated hydronephrosis was observed on this day. The overall abdominal-pelvic ultrasound findings were unremarkable apart from the aforementioned bladder abnormalities. ^[Figure 1]

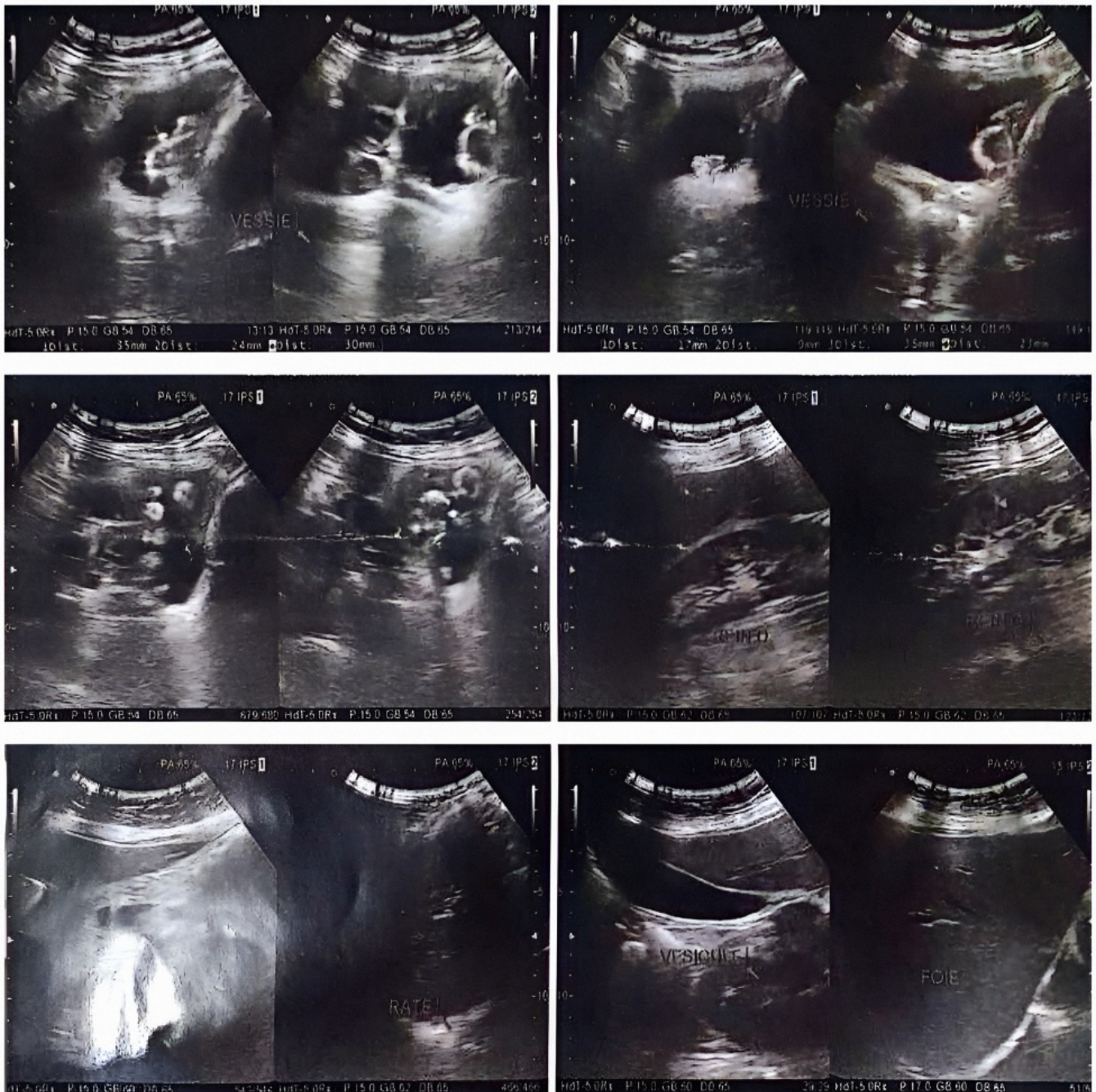


Figure 1. The ultrasound conducted on January 23, 2023, revealed normal liver and gallbladder, well-differentiated kidneys, and free adrenal glands. No ascitic fluid or abdominal masses were detected. However, the bladder showed irregular wall thickening, measuring 38/23mm, with multifocal budding and fine calcifications. No hydronephrosis was observed. Overall, the abdominal-pelvic ultrasound indicated unremarkable findings aside from the noted bladder abnormalities.

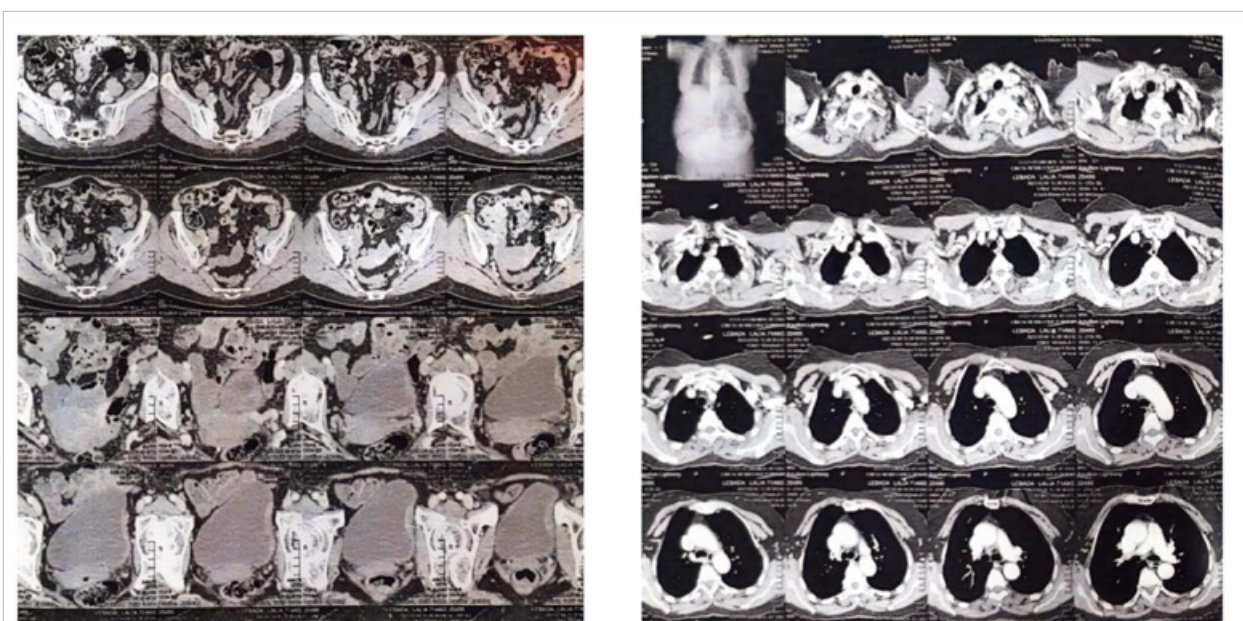
On February 9, 2023, a cystoscopy was conducted to determine the type and grade of the bladder tumor. The results, documented indicated a malignant epithelial tumor proliferation infiltrating the lamina propria. The tumor displayed flat masses and irregularly thick coalescent papillary structures with a conjunctive-vascular axis, characterized by several layers of transitional cells, significant loss of polarity, marked nuclear pleomorphism, hyperchromatic nuclei with prominent nucleoli, and frequent mitoses throughout the epithelial thickness. No intravascular tumor emboli were visualized. The

histopathological assessment concluded that the findings were consistent with a high-grade papillary urothelial carcinoma, aligning with the WHO/ISUP 2016 classification. Chorion infiltration was noted, and there were no vascular emboli observed. The TNM classification according to AJCC 2017 was determined as pT1 NX Mx. This cystoscopic examination served as a pivotal step in elucidating the detailed characteristics and staging of the bladder tumor, further informing the patient's diagnostic and treatment trajectory.

On March 3, 2023, a comprehensive evaluation of the patient's medical condition was conducted through a full-body computed tomography (CT) scan, with a focus on the osseous, thoraco-abdomino-pelvic regions, both without and with iodine contrast agent injection. The examination aimed to further elucidate the complexities of the previously diagnosed bladder tumor. The detailed radiological findings, initially documented in French, are as follows; In the osseous windows, no lesions were identified, confirming the absence of skeletal abnormalities.

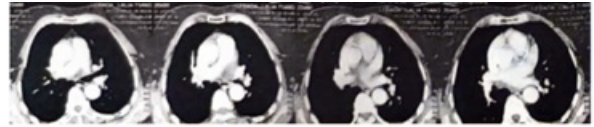
Moving to the thoracic region, a notable lower right ventro-lobar pulmonary nodule measuring 5mm was observed in the postero-basal area. Simultaneously, the abdominal-pelvic assessment revealed intricate details, particularly concerning the bladder and adjacent structures. The bladder exhibited a semi-filled state with a diverticulum, manifesting focal endophytic thickening on the left lateral wall. This thickening, reaching 9.6mm in diameter, displayed a cleavage plan and homogeneous enhancement. The conclusion suggested the necessity for reassessment regarding both size and morphology. Importantly, there were no discernible abnormalities in the abdominal, pelvic, nodal, or secondary osseous visceral regions. Additional scrutiny of abdominal organs revealed an enlarged liver measuring 190mm with regular contours, homogeneous density, and enhancement. The spleen maintained a normal size with regular contours and homogeneous enhancement. Likewise, the pancreas exhibited a normal size without abnormalities in size or homogeneous enhancement. The renal system demonstrated functional kidneys without morphological or size anomalies, while the adrenal glands appeared unremarkable. Gynecological findings included a normal-sized uterus with regular morphology and bilateral uterine venous circulation. The cul-de-sac of Douglas was reported as free from abnormalities.

[Figure 2]





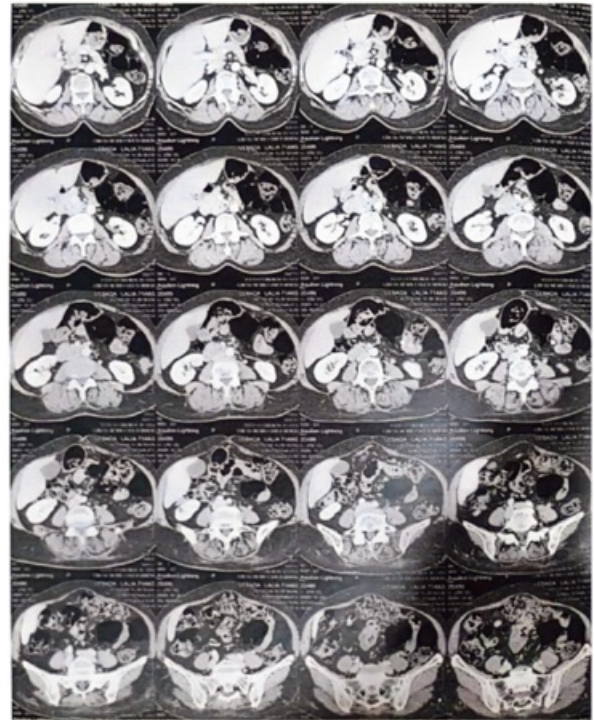
A



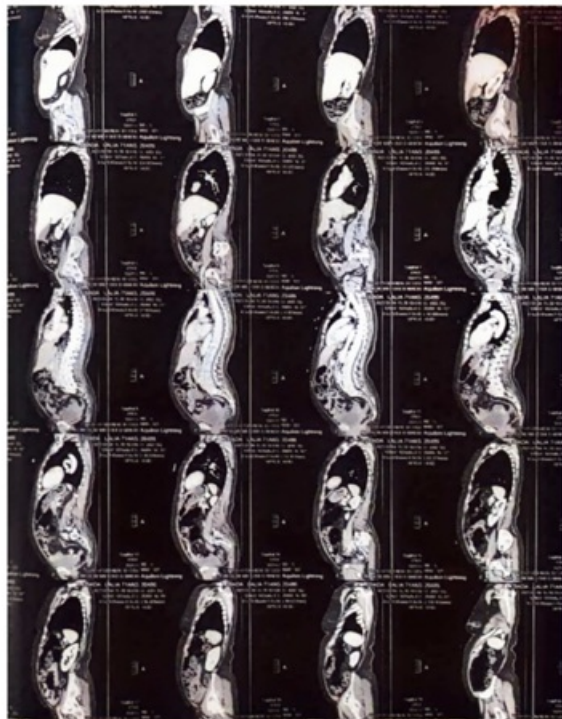
B



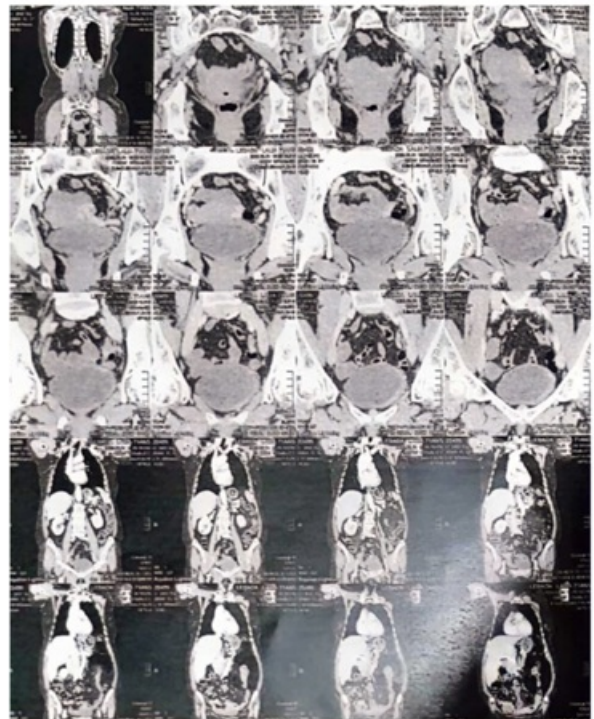C



D



E



F



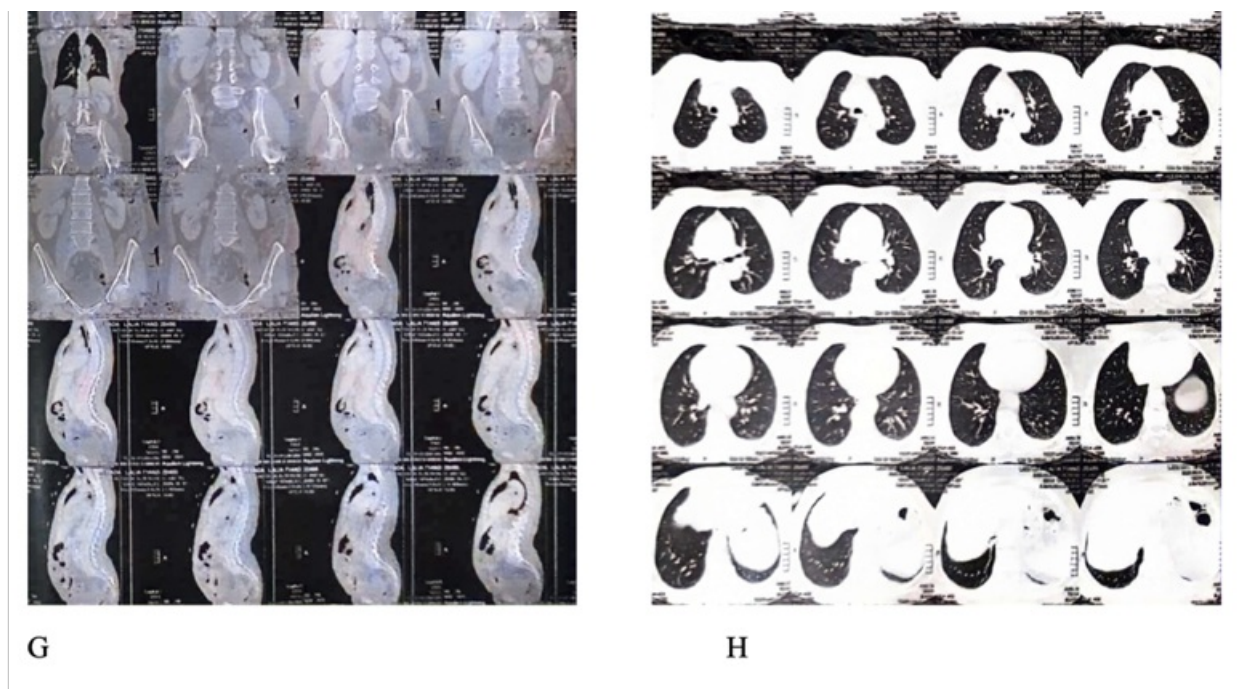


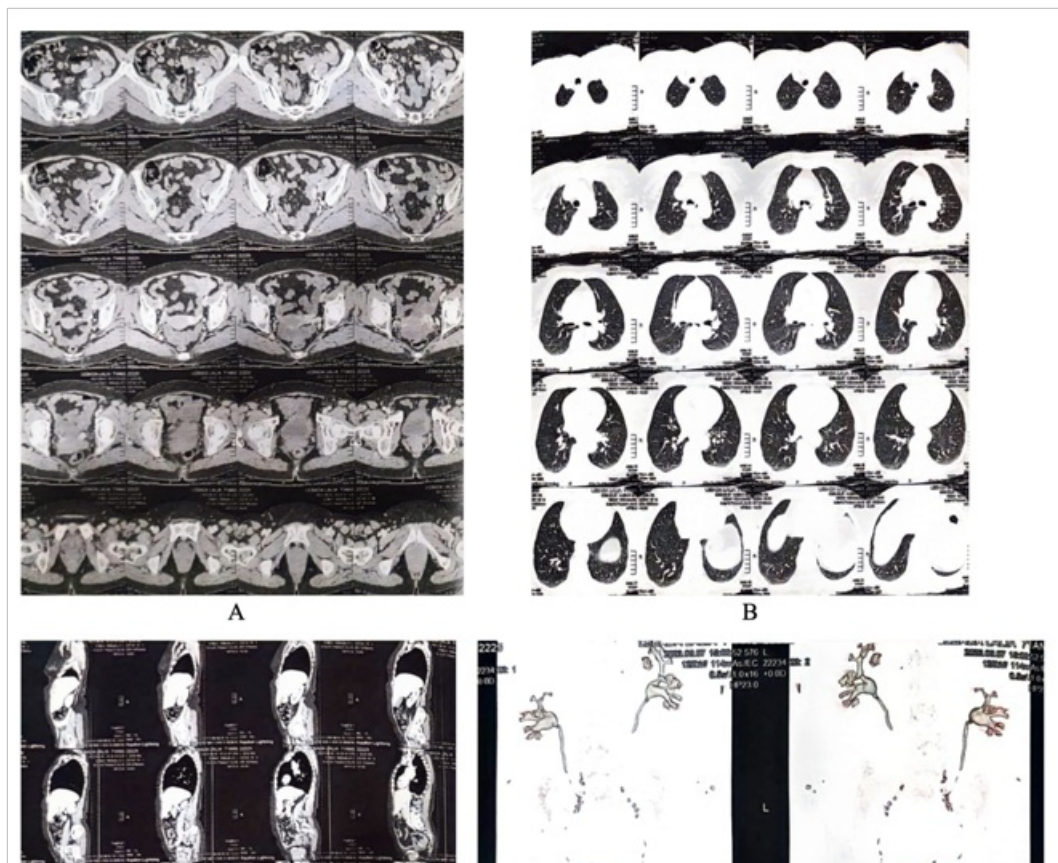
Figure 2. A thorough assessment of the patient's medical condition was conducted through a comprehensive full-body computed tomography (CT) scan, encompassing the osseous, thoraco-abdomino-pelvic regions, both with and without the administration of iodine contrast agent. The primary objective of this examination was to elucidate the intricacies associated with a previously diagnosed bladder tumor. Radiological findings, initially documented, reveal a lack of osseous abnormalities. In the thoracic region, attention is drawn to a 5mm lower right ventro-lobar pulmonary nodule in the postero-basal area. Meanwhile, the abdominal-pelvic assessment divulges specific details, notably concerning the bladder and surrounding structures. The bladder, in a semi-filled state, exhibits a diverticulum with focal endophytic thickening on the left lateral wall, measuring 9.6mm in diameter. This thickening, characterized by a cleavage plane and homogeneous enhancement, necessitates reassessment regarding both size and morphology. Importantly, no abnormalities are detected in the abdominal, pelvic, nodal, or secondary osseous visceral regions. Further scrutiny of abdominal organs reveals an enlarged yet morphologically regular liver (190mm), a normal-sized spleen with homogeneous density and enhancement, and a normally sized pancreas without anomalies in size or enhancement. The renal system showcases functional kidneys without morphological or size irregularities, while the adrenal glands appear unremarkable. Gynecological findings include a normal-sized uterus with regular morphology, bilateral uterine venous circulation, and a cul-de-sac of Douglas free from abnormalities.

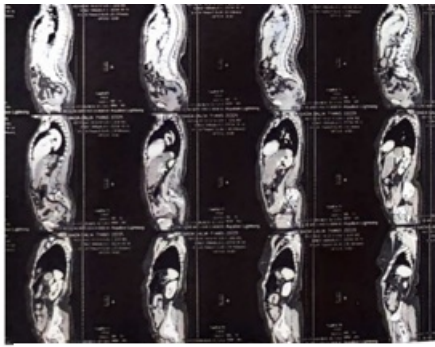
On March 15, 2023, the medical team formulated a therapeutic strategy for the patient, opting to initiate a course of Bacillus Calmette-Guérin (BCG) intravesical therapy as part of the treatment plan for bladder cancer. This decision marked a pivotal step in the comprehensive management of the patient's condition. Intravesical BCG therapy involves the administration of Bacillus Calmette-Guérin, a live attenuated strain of *Mycobacterium bovis*, directly into the bladder. This immunotherapeutic approach aims to stimulate the patient's immune response and enhance the body's ability to combat and eradicate cancerous cells within the bladder lining. The mechanism of action behind intravesical BCG therapy is multifaceted. BCG induces a localized inflammatory response within the bladder, attracting immune cells such as macrophages and T lymphocytes. This immune activation triggers a cascade of events, including the release of cytokines and other signaling molecules, fostering an environment hostile to cancer cells. Additionally, BCG appears to induce an immunological memory, enhancing the body's ability to mount a robust defense against future tumor cells.

The patient underwent a series of six intravesical BCG injections, administered weekly. This structured regimen is designed to optimize the therapeutic effects of BCG while mitigating potential side effects. The weekly administration allows for sustained immune stimulation and engagement with cancer cells, contributing to the overall efficacy of the treatment. The decision to employ intravesical BCG therapy underscores a strategic commitment to harnessing the body's immune system in the fight against bladder cancer. This approach aligns with contemporary therapeutic paradigms, emphasizing the integration of immunomodulatory strategies to achieve a comprehensive and tailored treatment plan for the patient's benefit. [11][12]

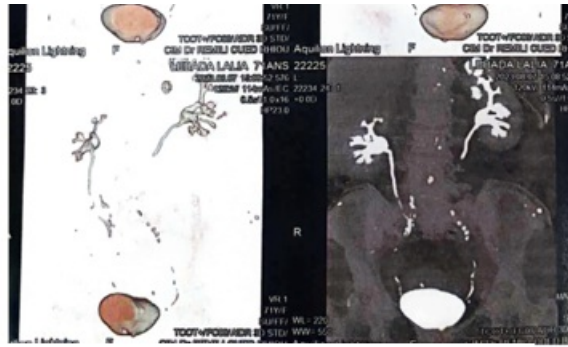
On August 7, 2023, a follow-up computed tomography (CT) scan was conducted to assess the progression of the bladder tumor, specifically in the context of Bacillus Calmette-Guérin (BCG) injection therapy.

Radiological findings revealed focal, irregular, and budding thickening of the anterolateral left bladder wall, measuring 13mm. Notably, this thickening spared the vesical floor, maintained distance from ureteral ostia, and raised concerns on cystography, warranting specialized consultation. The examination detected no anomalies in pulmonary parenchyma, mediastinal lymph nodes, or pleural space. Vascular integrity and the absence of secondary visceral or nodal involvement were noted in the thoraco-abdomino-pelvic regions. The liver, ureters, pancreas, spleen, and renal system exhibited normal findings, with a Bosniak I cyst identified in the mid-right kidney. Gynecological assessments indicated no abnormalities in the uterus. This comprehensive radiological evaluation serves as a crucial tool in gauging the response to BCG therapy, guiding further diagnostic considerations, and informing the ongoing therapeutic approach for the patient's bladder cancer. [Figure 3]

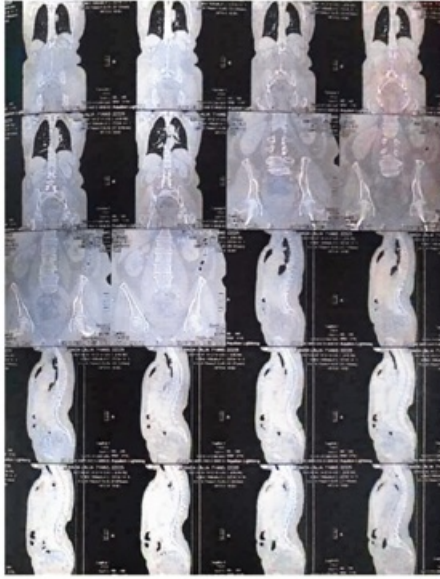



C



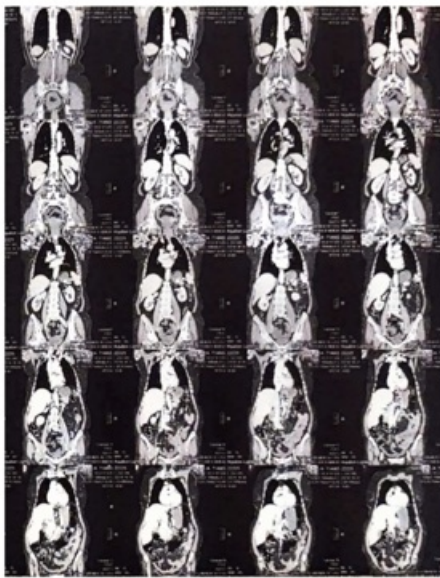D



E



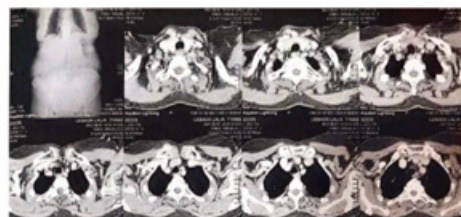
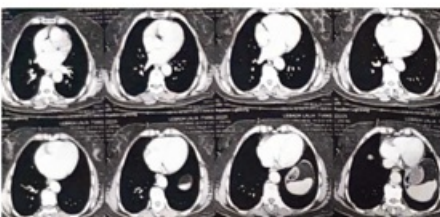
F



G



H



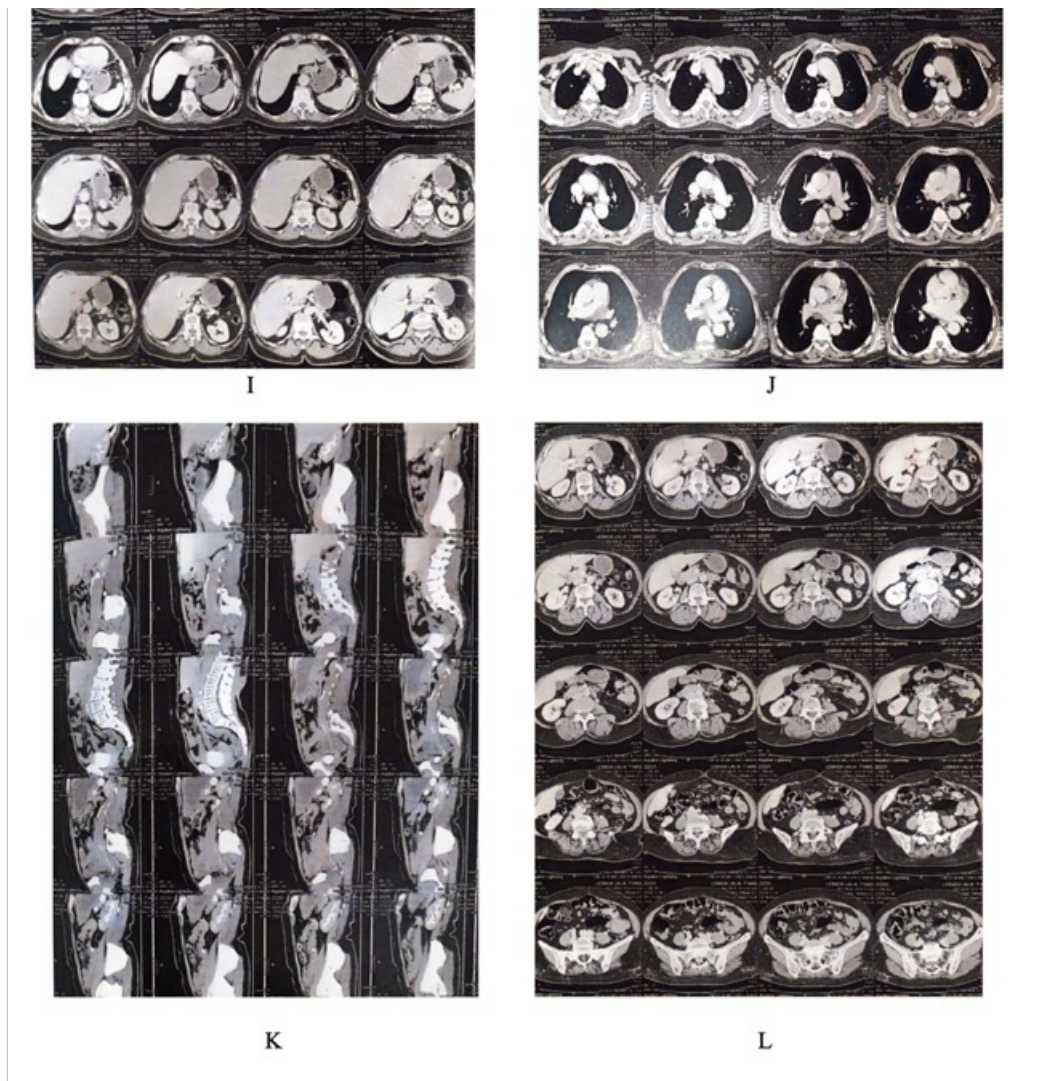


Figure 3. In a subsequent computed tomography (CT) scan aimed at assessing the progression of the bladder tumor within the context of Bacillus Calmette-Guérin (BCG) injection therapy, radiological findings disclosed focal, irregular, and budding thickening of the anterolateral left bladder wall, measuring 13mm. Significantly, this thickening exhibited sparing of the vesical floor, maintained a distance from ureteral ostia, and prompted concerns on cystography, necessitating specialized consultation. The examination identified no abnormalities in pulmonary parenchyma, mediastinal lymph nodes, or pleural space. Vascular integrity and the absence of secondary visceral or nodal involvement were observed in the thoraco-abdomino-pelvic regions. Normal findings were noted in the liver, ureters, pancreas, spleen, and renal system, with the identification of a Bosniak I cyst in the mid-right kidney. Gynecological assessments revealed no abnormalities in the uterus. This comprehensive radiological evaluation stands as a pivotal tool for gauging the response to BCG therapy, guiding further diagnostic considerations, and informing the ongoing therapeutic approach for the patient's bladder cancer.

On September 19, 2023; following the failure of Bacillus Calmette-Guérin (BCG) therapy and the escalation of a more aggressive tumor presentation, the decision was made to proceed with a radical cystectomy. This surgical intervention involved the complete removal of the bladder, coupled with urinary diversion utilizing a segment of the intestines. Subsequent to the procedure, an in-depth analysis of the excised tumor was undertaken to elucidate its histological and molecular characteristics. The patient, who had undergone six sessions of BCG therapy, exhibited a conscious and

cooperative demeanor during clinical examination, with no hematuria or pelvic pain noted. Abdominal examination revealed suppleness, and no palpable lymph nodes were detected. Biological assessments indicated a stable hemoglobin level of 12.4 g/dL, a white blood cell count of 7000/mm³, a urea level of 0.46 mmol/L, creatinine at 7 μmol/L, and albumin measuring 42 g/L. Radiological evaluation through a thoraco-abdomino-pelvic CT scan unveiled focal, irregular, and budding thickening of the anterolateral left bladder wall, measuring 13mm. Notably, there was no invasion of the vesical floor or extra-vesical structures, and no regional lymphadenopathy or secondary localizations were observed.

The surgical procedure involved a pelvic anterior exenteration with urinary diversion utilizing a Bricker-type approach. Postoperatively, the patient exhibited favorable clinical and biological progress, leading to discharge on the 10th day. The left drain was removed, and biological parameters normalized. A functional Bricker diversion with a clean dressing was maintained, ensuring optimal postoperative recovery and addressing the aggressive nature of the bladder tumor.

Following the bladder removal, the pathological analysis of the specimens revealed a comprehensive overview. The macroscopic examination included the anterior pelvic exenteration specimen, consisting of the bladder with a 1 cm ulcerating tumor, and a total hysterectomy with a free uterine lumen. In addition, lymphadenectomies were conducted on the right ilio-obturator, left ilio-obturator, and right external iliac regions. Microscopic analysis of the bladder specimen unveiled a non-muscle-invasive bladder tumor (TVNIM), identified as a high-grade invasive urothelial carcinoma per the WHO 2022 and WHO 1973 classifications. Notably, the tumor exhibited diverse characteristics, including surface urothelium ulceration, micro-papillary (5%) and plasmacytic (5%) components, marked cytonuclear atypia, vascular emboli, and a reactive macrophagic response with giant cells. The resected ureteral segments showed no abnormalities, affirming their health status. Lymphadenectomy findings indicated both non-infiltrated and infiltrated ganglia with capsular breach. The urethral limit, cervical, and uterine walls displayed no distinctive histological features, while the annexes revealed no remarkable findings. Overall, the histopathological analysis provided a detailed characterization of the bladder tumor, emphasizing its aggressive nature and confirming the absence of in situ high-grade components.

Concerned about potential residual lesions or other neoplastic stem cells, physicians discussed the possibility of administering four sessions of chemotherapy. A thorough assessment on **October 3, 2023**, revealed an invasive high-grade urothelial carcinoma classified as pT2 N2 with a micro-papillary component estimated at 5%, plasmacytic at 5%, and malpighian at 5%, accompanied by the presence of vascular emboli. The left ilio-obturator lymphadenectomy identified 11 lymph nodes, with 2 displaying infiltration and capsular breach. Ureteral recuts and examination of the uterus and annexes confirmed their health. The clinical evaluation indicated normalcy, with clear urine drainage through the Bricker conduit. A decision from the Onco-urological RCP on **October 23, 2023**, recommended adjuvant chemotherapy. However, considering the patient's age and existing health conditions, especially significant hearing impairment and renal enzyme dysfunction, posing a risk of chronic renal and auditory failure, there were substantial concerns about administering any chemotherapy. Consequently, given the evident organic decline and worsening condition, the medical team opted for a non-interventional approach, acknowledging the patient's deteriorating organic function and overall health status.

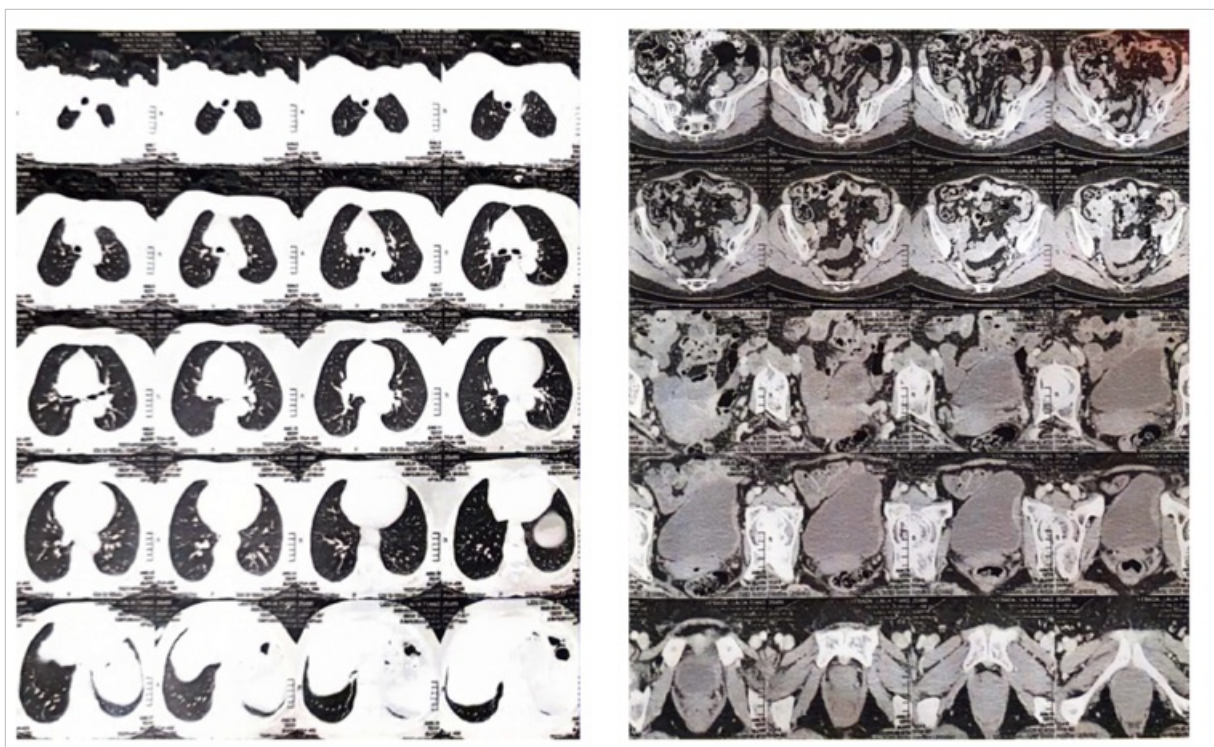
In the period between late **October 2023 and the end of December 2023** symptoms of various organic dysfunctions

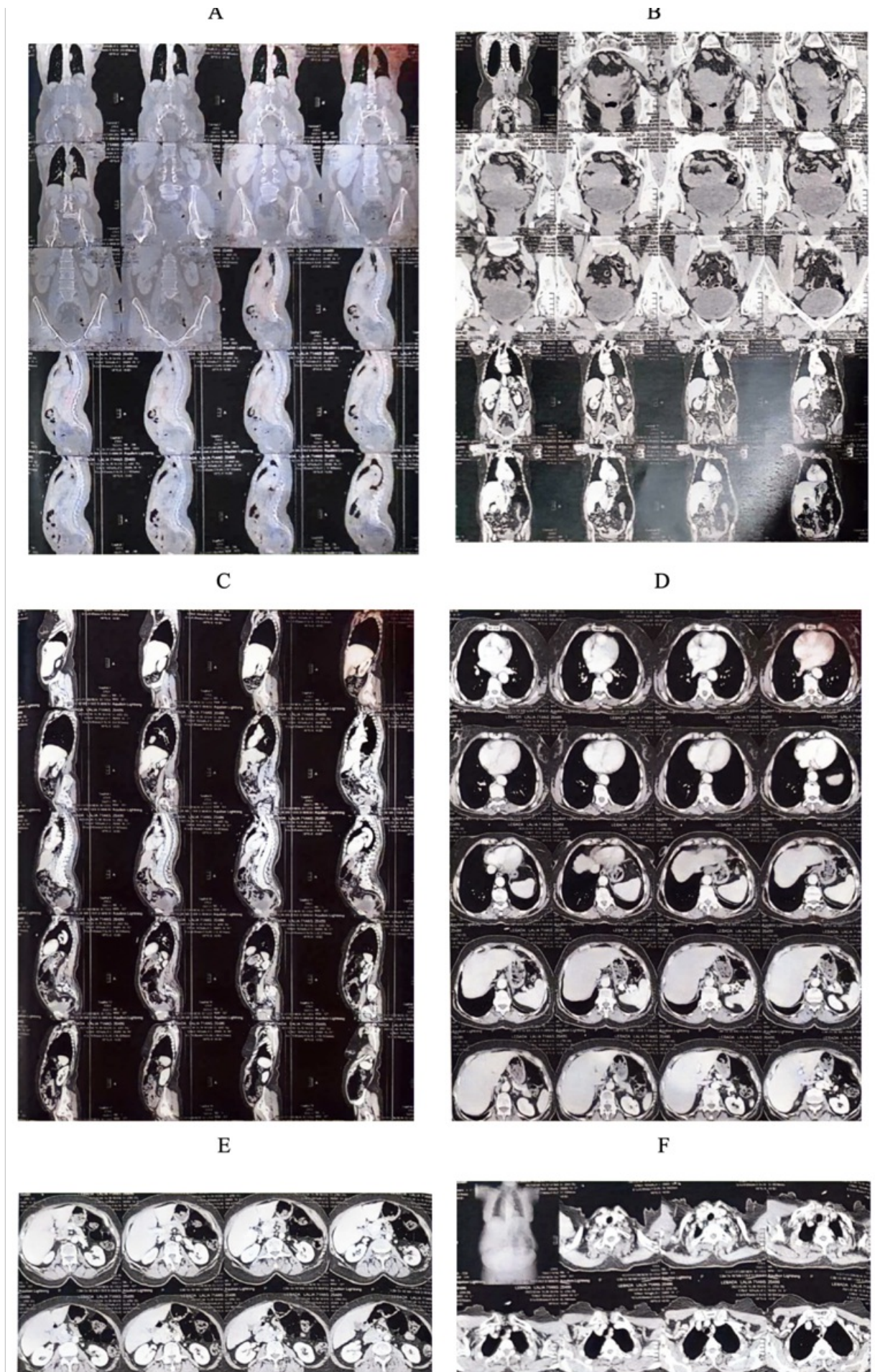
manifested. During this timeframe, a case report explored the impact of a novel therapeutic approach, coined the 'Glucose Mutation Theory,' introduced by Maher Akl. This innovative strategy relies on glucosodiene alkaline particles, aimed at inhibiting glucose breakdown within tumors and adjusting the tumor's pH. The effectiveness of this treatment was documented in a case involving advanced triple-negative breast cancer with bone metastasis at stage three. Following a 20-day regimen of glucosodiene treatment at a daily dose of 100 ml, nearly all active foci disappeared.

Maintaining the same treatment approach for 20 days revealed improvements in vital signs around the fifth day, including reduced pain, enhanced cognition, improved sleep quality, normalized urine color, and restored appetite.

After this therapeutic period, a comprehensive CT scan conducted on **January 29, 2024**, provided detailed insights into the patient's condition. The examination revealed no mediastinal lymphadenopathies and an absence of pleural effusion at the thoracic level. In the abdomino-pelvic region, intact vascular axes were observed, along with nephrostomy tubes indicating moderate dilation of the right excretory cavities and minimal dilation of the left. The liver appeared normal in size with regular contours and homogeneous density and enhancement. Total cystectomy showed no signs of local recurrence, and the upper and lower urinary tracts were undilated. However, a 7mm gallstone was present. Furthermore, the spleen exhibited a calcified aneurysm at its terminal portion of 25x24mm and another at the middle portion of the left renal artery measuring 16x15mm. Additionally, a diffuse atheromatous infiltration was noted in the aorta and iliac branches. In the osseous examination, no suspicious lesions were identified, but arthrosclerotic changes were observed in the spine. In conclusion, the patient demonstrated stability post-total cystectomy without local recurrence.

The presence of nephrostomy tubes indicated moderate dilation on the right and minimal dilation on the left. Stability was also noted in the right parenchymal lung nodule. Importantly, no secondary locations were detectable in the pleura, lungs, liver, lymph nodes, or bones. [Figure 4]





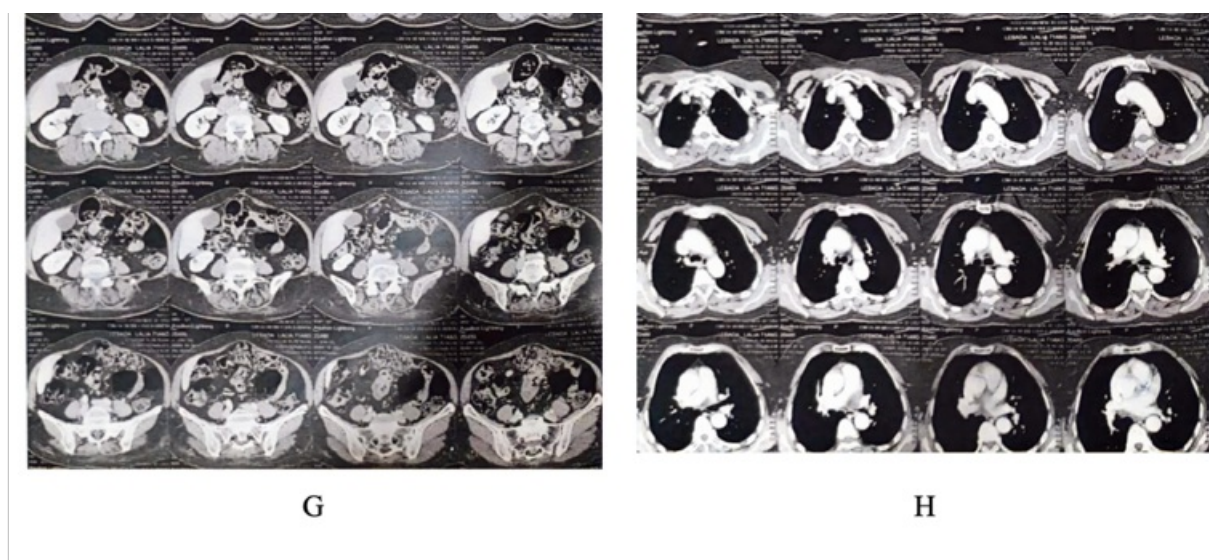


Figure 4. A comprehensive CT scan conducted on January 29, 2024, provided detailed insights into the patient's condition. The examination disclosed the absence of mediastinal lymphadenopathies and pleural effusion at the thoracic level. In the abdomino-pelvic region, intact vascular axes were observed, and nephrostomy tubes indicated moderate dilation of the right excretory cavities and minimal dilation of the left. The liver exhibited normal size with regular contours, homogeneous density, and enhancement. Total cystectomy revealed no local recurrence, and the upper and lower urinary tracts were undilated. However, a 7mm gallstone was present. The spleen displayed a calcified aneurysm at its terminal portion of 25x24mm and another at the middle portion of the left renal artery measuring 16x15mm. Additionally, diffuse atheromatous infiltration was noted in the aorta and iliac branches. Osseous examination revealed no suspicious lesions, but arthrosclerotic changes were observed in the spine. In conclusion, stability post-total cystectomy was demonstrated without local recurrence. The presence of nephrostomy tubes indicated moderate dilation on the right and minimal dilation on the left. Stability was also noted in the right parenchymal lung nodule. Importantly, no secondary locations were detectable in the pleura, lungs, liver, lymph nodes, or Bones.

Discussion

The case involves a 72-year-old patient diagnosed with bladder cancer, opting for a multifaceted therapeutic journey. Bladder cancer, primarily transitional cell carcinoma, poses challenges due to delayed diagnosis, emphasizing the importance of early detection. Chemotherapy, a cornerstone in cancer treatment, encounters complexities, requiring a nuanced approach based on patient-specific factors. In this intricate landscape, Maher Akl's Glucose Mutation Theory introduces Glucosodiene, showcasing promising outcomes in metastatic triple-negative breast cancer. The patient's comprehensive assessment revealed initial positive responses to traditional treatments, including BCG therapy. However, the cancer's aggressive nature necessitated radical cystectomy, leading to favorable postoperative progress. Pathological analysis indicated the potential for adjuvant chemotherapy, a decision weighed against the patient's age and health status. Considering these challenges, the innovative approach of Glucosodiene emerged as a viable alternative, aligning with Akl's theory. Between October and December 2023, as the patient exhibited organic decline, Glucosodiene treatment showcased significant positive impacts. A 20-day regimen resulted in the disappearance of active cancer foci, demonstrating improved vital signs, reduced pain, enhanced cognition, normalized urine color, and restored appetite. A follow-up CT scan in January 2024 confirmed stability post-total cystectomy, highlighting the absence of local recurrence and secondary locations. The effectiveness of Glucosodiene positions it as a valuable therapeutic option, offering hope in

cases where traditional chemotherapy is constrained. In summary, the case underscores the challenges of bladder cancer treatment, the complexities surrounding chemotherapy, and the potential of Glucosodiene as a groundbreaking alternative, showcasing positive outcomes in improving the patient's condition.

Conclusion

In essence, this case study not only contributes to the understanding of bladder cancer complexities but also highlights the potential role of innovative treatments like Glucosodiene in shaping more effective and personalized strategies for cancer management. As we navigate the evolving landscape of oncology, these experiences pave the way for further exploration and refinement of therapeutic modalities, offering renewed hope for patients facing formidable challenges in their journey towards recovery.

Statements and Declarations

Statement of Ethical Approval or Informed Consent for Case Studies

In conducting this case study, adherence to the principles outlined in the Declaration of Helsinki was ensured. The study also met the criteria for care guidelines, and informed consent was obtained from the patient for follow-up, including permission for the publication of all photographs, laboratory findings, and images presented in this report. The trial registration details for Glucosodiene study are as follows: **NCT05957939**.

Acknowledgments

I wish to acknowledge and appreciate the support of my mother and all those who contributed to my efforts during the various stages of this research. It is my sincere hope that my contributions may eventually contribute to the eradication of cancer, a noble cause worth dedicating a lifetime to.

Funding

This research received no specific grant from any funding agency in the public, commercial, or not-for-profit sectors.

Conflict of Interest

The authors declare that there are no conflicts of interest.

References

1. ^Kaseb H, Aeddula NR. *Bladder Cancer*. [Updated 2022 Oct 24]. In: *StatPearls [Internet]*. Treasure Island (FL): StatPearls Publishing; 2024 Jan-. Available from: <https://www.ncbi.nlm.nih.gov/books/NBK536923>.
2. ^Saginala K, Barsouk A, Aluru JS, Rawla P, Padala SA, Barsouk A. *Epidemiology of Bladder Cancer*. *Med Sci (Basel)*. 2020 Mar 13;8(1):15. doi: 10.3390/medsci8010015. PMID: 32183076; PMCID: PMC7151633.
3. ^Mitra AP, Datar RH, Cote RJ. *Molecular pathways in invasive bladder cancer: new insights into mechanisms, progression, and target identification*. *J Clin Oncol*. 2006 Dec 10;24(35):5552-64. doi: 10.1200/JCO.2006.08.2073. PMID: 17158541.
4. ^Inamura K. *Bladder Cancer: New Insights into Its Molecular Pathology*. *Cancers (Basel)*. 2018 Apr 1;10(4):100. doi: 10.3390/cancers10040100. PMID: 29614760; PMCID: PMC5923355.
5. ^Amjad MT, Chidharla A, Kasi A. *Cancer Chemotherapy*. [Updated 2023 Feb 27]. In: *StatPearls [Internet]*. Treasure Island (FL): StatPearls Publishing; 2024 Jan-. Available from: <https://www.ncbi.nlm.nih.gov/books/NBK564367>.
6. ^Anand U, Dey A, Chandel AKS, Sanyal R, Mishra A, Pandey DK, De Falco V, Upadhyay A, Kandimalla R, Chaudhary A, Dhanjal JK, Dewanjee S, Vallamkondu J, Pérez de la Lastra JM. *Cancer chemotherapy and beyond: Current status, drug candidates, associated risks and progress in targeted therapeutics*. *Genes Dis*. 2022 Mar 18;10(4):1367-1401. doi: 10.1016/j.gendis.2022.02.007. PMID: 37397557; PMCID: PMC10310991.
7. ^Gehdoo RP. *Anticancer Chemotherapy and its Anaesthetic Implications (Current Concepts)*. *Indian J Anaesth*. 2009 Feb;53(1):18-29. PMID: 20640073; PMCID: PMC2900029.
8. ^O'Brien K, Ried K, Binjemain T, Sali A. *Integrative Approaches to the Treatment of Cancer*. *Cancers (Basel)*. 2022 Nov 30;14(23):5933. doi: 10.3390/cancers14235933. PMID: 36497414; PMCID: PMC9740147.
9. ^Maher Akl, Amr Ahmed. (2024). *Developing the Theory of Toxic Chemotherapeutic Nutrition for Cancer Cells and Targeting Tumors via Glucose Mutation: Medical Guidance and Integrated Therapeutic Approach*. Qeios. doi:10.32388/EBCKFO.4.
10. ^Ahmed, A. (2023). *Targeting the warburg effect with glucosodiene: a case report of a 43-year-old female after mastectomy of the right breast and axillary clearance with successful first case treatment for metastatic Triple Negative Breast Cancer (TNBC) of bone*. *Oncology and Radiotherapy*, 17(10), 751-757.
11. ^Herr HW, Schwalb DM, Zhang ZF, Sogani PC, Fair WR, Whitmore WF Jr, Oettgen HF. *Intravesical bacillus Calmette-Guérin therapy prevents tumor progression and death from superficial bladder cancer: ten-year follow-up of a prospective randomized trial*. *J Clin Oncol*. 1995 Jun;13(6):1404-8. doi: 10.1200/JCO.1995.13.6.1404. PMID: 7751885.
12. ^Grabe-Heyne K, Henne C, Mariappan P, Geiges G, Pöhlmann J, Pollock RF. *Intermediate and high-risk non-muscle-invasive bladder cancer: an overview of epidemiology, burden, and unmet needs*. *Front Oncol*. 2023 Jun 2;13:1170124. doi: 10.3389/fonc.2023.1170124. PMID: 37333804; PMCID: PMC10272547.