

[Open Peer Review on Qeios](#)

# A Villain in Disguise in the Management of Painful Peripheral Neuropathy: A Case Report

Prateek Upadhyay<sup>1</sup>, Sukanya Mitra<sup>1</sup>, Prashant Ahlawat<sup>1</sup>

<sup>1</sup> Government Medical College and Hospital

**Funding:** No specific funding was received for this work.

**Potential competing interests:** No potential competing interests to declare.

## Abstract

Tuberculosis is widely prevalent in India and the patients often require holistic management of the disease, the related complications, adverse effects of treatment, and long-term sequelae. We present here a case of a 17-year-old male who presented with painful peripheral neuropathy to the pain clinic with excruciating pain. A thorough history, clinical examination, work-up, and treatment resulted in the alleviation of the patient's pain over 6 weeks. We aim to bring into notice the under-reported role of Cycloserine in addition to Linezolid as inciting agent in peripheral neuropathy, necessary alterations, and advocate for a holistic approach in pain clinics.

Dr. **Prateek Upadhyay** MD<sup>1</sup>, Dr. **Sukanya Mitra** MD<sup>1,\*</sup>, Dr. **Prashant Ahlawat** MBBS<sup>2</sup>

<sup>1</sup> Department of Anaesthesia and Intensive Care, Government Medical College and Hospital, Chandigarh

<sup>2</sup> Department of General Medicine, Government Medical College and Hospital, Chandigarh

### \*Correspondence to:

*Dr. Sukanya Mitra*

*Professor and Head*

*Department of Anaesthesia and Intensive Care*

*Government Medical College and Hospital, Sector 32, Chandigarh, 160030, India*

*Phone: 91-9646121521*

*E-mail: [drsmitra12@yahoo.com](mailto:drsmitra12@yahoo.com)*

## Role of authors

- Dr. Prateek Upadhyay: This author evaluated the case, followed up with the patient, and created the draft of the manuscript.
- Dr. Sukanya Mitra: This author supervised the case, and reviewed and edited the draft.
- Dr. Prashant Ahlawat: This author helped in the physical examination and review of the literature.

**Running title:** Painful peripheral neuropathy management

**Keywords:** peripheral neuropathy, tuberculosis, linezolid, cycloserine, pain medicine, antitubercular, neuropathy, neuritis.

Glossary of Terms		
<b>TB</b>	:	Tuberculosis
<b>DSP</b>	:	Distal sensory polyneuropathy
<b>PTB</b>	:	Pulmonary tuberculosis
<b>MDR</b>	:	Multi-drug resistant
<b>ATT</b>	:	Anti-tubercular treatment
<b>Tab.</b>	:	Tablet
<b>VCPS</b>	:	Verbal categorical pain score
<b>HIV</b>	:	Human immunodeficiency virus
<b>OPD</b>	:	Outpatient department

## Introduction

Peripheral neuropathies refer to a wide-ranging set of peripheral nervous system disorders with diverse patterns with the commonest being distal sensory polyneuropathy (DSP). It is characterized by “length-dependent peripheral nerve injury resulting in distal predominant sensory loss, pain, and severe weakness” [1]. It is commonly indicted for complicating the disease and impeding the treatment of tuberculosis (TB). The etiology is multifactorial. A detailed history and workup are required for the management of such patients. We present here a case of painful peripheral neuropathy incited by anti-tubercular drugs and their management, highlighting the importance of timely and holistic management.

Written informed consent was obtained from the patient for publication.

## Case report

A 17-year-old male, a known case of multidrug-resistant pulmonary tuberculosis (MDR-PTB) presented to the pain clinic with severe burning pain in his lower limbs, severe enough to disturb his sleep and a Verbal Categorical Pain Scale (VCPS) rating of 10 on a scale of 0 to 10. It was associated with difficulty in walking. He could walk only with the support and his slippers often fell out involuntarily while trying to walk.

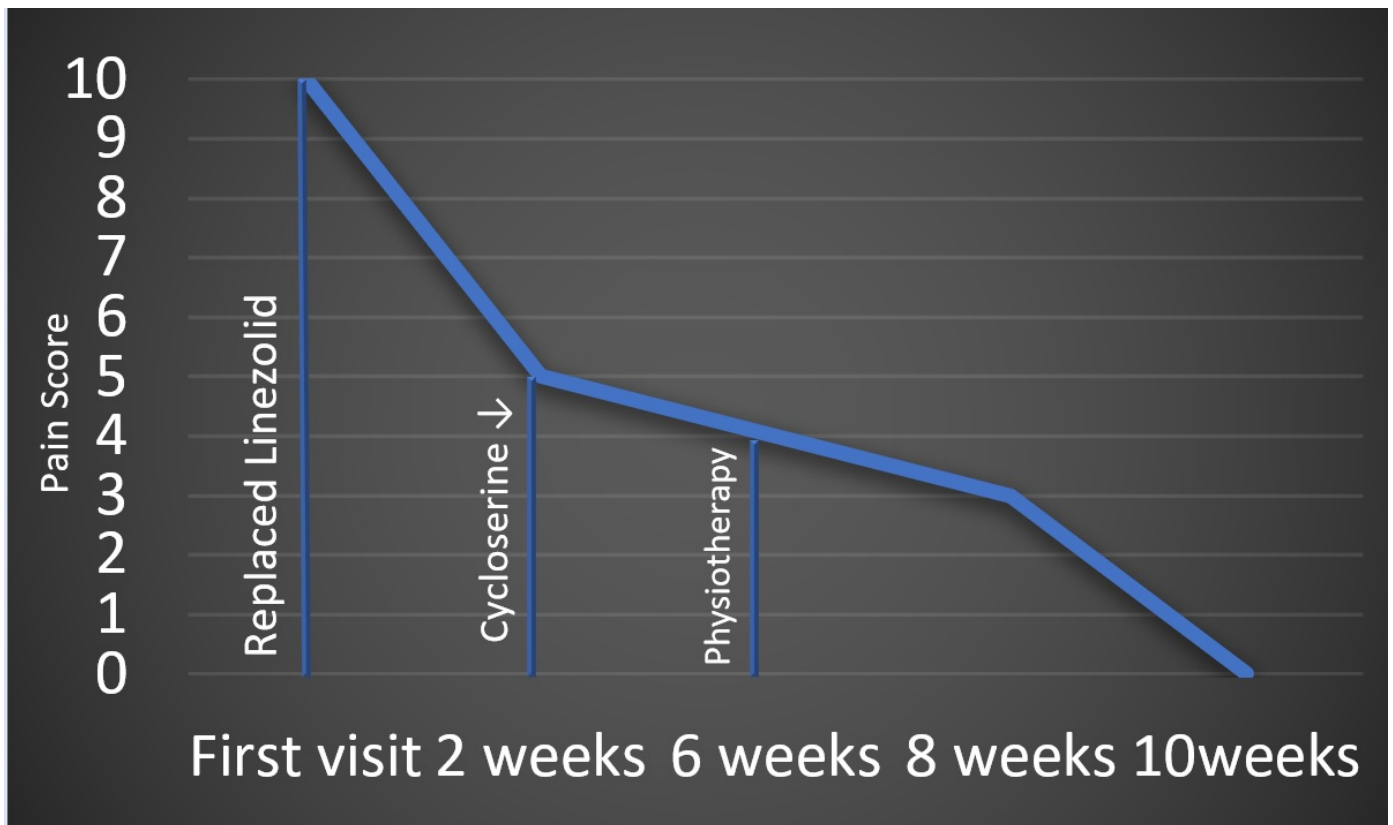
Background: History dates back to four months when he presented with the chief concerns of cough with expectoration and fever for 15 days and was diagnosed with MDR-PTB (with Rifampicin resistance). The patient was started on an oral longer MDR Regimen of Anti-tubercular treatment (ATT). He was offered a shorter treatment regimen with Kanamycin, but

he and his parents refused to be started on Kanamycin because of daily injections and the possibility of hearing impairment. After two months, he presented with a complaint of joint pain involving large joints with pain over bilateral lower limbs and was managed conservatively by the pulmonologist. After a month, he complained of persistent and increasing pain in bilateral lower limbs, fatigue, and numbness of bilateral lower limbs. A Nerve conduction study was performed, and bilateral sensory neuropathy was observed. After a month, the patient still had persistent bilateral lower limb pain and was referred to the pain clinic.

**Management:** On presentation to the pain clinic, he was receiving all-oral longer anti-tubercular treatment (ATT) regimen drugs i.e., Tab. Bedaquiline 200 mg once daily (three times a week), Tab. Levofloxacin 750 mg once daily, Tab. Linezolid 300 mg once daily, Tab. Clofazimine 100 mg once daily and Tab. Cycloserine 750 mg once daily along with Tab. Pyridoxine 100 mg before bed for four months. Linezolid-induced peripheral neuropathy was suspected, and it was replaced with Tab. Delamanid 100 mg twice daily. Oral pregabalin 50 mg once daily and amitriptyline 10 mg before bed were started.

After two weeks, the burning pain in the sole decreased but difficulty in walking persisted (VCPS 5). Pregabalin was increased to 50 mg twice daily and mecobalamin was added. ATT was advised to be modified in suspicion of Cycloserine induced neuritis. It could not be stopped in view of the lack of alternative drugs with better adverse effect profiles, but the dose was reduced from 750 mg once daily to 500 mg once daily. Vitamins B1 and B12 were added.

After six weeks, his burning pain in the sole and continuous pain in his legs decreased, he could hold slippers and his gait improved. He was advised rigorous physiotherapy: Joint compressions for bilateral lower limbs, bridging exercises, pounding exercises, sensory integration therapy, rubbing of the skin with different texture clothing, and contrast bath for bilateral feet. Now, he could hold slippers and his gait improved. Gradually, he could walk without support and his pain score plummeted to zero. He continues medication, and physiotherapy and visits the pain clinic every two weeks. Table 1 summarizes the clinical examination findings and Figure 1 shows the pain score of the patient over time.



**Figure 1.** Pain score of the patient during the course of treatment.

**Table 1.** Clinical examination on presentation (before) and after 8 weeks (after). DTR: Deep tendon reflex.

	Before	After
<b>Motor Power: Foot [Ankle]</b>	0/5	3/5
<b>Motor Power: Legs [Knee]</b>	2/5	4/5
<b>Pain sensation</b>	Exaggerated	Present
<b>Crude Touch</b>	Present	Present
<b>Fine touch</b>	Absent	Absent
<b>Temperature</b>	Present	Present
<b>Deep Tendon Reflexes (DTR)</b>	Diminished	Diminished
<b>Numbness</b>	Present	Present
<b>Weakness</b>	Present	Improved
<b>DTR Knee</b>	0/3	2/3
<b>DTR Plantar</b>	0/3	1/3

## Discussion

Painful peripheral neuropathy is commonly observed among patients with tuberculosis (TB). In a comparative study, the prevalence of peripheral neuropathy was found to be 13% in a cohort of MDR-TB patients which indicated that diagnosis

of peripheral neuropathy can reasonably be made on clinical presentation alone and management is possible without compromising the treatment of TB itself [2]. Peripheral neuropathy in tuberculosis occurs due to multiple reasons including the disease itself, co-morbid conditions, substance abuse, malnutrition, and an adverse effect of treatment [3]. More recently, it has been related to radiculopathy because of tuberculous meningitis [4]. It's prudent to consider that all known cases of tuberculosis need to be screened in view of the early detection of peripheral neuropathy [3].

Anti-tubercular drugs with peripheral neuropathy occurring as an adverse effect include Isoniazid, Ethambutol, Linezolid, Cycloserine, Fluoroquinolones, Ethionamide, and para-aminosalicylic acid [2][5]. However, the risk of developing peripheral neuropathy should be balanced against the damage that MDR TB causes if not treated befittingly. On the other hand, the reported irreversibility of peripheral neuropathy secondary to anti-tubercular treatment necessitates vigilant screening as a stitch in time saves nine in such patients [6]. Also, it is to be noted that it's unfair to establish in whole and sole that it is iatrogenic. The possibility of a primary effect on the nerves should not be ignored.

In this case, Linezolid and Cycloserine were suspected to be villains in disguise. Peripheral neuropathy commonly occurs with Linezolid. It's commoner to occur at a dose of more than 600 mg per day. Symptomatic relief is observed when the dosage is reduced to 300 mg per day [7][8][9]. However, Linezolid-associated peripheral neuropathy is dreadfully painful and tends to be non-reversible. It is attributed to the disruption of mitochondrial function [9]. Most patients being treated with linezolid receive pyridoxine as part of the standard of care. Cycloserine is another offender that usually escapes attention. Cycloserine-induced peripheral neuropathy is related. If the disorder is not being controlled, decreasing the dose of Cycloserine needs to be done. Rarely, medication may be discontinued because of the non-availability of better alternatives and MDR treatment regimen compromise.

The basic management of PN in patients with tuberculosis must follow a 2-phased approach [9][10]. Phase 1 includes prevention which involves: (i) management of underlying disease (s)- TB, diabetes, HIV infection, etc.; (ii) avoidance of substance abuse; (iii) drug dose adjustments: without bargaining the TB treatment regimen. If not possible then emphasize preserving functioning and symptomatic relief through rigorous physiotherapy; (iv) preserving functioning; and (v) pyridoxine supplementation. Phase 2 involves treatment. This involves (i) termination of the possible offending agent; (ii) vitamin supplementation to counter the deficiencies and supplementation for those with dietary compromise; (iii) rigorous physical therapy; (iv) pain relief; (v) bio-psycho-social support; and (vi) pharmacotherapy: tricyclic antidepressants (amitriptyline), selective serotonin reuptake inhibitors (Fluoxetine. Paroxetine), serotonin noradrenaline reuptake inhibitors (duloxetine and milnacipran) and gabapentin or pregabalin.

We still have a long way to go in managing TB and its complications. More research is required to formulate a treatment protocol. With this case, we aim to bring about the complexities in pain OPD management of such patients to help them and provide better health and quality of life for survivors of TB.

To conclude, the management of painful peripheral neuropathy in pain OPD requires a holistic timely approach. In this case, stopping Linezolid and reducing the dose of Cycloserine resulted in a marked reduction in pain which implies their often-unheeded share in the pathogenesis of peripheral neuropathy in TB patients. This, in conjugation with vitamin

supplementation, rigorous physiotherapy, and frequent follow-ups resulted in a good outcome for the patient.

## Declarations

- We declare no potential sources of conflicts of interest and no financial disclosures.
- Published with the written consent of the patient.
- This manuscript ensures adherence to the ACRE checklist.

## References

1. <sup>^</sup>Barrell K, Smith AG. *Peripheral Neuropathy*. *Med Clin North Am*. 2019; 103: 383-97.
2. <sup>a, b</sup>Shin SS, Hyson AM, Castañeda C, et al. *Peripheral neuropathy associated with treatment for multidrug-resistant tuberculosis*. *Int J Tuberc Lung Dis*. 2003;7:347-53.
3. <sup>a, b</sup>Blain PG, Lane RJ. *Neurological disorders*. In: Davies DM, Ferner RE, de Glanville H, eds. *Davies's Textbook of Adverse Drug Reactions*, 5th ed. London, UK: Chapman and Hall Medical, 1998. 585-629.
4. <sup>^</sup>Orrell RW, King RH, Bowler JV, Ginsberg L. *Peripheral nerve granuloma in a patient with tuberculosis*. *J Neurol Neurosurg Psychiatry*. 2002;73:769-71. doi: 10.1136/jnnp.73.6.769.
5. <sup>^</sup>Vilholm OJ, Christensen AA, Zedan AH, Itani M. *Drug-induced peripheral neuropathy*. *Basic Clin Pharmacol Toxicol*. 2014;115:185-92. doi: 10.1111/bcpt.12261.
6. <sup>^</sup>Saroha D, Garg D, Singh AK, Dhamija RK. *Irreversible neuropathy in extremely-drug resistant tuberculosis: An unfortunate clinical conundrum*. *Indian J Tuberc*. 2020;67:389-92. doi: 10.1016/j.ijtb.2019.11.012.
7. <sup>^</sup>Roongruangpitayakul C, Chuchottaworn C. *Outcomes of MDR/XDR-TB patients treated with linezolid: experience in Thailand*. *J Med Assoc Thai*. 2013;96:1273-82.
8. <sup>^</sup>Koh WJ, Kang YR, Jeon K, et al. *Daily 300 mg dose of linezolid for multidrug-resistant and extensively drug-resistant tuberculosis: updated analysis of 51 patients*. *J Antimicrob Chemother*. 2012;67:1503-7. doi: 10.1093/jac/dks078.
9. <sup>a, b, c</sup>Mafukidze AT, Calnan M, Furin J. *Peripheral neuropathy in persons with tuberculosis*. *J Clin Tuberc Other Mycobact Dis*. 2015;2:5-11. doi: 10.1016/j.jctube.2015.11.002.
10. <sup>^</sup>Hershman DL, Lacchetti C, Dworkin RH, et al. *Prevention and management of chemotherapy-induced peripheral neuropathy in survivors of adult cancers: American Society of Clinical Oncology clinical practice guideline*. *J Clin Oncol*. 2014;32:1941-67. doi: 10.1200/JCO.2013.54.0914.