

[Open Peer Review on Qeios](#)

Retinal Vasculitis Following COVID-19 Infection: A Systematic Review

Salil Mehta¹

¹ Lilavati Hospital & Research Centre

Funding: No specific funding was received for this work.

Potential competing interests: No potential competing interests to declare.

Abstract

Purpose: We conducted a systematic review of literature to identify cases of vasculitis following corona-virus disease (COVID-19) infection and analyse their specific systemic and ocular features.

Methods: We used the key-words “retina” AND “vasculitis” AND vessels” AND COVID-19 to identify potential papers. We analysed case series, and case reports.

Results: 10 papers that describing 12 patients contained enough data to permit analysis and these were included in the study. There were seven female (58.3%) and five male patients (41.6%) with ages ranging from 11 to 66 (mean 42.6 years). Time from onset of the vasculitis following COVID-19 infection varied from three to 150 days (mean 41.0 days). Clinical findings were described in 15 of the 24 eyes of these 12 patients (62.5%) and included anterior uveitis; optic neuropathies; retinal infiltrates and clinical and unilateral or bilateral retinal vasculitis.

Conclusions: Patients with retinal vasculitis appear to constitute a distinct subset and may require different treatment protocols.

Dr. Salil Mehta MS DNB FRCS (Glasg)*

Department of Ophthalmology, Lilavati Hospital and Research Centre, Mumbai, India

*Corresponding Author:

Salil Mehta MS, DNB, FRCS (Glasg)

Department of Ophthalmology,

Lilavati Hospital and Research Center,

Bandra Reclamation, Bandra, Mumbai, India.

Email: drsalilmehta@gmail.com

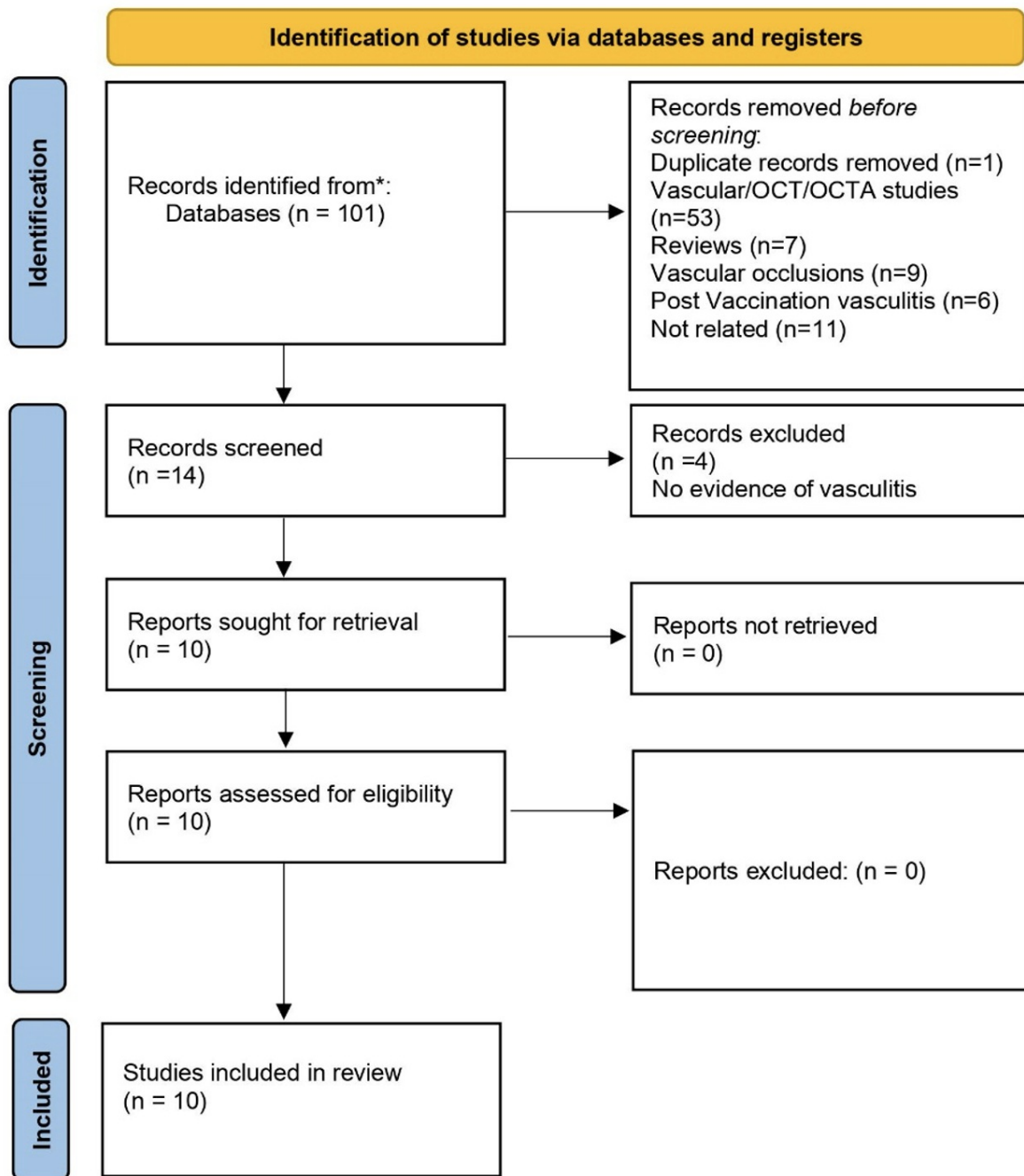
Introduction

COVID-19 due to severe acute respiratory syndrome coronavirus 2 (SARS-CoV-2) infection, has had significant systemic and ocular implications globally. COVID-19 infection has been associated with both a prothrombotic state and a hyperinflammatory state and the systemic implications include the vascular system of the eye. Numerous retinal and retinal vascular lesions have been reported including hemorrhages, cotton wool spots, arterial and venous occlusions, and vasculitis. We suggest that patients with vasculitis may constitute a distinct subset of patients as compared to patients with vascular occlusion such retinal arterial or venous occlusion. We conducted a systematic review of literature to identify cases of vasculitis following COVID-19 infection and analyse their specific systemic and ocular features.

Methods

We conducted a systematic review to identify and analyze cases of retinal vasculitis following COVID-19 infection using the Pubmed database (www.pubmed.gov) for English language articles. This search was performed on 14/5/2023. We used the key-words “retina” AND “vasculitis” AND Vessels” AND COVID-19 to identify potential papers. We analysed case series, and case reports but excluded reviews, editorials, and non-relevant papers. Demographic findings, systemic features, and ocular lesions detected were entered into a Microsoft Excel sheet.

A total of 101 results were identified. Duplicates were excluded (n=1) as were papers that primarily dealt with OCT/OCTA findings (n=53), literature reviews (n=7), vasculitis following COVID-19 vaccination (n=6), vascular occlusions (n=9) or were unrelated (n=15). The PRISMA flowchart is shown in Figure 1.



The PRISMA flowchart of this study

Results

10 papers that describing 12 patients contained enough data to permit analysis and these were included in the study [\[1\]\[2\]\[3\]\[4\]\[5\]\[6\]\[7\]\[8\]\[9\]\[10\]](#). There were seven female (58.3%) and five male patients (41.6%) with ages ranging from 11 to 66 (mean 42.6 years). Countries of origin included India (three patients, 25%); Turkey (two patients, 16.6%); Switzerland (three patients, 25%); Spain (one patient, 8.3%); Malaysia (one patient, 8.3%); USA (one patient, 8.3%) and France (one patient, 8.3%). Time from onset of the vasculitis following COVID-19 infection varied from three to 150 days (mean 41.0 days).

Systemic investigations commonly included MRI of the brain; infectious disease panels to determine other potential causes of vasculitis (seven patients; all negative results) ^{[1][3][4][5][6][7][9]}; autoimmune disease investigations (largely ANA/ANCA/Anti Ds DNA; seven patients; all negative results) ^{[2][3][5][8][9][10]} and chest imaging (x-ray or CT chest).

Clinical findings were described in 15 of the 24 eyes of these 12 patients (62.5%) and included anterior uveitis (three eyes, 12.5%) ^{[1][6]}; optic neuropathies (papillophlebitis/edema/optic neuritis: two eyes, 8.3%) ^[6,7]; retinal infiltrates (five eyes, 20.8%) ^{[1][3][5]} and clinical and in most cases, angiographic evidence of unilateral or bilateral retinal vasculitis (15 eyes (62.5%) ^{[1][2][3][5][6][8][10]}; two described as frosted branch angiitis (8.3%)) ^{[4][7]}. Visual acuities ranged from 20/20 to CFCF.

Virtually all patients (12 patients) underwent fundus photography, OCT and FFA which led to the primary diagnosis. Periocular or systemic steroids were the commonest treatment modality (six patients, 50%) ^{[1][2][3][6][7][9]} followed by antivirals (one patient, 8.3%) ^[4] and anticoagulants (one patient, 8.3%) ^[8]. No treatment protocols had been described for the remaining patients. seven patients (58.3%) had stable visual outcomes ^{[4][6][7][8][10]} whereas five (41.6%) had a full recovery ^{[1][2][3][5][9]}.

The salient findings of these patients are summarized in Table 1.

Table 1. Shows the salient clinical and ocular findings of studied patients

No	Primary Author	Age/Sex	RE findings	LE findings	Vision	Treatment	Time to Onset
1	Yalcinsoy ^[1]	46/F	Anterior Uveitis, Superficial retinal infiltrates, retinal periphlebitis	Anterior Uveitis, Superficial retinal infiltrates, retinal periphlebitis	6/7.5 (BE)	Steroids	14
2	Mehta ^[2]	56/F	Vasculitis	Normal	6/6 (BE)	Steroids	NA
3	Erdem ^[3]	37/M	vasculitis/retinal hyperreflective lesions	normal	6/30 (RE) 6/6 (LE)	Steroids	30
4	Lim ^[4]	33/M	FBA vitritis	Normal	6/60 (RE) 6/7.5 (LE)	ART Gancyclovir	30
5	Quintana-Castenedo ^[5]	11/M	Normal	retinal vasculitis, perivascular infiltrates, retinal exudates	6/6 (BE)	Nil	NA
6	Francois ^[6]	Late 50s/F	Anterior Uveitis, Vitritis, retinal vasculitis/optic neuropathy	Normal	HM (RE) 6/6 (LE)	Steroids	NA
7	Hanson ^[7]	34/F	Normal	FBA, optic disc edema, retinal hemorrhages, retinal whitening	6/9 (RE) CFCF(LE)	Steroids	3
8	Chandrasekhara ^[8]	66/M	Panuveitis, Vasculitis, CRAO	Panuveitis, vasculitis	NA	NA	NA
9	Sheth ^[9]	52/M	Normal	Hemi RVO	6/6 (RE) 6/60 (LE)	steroids	10
10	Tsiropoulos ^[10] (A)	44/F	Peripheral vasculitis	Peripheral vasculitis	6/6 (RE) 6/7.5 (LE)	NA	150
	(B)	45/f	normal	Peripheral vasculitis	6/6 (BE)	NA	28
	(C)	38/F	normal	Peripheral vasculitis	6/6 (BE)	NA	30

Legends: FBA: Frosted Branch Angiitis; RVO: retinal vein occlusion; CRAO; central retinal arterial occlusion, ART: antiretroviral treatment.

Discussion

COVID-19 is an infection caused by SARS-CoV 2 that can involve a wide range of organs especially the vascular system. Endothelial cell inflammation is common and occurs in association with arterioles, veins and capillaries thus leading to tissue hypoperfusion and consequent injury. COVID-19 infection may thus be associated with several different types of systemic vasculitis. Wong and co-authors, in a systematic review, were able to identify leukocytoclastic vasculitis (LCV), IgA vasculitis, and Kawasaki disease like vasculitis in patients with COVID-19 infection. They described the endothelial inflammation, apoptosis, and dysfunction that commonly occurs as potential causative mechanisms. Kawasaki disease (KD), a medium vessel vasculitis, is an acute inflammation that largely affects the coronary arteries of children younger than 5 years of age. SARS-CoV-2 infection may potentially cause inflammation within the endothelium triggering the development of KD. IgA Vasculitis is a small-vessel vasculitis that is caused by immune-complexes deposits containing IgA and are thought to occur following an upper respiratory tract infection of SARS-CoV-2 and the subsequent upregulation of IL-6. The cytokine storm frequently associated with SARS-COV-2 infection may have a causative role as well. Leukocytoclastic vasculitis (LCV) is a small vessel vasculitis characterized by immune complex-mediated inflammation of skin capillaries usually linked to a rise in IL6 levels [\[11\]](#).

Increasingly many studies and case reports have described the retinal vascular lesions associated with COVID-19. D' Alessandro conducted a systematic review of vascular retinal manifestations and described the cumulative findings of 21 studies. The review described a range of findings that ranged from cotton wool spots, hemorrhages to retinal artery and vein occlusions [\[12\]](#).

With an emphasis on retinal vascular occlusions, Yeo and co-workers conducted a systematic review and analysed the prevalence and clinical findings in such patients. They were able to identify 13 cases of retinal artery occlusion (RAO) and 14 cases of retinal vein occlusion (RVO) from COVID -19 recovered with 50% of both groups lacking any other potentially contributory systemic illness. The authors note that COVID-19 per se is associated with thrombosis possibly via endothelial injury and vessel wall inflammatory reactions. Additional factors include hypercoagulability and platelet activation. They noted that most cases of arterial occlusion present with abnormal coagulation markers likely due to the overwhelming systemic inflammation whereas patients with retinal vascular occlusion may, in addition, also possess local pathogenic factors such arteriovenous crossing pathology or localised vasospasm. The authors did not describe signs of intraocular inflammation in any of these patients [\[13\]](#).

Similar findings have also been reported following COVID-19 vaccination. Li et al, in their case series, have described the occurrence of intraocular inflammation following vaccination. 1 case of frosted branch angiitis was observed in this series. They have postulated that molecular mimicry due to an antigenic similarity between vaccine derived proteins and uveal peptides may play a causative role [\[14\]](#). Bolletta et al described the lesions of 34 patients and reported the presence of two cases of retinal vasculitis. They suggest that an increase in IFN-I secretion may potentially cause or exacerbate autoimmune phenomenon [\[15\]](#).

We describe the findings of 12 patients with retinal vasculitis following COVID-19 infection. This group of patients appears

to be distinct from the group that presents with retinal vascular occlusion such as RAO/RVO as suggested by the frequent association with other signs of intraocular inflammation such as anterior uveitis or vitritis and a good response to steroids with almost all patients maintaining vision or recovering vision. Potential causative mechanisms include the presence of a prothrombotic state due to endothelial injury or inflammation. The naturally occurring antithrombotic activity of the endothelium may be lost due to direct viral infection or the resultant inflammation [16]. Immune system dysregulation with a subsequent cytokine storm with the production of TNF-alpha and IL-6 may also contribute to the vessel wall inflammation and thrombosis. We suggest that while multiple pathogenic mechanisms appear to cause retinal vascular pathology and may exist simultaneously, this may cause a clinical spectrum of disease. Patients with a predominantly inflammatory reaction may present with a vasculitic picture whereas those with a predominantly prothrombotic reaction may present as a vascular occlusion with minimal signs of intraocular inflammation. This group of patients may benefit from primary steroid treatment as opposed to anticoagulant treatment as described for vascular occlusions.

The authors report no conflict of interest.

References

1. [a, b, c, d, e, f, g, h](#) Ozdemir Yalcinsoy K, Ozdamar Erol Y, Ozdal PC. *Bilateral Granulomatous Panuveitis in A Patient with COVID-19. Ocul Immunol Inflamm.* 2022 Apr 29;1-4. doi: 10.1080/09273948.2022.2061523.
2. [a, b, c, d, e, f](#) Mehta S, Gill N. *Retinal Vasculitis in a Patient with Mixed Connective Tissue Disease Following COVID-19 Infection: Correlation or Coincidence? Cureus.* 2022 Jun 27;14(6): e26365. doi: 10.7759/cureus.26365.
3. [a, b, c, d, e, f, g, h](#) Erdem S, Karahan M, Dursun ME, Ava S, Hazar L, Katran I, et al. *Retinal Vasculitis Case Developing in the Early Period after COVID-19. Klin Monbl Augenheilkd.* 2022 Sep;239(9):1132-1133. English. doi: 10.1055/a-1363-1326. Epub 2021 Apr 14.
4. [a, b, c, d, e, f](#) Lim TH, Wai YZ, Chong JC. *Unilateral frosted branch angiitis in an human immunodeficiency virus-infected patient with concurrent COVID-19 infection: a case report. J Med Case Rep.* 2021 May 12;15(1):267. doi: 10.1186/s13256-021-02826-1.
5. [a, b, c, d, e, f, g](#) Quintana-Castanedo L, Feito-Rodríguez M, Fernández-Alcalde C, Granados-Fernández M, Montero-Vega D, Mayor-Ibarguren A, et al. *Concurrent chilblains and retinal vasculitis in a child with COVID-19. J Eur Acad Dermatol Venereol.* 2020 Dec;34(12):e764-e766. doi: 10.1111/jdv.16801. Epub 2020 Jul 30.
6. [a, b, c, d, e, f, g](#) François J, Collery AS, Hayek G, Sot M, Zaidi M, Lhuillier L, et al. *Coronavirus Disease 2019-Associated Ocular Neuropathy with Panuveitis: A Case Report. JAMA Ophthalmol.* 2021 Feb 1;139(2):247-249. doi: 10.1001/jamaophthalmol.2020.5695.
7. [a, b, c, d, e, f](#) Hanson J, Dillon AB, Budoff G, Oh AJ, Goodyear K, Lorenzo M, et al. *Frosted Branch Angiitis in the Setting of Active COVID-19 Infection and Underlying Mixed Connective Tissue Disease. Cureus.* 2023 Mar 28;15(3):e36819. doi: 10.7759/cureus.36819.
8. [a, b, c, d, e, f](#) Chandrashekara S, Jaladhar P, Paramshetti S, Ramachandran V, Nizar SF, Kori D. *Post COVID*

- Inflammation Syndrome: Different Manifestations Caused by the Virus. J Assoc Physicians India. 2020 Dec;68(12):33-34.*
9. ^{a, b, c, d, e, f}Sheth JU, Narayanan R, Goyal J, Goyal V. Retinal vein occlusion in COVID-19: A novel entity. *Indian J Ophthalmol.* 2020 Oct;68(10):2291-2293. doi: 10.4103/ijo.IJO_2380_20.
 10. ^{a, b, c, d, e}Tsiropoulos GN, Castro DG, Ambresin A. Six Cases of Retinal Vascular Anomalies after Coronavirus Disease 2019: A Case Series. *Klin Monbl Augenheilkd.* 2022 Apr;239(4):537-544. English. doi: 10.1055/a-1771-5695. Epub 2022 Apr 26.
 11. [^]Wong K, Farooq Alam Shah MU, Khurshid M, Ullah I, Tahir MJ, Yousaf Z. COVID-19 associated vasculitis: A systematic review of case reports and case series. *Ann Med Surg (Lond).* 2022 Feb; 74:103249. doi: 10.1016/j.amsu.2022.103249. Epub 2022 Jan 13.
 12. [^]D'Alessandro E, Kawasaki A, Eandi CM. Pathogenesis of Vascular Retinal Manifestations in COVID-19 Patients: A Review. *Biomedicines.* 2022 Oct 26;10(11):2710. doi: 10.3390/biomedicines10112710.
 13. [^]Yeo S, Kim H, Lee J, Yi J, Chung YR. Retinal vascular occlusions in COVID-19 infection and vaccination: a literature review. *Graefes Arch Clin Exp Ophthalmol.* 2023 Jan 4:1–16. doi: 10.1007/s00417-022-05953-7. Epub ahead of print.
 14. [^]Li S, Ho M, Mak A, Lai F, Brelen M, Chong K, et al. Intraocular inflammation following COVID-19 vaccination: the clinical presentations. *Int Ophthalmol.* 2023 Mar 31:1–11. doi: 10.1007/s10792-023-02684-4.
 15. [^]Bolletta E, Iannetta D, Mastrofilippo V, De Simone L, Gozzi F, Croci S, et al. Uveitis and Other Ocular Complications Following COVID-19 Vaccination. *J Clin Med.* 2021 Dec 19;10(24):5960. doi: 10.3390/jcm10245960.
 16. [^]Reinhold A, Tzankov A, Matter MS, Mihic-Probst D, Scholl HPN, Meyer P. Ocular Pathology and Occasionally Detectable Intraocular Severe Acute Respiratory Syndrome Coronavirus-2 RNA in Five Fatal Coronavirus Disease-19 Cases. *Ophthalmic Res.* 2021;64(5):785-792. doi: 10.1159/000514573.