

[Open Peer Review on Qeios](#)

Primary Surgical Treatment of Cleft Palates in the Algerian Hospital Environment

Boumediene Abou-Bekr¹, Mohammed A. Adjed², H. Meftah², Y. Ouadah², CH. Boghari², SM. Azzouz², A. Baba-Ahmed²

¹ Université Abou Bekr Belkaid, Tlemcen

² University of Tlemcen

Funding: The author(s) received no specific funding for this work.

Potential competing interests: The author(s) declared that no potential competing interests exist.

Abstract

It is widely acknowledged that cleft palate is one of the most common craniofacial malformations. It requires multidisciplinary care composed mainly of a speech therapist, a radiologist, a psychologist, and above all a pediatric surgeon. It should be noted that the closing of this cleft represents a challenge for the pediatrician who above all seeks to restore the anatomical relationships that are compatible with the velopharyngeal competence that is required for the proper functioning of phonation, swallowing, ventilation, and hearing. Otherwise, the child may develop velopalatine incompetence which can cause a phonatory problem that may remain poorly tolerated by the patient and those around him. This phonatory problem represents a major concern for parents. In addition, the classic surgical technique of *Veau – Wardill - Kilner palatoplasty* consists of dissecting the nasal and oral mucous membranes of the palatal tablets which are sutured along the midline without intravelar myopathy. In the literature, the velar insufficiency rate of this technique is reported as between 15 and 26%. In addition, over the last twenty years, the techniques for reconstructing velopalatine clefts have remarkably progressed. As an example, it is worth citing the Sommerlad intravelar veloplasty (IVV) and the Furlow Z veloplasty which are the most anatomical technique as they both allow repositioning the velar muscles thus leading to an improvement in the lifting and receding movements of the veil, which significantly reduces the sequelae. The goal of the present work, which is based on a sample of 85 cases, is to make an epidemiological, therapeutic, and evolutionary analysis, and also to take stock of the surgical techniques practiced in our country for the primary treatment of cleft palates. It was found that the velar insufficiency rate was much higher after classical palatoplasty than after primary surgery with intravelar veloplasty or Furlow's Z-plasty.

B. Abou-Bekr^{*}, M. A. Adjed, H. Meftah, Y. Ouadah, CH. Boghari, SM. Azzouz, A. Baba-Ahmed

Department of pediatric surgery - Mother and child specialty center at the university hospital of the city of Tlemcen - Algeria

**Corresponding author*

Keywords: Cleft Palate; Soft Palate; Surgery; Phonation; Velar Insufficiency.

Introduction

It is acknowledged that, among congenital malformations of the face, cleft palates (CPs) are by far the most common. Statistically, they represent the proportion of around 1 case per 600 births^[1]. Cleft palates are malformations of the embryo related to a disorder occurring between the 7th and 12th week of pregnancy by a defect in the fusion of buds of the palatal process^[2]. This can range from the simple bifidity of the uvula to the full velopalatine cleft as shown in Figure 1. It is useful to note that the etiology appears to be due to a combination of hereditary and environmental factors. Currently, echography can be used for prenatal diagnosis that can psychologically help to prepare the family and support the newborn. The soft palate is a mobile and contractile musculoaponeurotic partition that is covered with a mucous membrane in continuity with the posterior edge of the hard palate, the action of which is ensured by five even and symmetrical muscles that constitute the velopharyngeal sphincter, as illustrated in Figure 2. The soft palate strongly contributes to the functions of phonation, swallowing, hearing, and breathing. Consequently, the anatomical modifications of the velopharyngeal sphincter, in the event of a cleft palate (CP), are mainly of muscular type, which leads to an insertion defect on the median raphe. As can be seen in Figure 3, these anatomical changes stretch along the inner edge of the cleft to converge into a conjoined tendon that is inserted into the posterior edge of the palatal blade, which consequently leads to velopharyngeal insufficiency (VPI)^[1]. It is worth recalling that primary surgical treatment involves two techniques. The first one is the classic Wardill-Veau-Kilner palatoplasty without muscle repositioning (MR), and the second one is Sommerlad's palatoplasty (Sommerlad's intravelar veloplasty) or Furlow's palatoplasty with muscle repositioning (MR). It should also be noted that any cleft palate repair carries a risk of postoperative complications. This risk may be between 10 and 30% for velopharyngeal insufficiency (VPI)^[3] and between 5.2 and 11.6 %^[4] for fistulas. The present study aims mainly to systematically examine the rates of occurrence of fistulas and velopharyngeal insufficiencies in the surgical techniques of cleft palate (CP) repair practiced in Algeria.

Material and methods

Our study involved 85 patients hospitalized at the Mother and child specialty center at the university hospital of the city of Tlemcen - Algeria. This is a retrospective investigation. The inclusion criteria in this study were any child who was treated between January 2015 and December 2019, and who showed a cleft palate. Note that all patients with syndromic clefts were excluded.

Course of the study

It is worth noting that all the patients were recorded on the pre-established standard form and were operated on by the

same surgeon. In addition, the three techniques used are the following. First, the Wardill-Veau-Kilner palatoplasty, as presented in Figure 4. Second, the Sommerlad intravelar veloplasty (IVV), shown in Figure 5: <https://youtu.be/W65kx8xRk0M> a video produced by the author for the post-graduate teaching of a surgical technique for the closure of a palatal or velar cleft. This technique is based on the realization of an intravelar myoplasty for the purpose of correctly repositioning the muscles of the cleft palate veil. This intravelar myoplasty is a required condition so that the patients can recover the correct phonation]. The third one is the Z-veloplasty of Furlow illustrated in Figure 6: https://youtu.be/1NC0Xw_fgHk a video produced by the author for the post-graduate teaching of a surgical technique for the closure of a velar cleft. This technique is based on the realization of a double Z, i.e. a buccal Z and a nasal Z, offset in mirror, in order to correctly reposition the muscles of the cleft palate veil with lengthening]. Moreover, the postoperative evolution is done after 2 days, 6 days, and one month, in search of postoperative complications, such as a fistula that is due to the release of the staple line. Then, there the speech therapy is carried out for a minimum of 6 months, in parallel with a clinical assessment, a telerradiography (Profile radiography)^[5], aerophonoscopy^[6] (nasal airflow in oral speech, tonic mouth breathing), and speech therapy (Borel - Maissonny classification)^[7], as illustrated in figure 7. Note that the aerophonoscopy was done at one, six, 12, and 24 months. Data entry and processing were carried out with MS Excel software (2016).

Results

Our study sample included 85 patients, with a predominance of males (sex ratio = 1.76). Our study population consisted of 54 boys (64%) and 31 girls (36%). The age of surgery procedures generally varies between 10 months and 7 years, i.e. 35 % between 10 and 18 months; 15 % between 18 and 24 months. It should also be noted that 61.6% of these surgical operations concerned the cleft palates and 38.4% the velar clefts (Figure 8).

Postoperative veil examination

About 15% of our patients presented a scar veil appearance, 65% a soft veil (normal) aspect, and 10% a sclerotic veil. In addition, 20% of the patients exhibited a short veil, and 10% of them exhibited a pathologically-looking uvula that is either bifid or hypoplastic. In addition, it should be noted that *phonatory* behavior and *voice quality* are indices of major importance that can reveal a velopharyngeal insufficiency.

The speech therapy examination, based on Borel – Maissonny's classification (Figure 7), it allowed finding that approximately 46% of patients who underwent *surgery* by the Wardill technique had a phonation that is classified II / 2 IIB, and approximately 53% of them presented a phonation classified IIM and III. However, 82% of the patients operated on by Sommerlad intravelar veloplasty (IVV) and Furlow Z-plasty techniques possessed a phonation classified II / 2 IIB, while 2% of them had a phonation classified IIM and III, as summarized in Table 1.

In radiography (profile radiography), the Björk ratio^[8] is defined as the veil length over the cavum depth. Moreover, the length of the soft palate is defined as the distance separating the upper edge of the hard palate from the top of the uvula

(veil at rest); it has an average value of (23 ± 5) mm in children. Note also that the depth of the cavum, which is the distance between the posterior wall of the hard palate and the posterior wall of the pharynx, is on average equal to (17 ± 5) mm in children. In addition, the average value of the ratio of the veil length over the cavum depth (VL/CD) is estimated as equal to 1.3. It is worth indicating that this ratio must be greater than 1 so that the child can have a good cyclopharyngeal occlusion, which means that the veil must be longer than the cavum. Therefore, the veil should not only touch the posterior wall but must also be attached to it over a certain area^[9]. The pronunciation of the phoneme "r" is dynamic and lasts for several seconds because this letter "r" is the most affected by the nasal air emission in the case of velopharyngeal insufficiencies (VPIs). It is an anterior closed vowel that requires a much retracted position of the veil, which allows us to better examine the functional value of the velopharyngeal sphincter. However, the phoneme "a" is the least affected. This dynamic incidence provides an objective overview of the contraction of the velopharyngeal sphincter. For this, it was deemed important to consider the studies previously carried out by Björk in order to establish a classification of mobility, even the elevation of the veil, on a scale that ranges from 1 to 3, namely (1): *Immobile*, (2) *Static or not very mobile*, and in this case the veil is located below the anterior nasal spine - posterior nasal spine (ANS - PNS) axis, and (3) *Mobile*, in which case, the veil is located on the ANS - PNS axis, as is clearly illustrated in Figure 14. It is important to note that 80% of patients operated on by the intravelar veloplasty (IVV) and Furlow Z-plasty techniques showed a ratio (VL/CD) > 1 , while 75% of them showed an elevated mobile veil (3). However, 20% of the patients operated upon by the Wardill technique had a (VL/CD) ratio greater than 1, while 35% of them had an elevated mobile veil (3). These results are reported in Table 1.

In order to examine the *aerophonoscope assessment content*, and with a desire to keep the method of analyzing *nasal air emission* practical and simple, it was decided to opt for the following rating: [0]: *nonasal air emissions*, [1-25]: *mild nasal air emissions*, [25-50]: *moderate nasal air emissions*, [50-75]: *severe nasal air emissions*, [75 -100]: *very severe nasal air emissions*. The nasal airflow in oral speech (NAOS) and the tonic mouth breathing (TMB) are clearly illustrated in Figures 13 and 12, respectively. After examining our group of patients by aerophonoscopy, we tried to determine the type of velopharyngeal insufficiency (VPI) they suffered from. Indeed, if the *nasal air emission* is significant on the tonic mouth breathing and the nasal airflow in oral speech (NAOS), then the velopharyngeal insufficiency (VPI) is organic. However, if the *nasal air emission* is zero on the tonic mouth breathing but is present in the nasal airflow in oral speech (NAOS), then the VPI is functional. It must be emphasized that approximately 85% of patients operated on by the intravelar veloplasty (IVV) and Furlow techniques presented zero tonic mouth breathing, while 73% of them presented a nasal airflow in oral speech (NAOS) between 0 and 25; therefore, 80 % of velopharyngeal insufficiency (VPI) is functional. On the other hand, 30% of patients operated on by the Wardill technique showed zero tonic mouth breathing, while 28% of them had a nasal airflow in oral speech (NAOS) between 0 and 25; therefore 44% of the velopharyngeal insufficiency (VPI) is functional. These results are summarized in Table 1.

Discussion

It was found that most of the sequelae come from the primary treatment and not from the original malformation. In fact, as

early as 1928, Veau and Ruppe indicated that the surgical procedure was responsible for the appearance of sequelae^[10]. Moreover, if the primary surgery has immediate positive effects, it will also have an influence on craniofacial growth that is not always favorable. It should also be noted that the long-term effects depend significantly on the quality of the primary surgery which can sometimes have negative consequences on various anatomical and functional aspects^[11].

It is worth noting that three techniques were described and used for the initial closure of the palatal and velar clefts of the patients of our sample. Note that the palatal closure was done in one stage, which means that the hard palate and the veil were simultaneously repaired. In addition, it should be mentioned that the various surgical techniques currently available are based on the anatomical specificities of the palatal divisions, particularly those relating to the anatomy of the veil muscles. That is still relevant today. It should also be noted that the anomalies observed are the result of certain surgical techniques that are used for *palatal defect reconstruction* which aim to restore the normal functional muscle anatomy. Therefore, it is essential to acknowledge these anatomical abnormalities before proceeding with the surgery. It should also be remembered that the aim of palate repair surgery is to re-establish the anatomical links which must be compatible with good velopharyngeal function. This is above all a functional surgery that mainly aims to improve and assess the child's future speech abilities. It should also be noted that, according to the published results, the occurrence rate of velopharyngeal insufficiency (VPI) is much higher after classic staphylorrhaphy (26%) than after a primary surgery with intravelar veloplasty (IVV)^{[12][13][14]} or Furlow Z-plasty (4.6 - 6.5%). These results are quite similar to ours. Table 1 indicates that the protocol used for the surgical intervention is classical: velopalatine cleft (VPC) between 10 and 18 months, when possible. It should also be noted that many patients could not benefit from this protocol for social and organizational reasons^{[15][16]}.

Based on some studies, previously conducted by V. Veau, the age of closure of the palate is 18 months. According to this same author, this is the best possible compromise between anesthetic risk and the obtainment of good quality speech results. On the other hand, according to some other authors, palate repair surgery mainly aims to restore the correct velopharyngeal function. Therefore, this surgery procedure ought to be undertaken in the first year of life before the development of a replacement joint. In addition, it is important to remember that the soft palate is used for speaking and therefore is only really used starting from the age of 1 year. Therefore, the velum must be closed before the age of 01 year^{[17][18]}. Based on a recent multicenter study that was conducted on the language assessment of 5-year-old children with complete cleft lip and cleft palate^[19], the percentage of good intelligibility (I, I-II and IIB) with the Talmant protocol is quite high (87.5%), while that of our classic protocol is relatively low (52%).

Furthermore, the postoperative evaluation is mainly dominated by the search for a velar insufficiency (velopharyngeal insufficiency). It is worth mentioning that, until now, there is no international consensus on how to assess phonation^[20]. It is quite possible to assess phonation, in the proper sense of the word, by studying parameters such as nasality, *nasal air emission*, joint disorders, and compensation phenomena. It is important to know that these parameters reflect indirectly the capacity of the velopharyngeal sphincter to achieve good occlusion. In addition, the function of the velopharyngeal sphincter can be directly assessed using the aerophonoscopy and *radiography* techniques in order to know if the sphincter is anatomically performing its function correctly. Note that, in this case, it is no longer the phonatory disorders that are assessed, but rather the sphincter function. Obviously, the two parameters are inseparable^[21].

Clinical examination

It must be emphasized that this examination is capital and informative. Indeed, according to Sommerlad, the dynamic examination of the veil when issuing an [a] is sufficient^[22]. Moreover, a clinical examination allows the soft palate to be properly explored; it also helps to get interesting information about its length, quality, appearance, and mobility. Nevertheless, this examination is always subjective. Note that the presence of oral-nasal communication usually implies functional disturbances during the phonatory and swallowing functions. In addition, the therapeutic attitude towards fistulas would depend on the possible disorders that will be all the more important as the fistula is large. Moreover, it was shown that air leakage during phonation can interfere with speech and sound resonance^[23]. Among the cases studied, 12 of them presented palatal fistulas that were closed by surgery.

Subjective assessment of oral production

The subjective listening assessment is the most common method in assessing voice quality, although it poses a reliability problem. This technique is based on intra-listener variability and inter-listener variability (Borel - Maisonnay classification). Phonations I, I/II, and II B are considered satisfactory phonations because the nasal sound does not interfere with speech intelligibility. In addition, the nasal noise can be either mild or moderate. In general, these phonations can be improved by speech therapy and, for the vast majority, should not require secondary surgery. On the other hand, the phonations II M and III are considered unsatisfactory due to poor speech intelligibility linked to a severe nasal noise, often with added noises (nasal murmur, glottis, hoarse murmur, nasal snoring)^[24].

Profile teloradiography

It is used to classify the different types of cyclopharyngeal occlusions. According to Van Demark, when the distance between the soft palate and the posterior pharyngeal wall is greater than 2 mm, there is velopharyngeal insufficiency (VPI). Further, it was deemed interesting to use Björk's ratio (VL/CD)^[8] as well as the posterior nasal spine (PNS) - anterior nasal spine (ANS) axis as a radiological reference in order to be able to carry out an objective evaluation of the length of veil, its mobility, and the cavum depth, and also to do an anatomo-functional classification. Other authors, such as Subtelny^[25] and Owsley^[26], also used Björk's ratio (VL/CD) for the radiological evaluation of their patients. On the other hand, aerophonoscopy makes it possible to quantify the nasal air emission during the phonatory function and also to compare the nasal air emissions between two check-ups in order to assess the effects of an operation or speech therapy^[27]. In this context, Gabriel Rousteau, a phoniatic physician, has repeatedly described in his work a protocol that allows distinguishing whether the origin is functional, organic, or neurological. On the expression "sinousaôsènsitatousenawats", the nasal airflow in oral speech (NAFOS)^[28] comprises all the oral vowels and the constrictive "s" which is the consonant that requires the highest velopharyngeal contraction.

Tonic mouth breathing

In this case, it is required to breathe as hard as possible through your mouth after a good breath intake. The examination carried out makes it possible not only to evaluate the effectiveness of the velopharyngeal contraction but also to detect the difficulties in dissociating oral breathing and nasal breathing in children with dyspraxia. For this, it was decided to adopt an aerophonoscopic exploration protocol for all patients. It should be noted that recent and detailed studies relating to the aerophonoscope are quite rare. In 2015, Ganry^[29] found out that the aerophonoscope provides reproducible inter- and intra-individual quantitative measurements. Its sensitivity to the degree of occlusion of the velopharyngeal sphincter is quite good in healthy subjects. However, the benefit of aerophonoscopy in the treatment of labial-alveolar-palatal clefts remains to be established. It is worth noting that more reliable quantitative data are still needed to determine the importance of this instrument in the follow-up of children with clefts, in the decision-making of a surgical veil replacement, and in the evaluation of the effectiveness of secondary procedures such as pharyngoplasty with a lower or upper pedicle. With regard to Gbaguidi, Testelin, and Devauchelle (2003)^[30], they found out that, in the case of velopharyngeal insufficiency (VPI), the exploration of phonation by aerophonoscopy seems to be a quite suitable examination for the assessment of phonation, due particularly to its ease of use, its non-invasive nature and also to the fact that it can be repeated on demand. Now, the only question worth asking is: *From what age can we apply aerophonoscopy?* In his study, which involved 314 patients, G. Rousteau^[31] indicated that this technique can be applied from the age of 3 and a half. Moreover, due to the reproducibility of the tests, the phonation can be objectively compared, for the same patient, before and after surgery. Moreover, another advantage of the aerophonoscope lies in the fact that it can help with speech therapy which allows the patient to rehabilitate thanks to a retroactive visual effect. In this context, Devauchelle et al. (2003) suggested that when a pharyngoplasty is decided following the identification of velopharyngeal insufficiency in a child with a cleft palate, an aerophonoscope assessment may be performed in the month preceding the operation. Then, it can be repeated after one month, six months, and one year after the operation. Afterward, the early result is evaluated one month after the operation in order to decide whether speech therapy should be repeated again or not. Note that the effectiveness of this rehabilitation is evaluated during the following aerophonoscopic examinations. For Devauchelle and colleagues, even if the aerophonoscope seems to be ideal for assessing phonation and for comparing the results, it does not, however, give any indication about the mechanism of velopharyngeal insufficiency, and therefore does not make it possible to prefer one surgical technique over another. Moreover, when two patients present the same *nasal air emission*, it is possible that one of them may have a less shocking tone alteration at listening than the other, with nasal snoring or extraneous noises like nasal breathing^[8]. It is worth pointing out that *nasal air emission* cannot be the only decision-making criterion in terms of rehabilitation. One has to take into consideration the discomfort felt by the child with respect to these phenomena. According to P. Blot^[32], it is possible to use numerical values for the purpose of developing research protocols, in particular in the case of velar surgery, but also for monitoring patients who had functional rhinoplasty surgical operations. This constitutes one of our current research objectives. In our work, the aerophonoscope would be an effective tool that can be made available to the pediatric surgeon when assessing velopharyngeal insufficiencies (VPIs) because it provides precise, reliable, and user-friendly assistance. It is a practical and reliable therapeutic accessory because it allows for velar rehabilitation that may be assisted by several modes (plane, clown). Moreover, it allows patients

to easily identify their faults with high reliability in finding nasal leaks. It can also make the preoperative and postoperative assessment easier and may also facilitate the comparative studies of subsequent examinations in accordance with the selected protocol. However, certain difficulties, such as tuning problems during measurements or software freezing, especially when used for the first time, have been reported.

Conclusion

This retrospective study made it possible to establish an adequate clinical and paraclinical analysis of the operated cleft palates. In addition, the profile radiography and aerophonoscopy techniques were of great and reliable assistance in the assessment of velopharyngeal insufficiencies (VPIs). These two techniques are unquestionably important. In addition, the classical Wardill-Veau-Kilner palatoplasty without muscle reposition showed a much higher percentage of velopharyngeal insufficiency (VPI) than the Sommerlad's intravelar veloplasty (IVV) or Furlow's palatoplasty with muscle reposition. Finally, it is highly recommended to perform early and functional surgery in the primary closure of cleft palates in order to decrease the incidence rate of fistulas and velopharyngeal insufficiencies (VPIs).

Figures and Tables

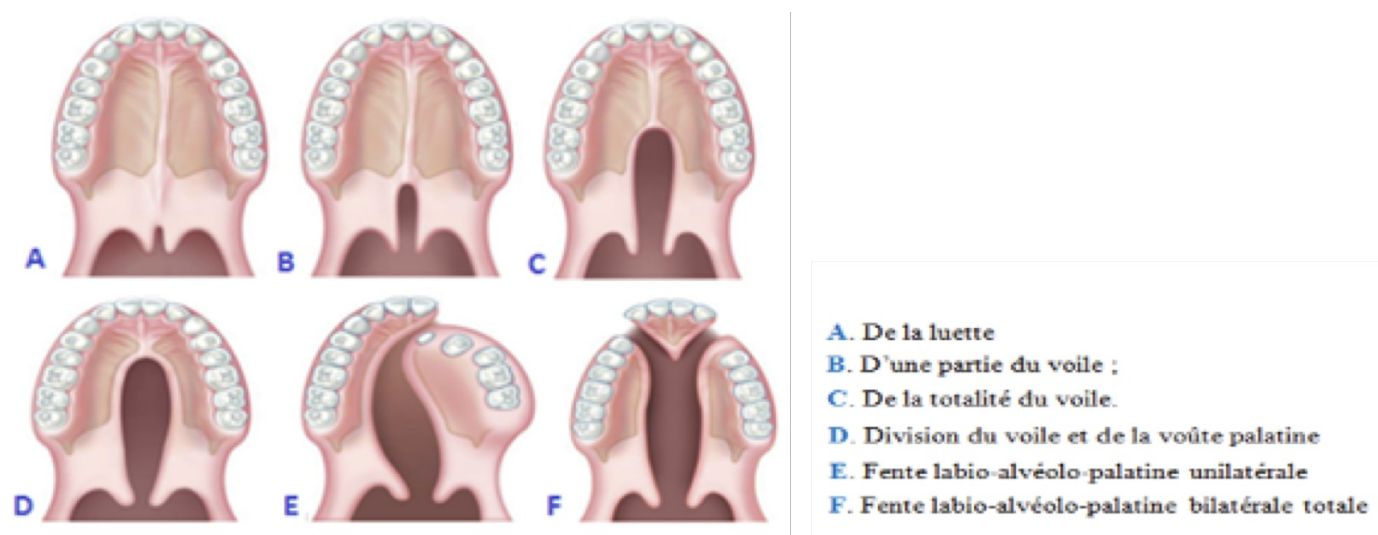


Figure 1^[33]: V. Veau classification

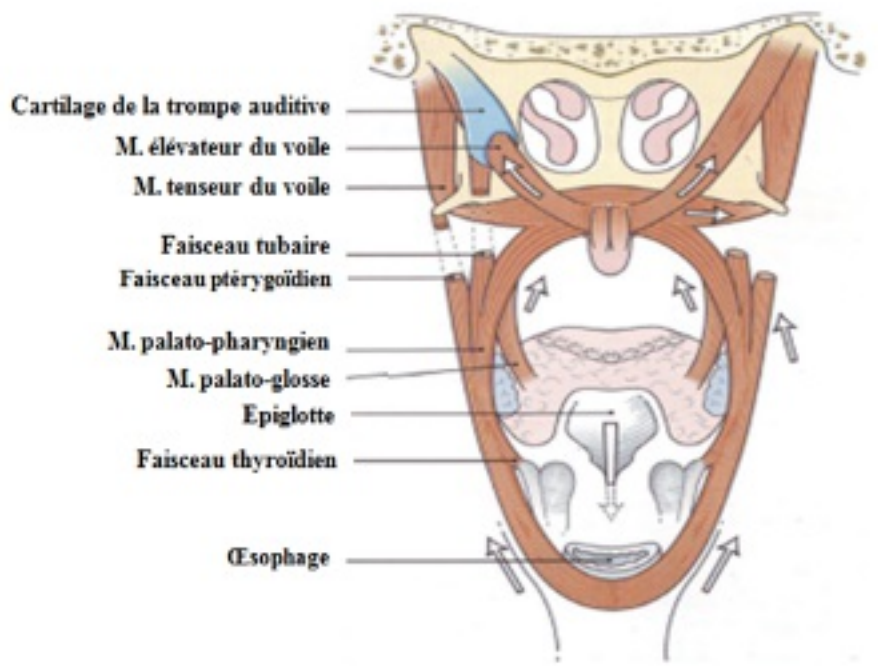


Figure 2^[34]: Functions of the palate muscles

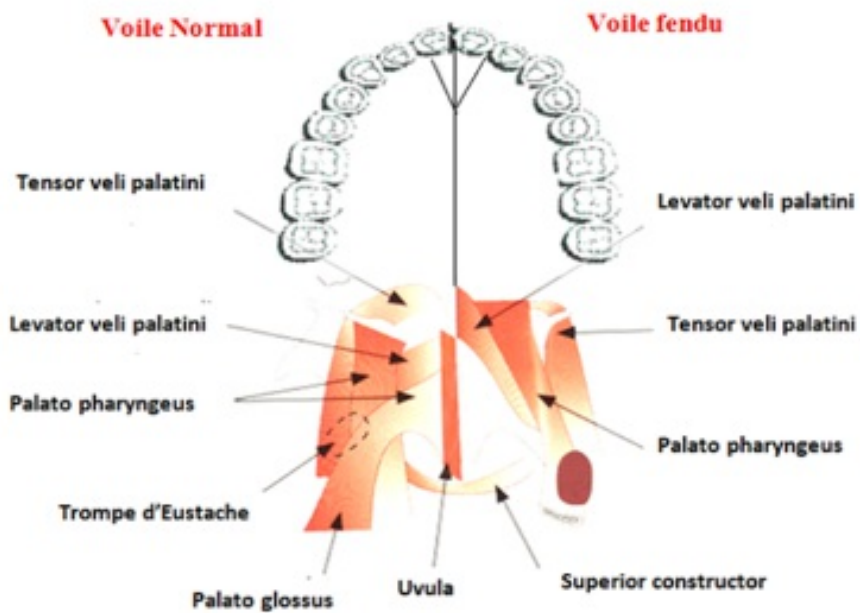


Figure 3^[35]: Anatomy of normal palate veil and cleft palate veil

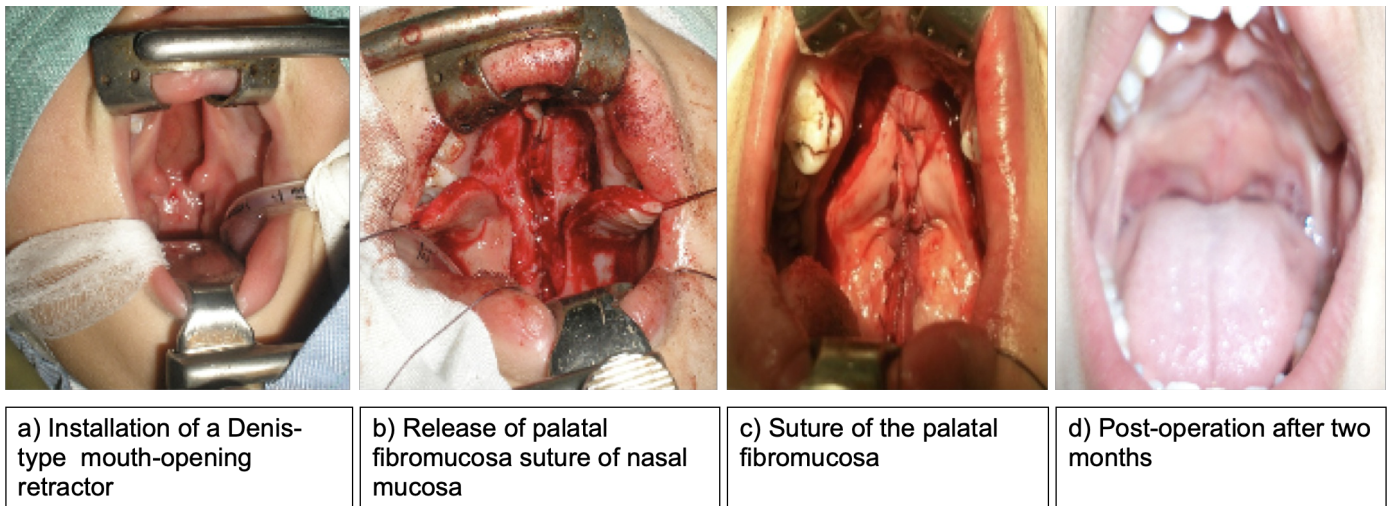


Figure 4: Veau – Wardill - Kilner technique

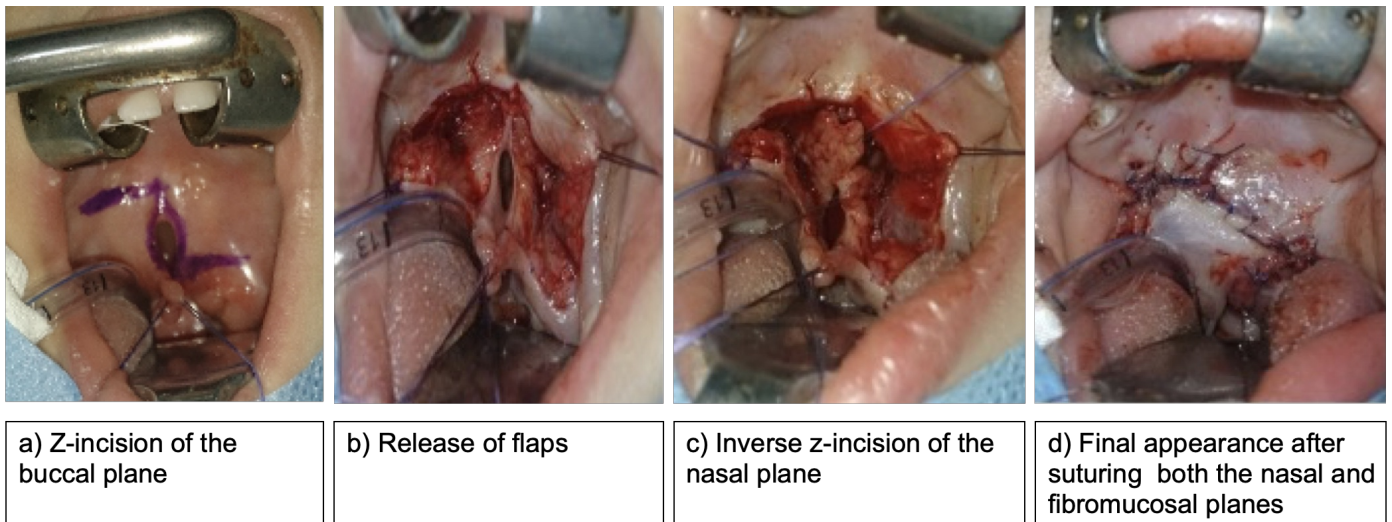


Figure 5: Furlow's double Z veloplasty

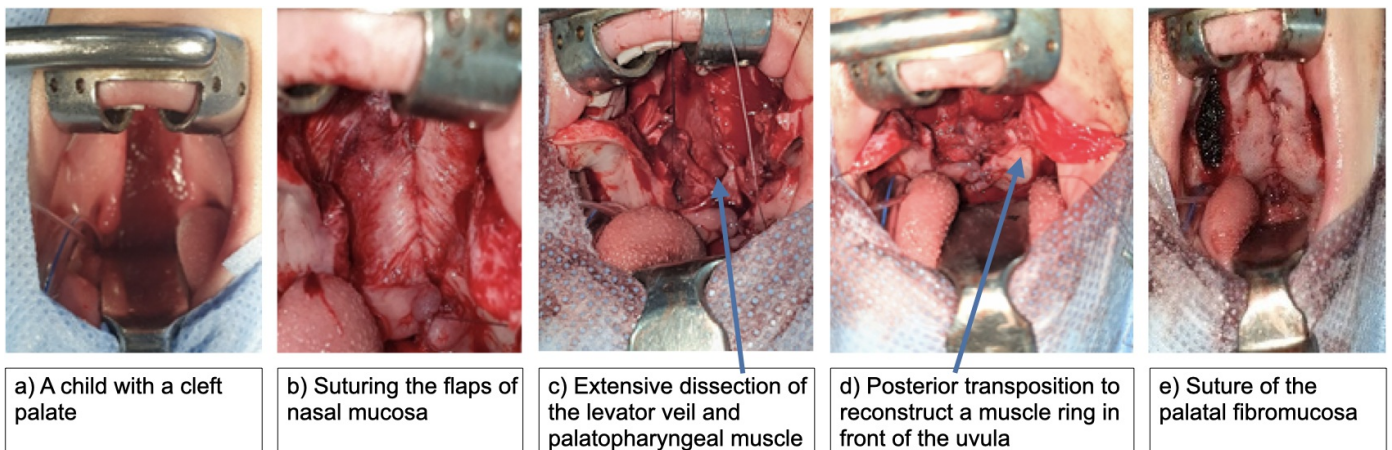
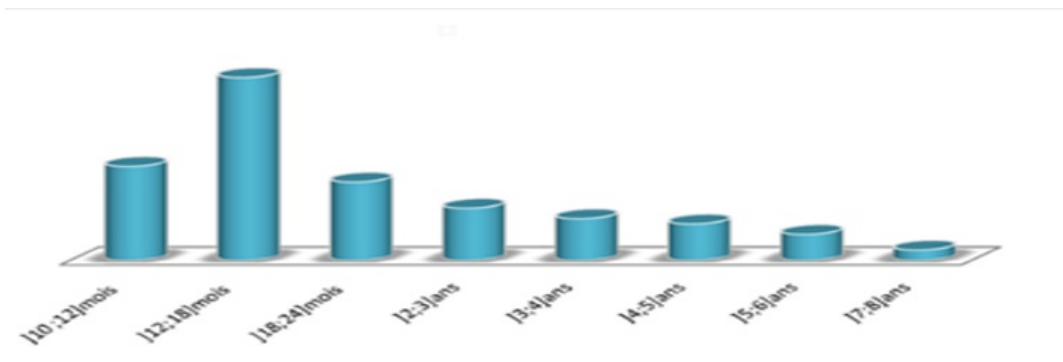
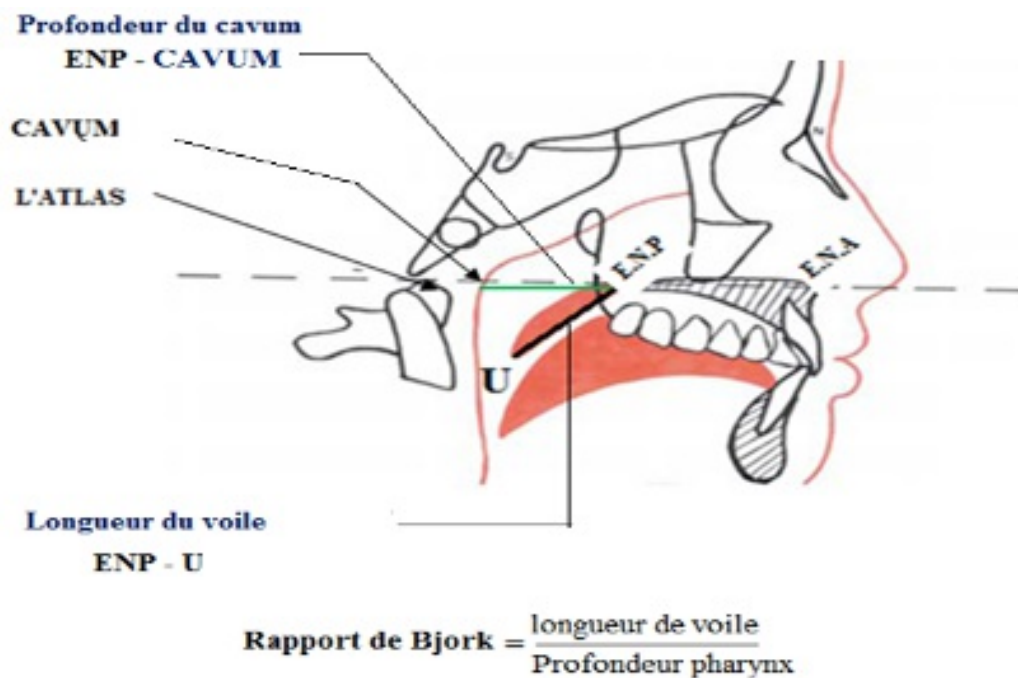


Figure 6: Sommerlad's intravelar veloplasty (IVV)

Figure 7: Borel - Maisonnny classification

Grade	Description
1	Normal phonation - No nasal leakage
1/2	Intermittent nasal leakage
2b	Continuous <i>nasal air emission</i> - Intelligible phonation
2m	Continuous <i>nasal air emission</i> - Unintelligible phonation
3	Presence of compensatory mechanisms


Figure 8: Age of palate closure

Figure 9: Lateral radiography

Static: Bjork ratio (VL/CD) greater than 1 ; **Dynamic:** Mobility of the veil (elevation) in "i": (1) The veil is static immobile, (2) The veil is not very mobile and is located below the (ANS - PNS) axis, (3) The veil is mobile and is located on the (ANS - PNS) axis

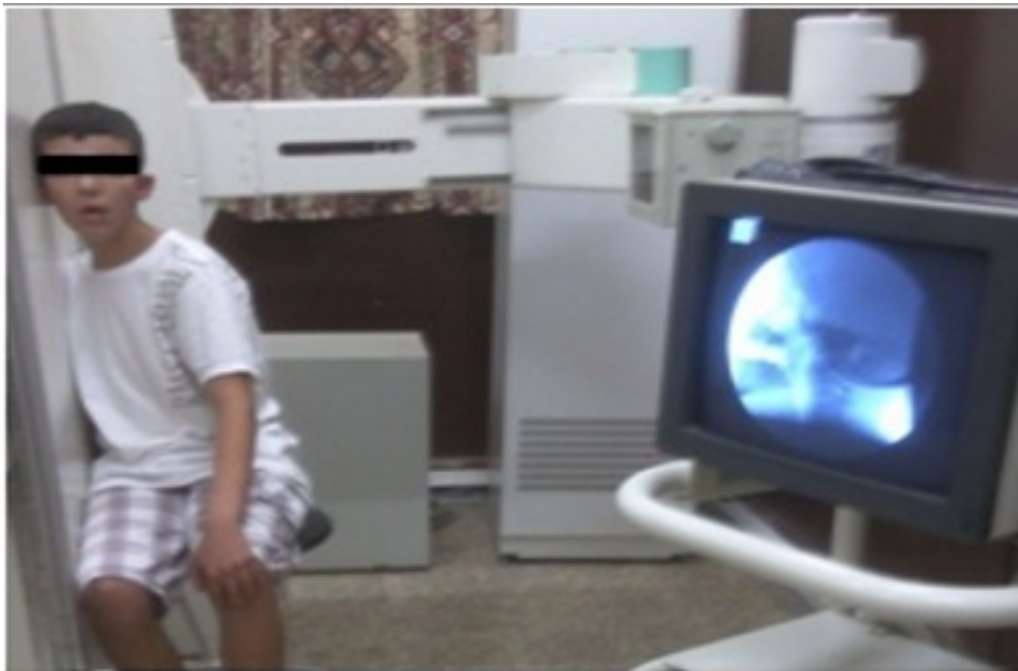

Figure 10: Lateral teleradiography - Photo taken at the radiography department - Tlemcen

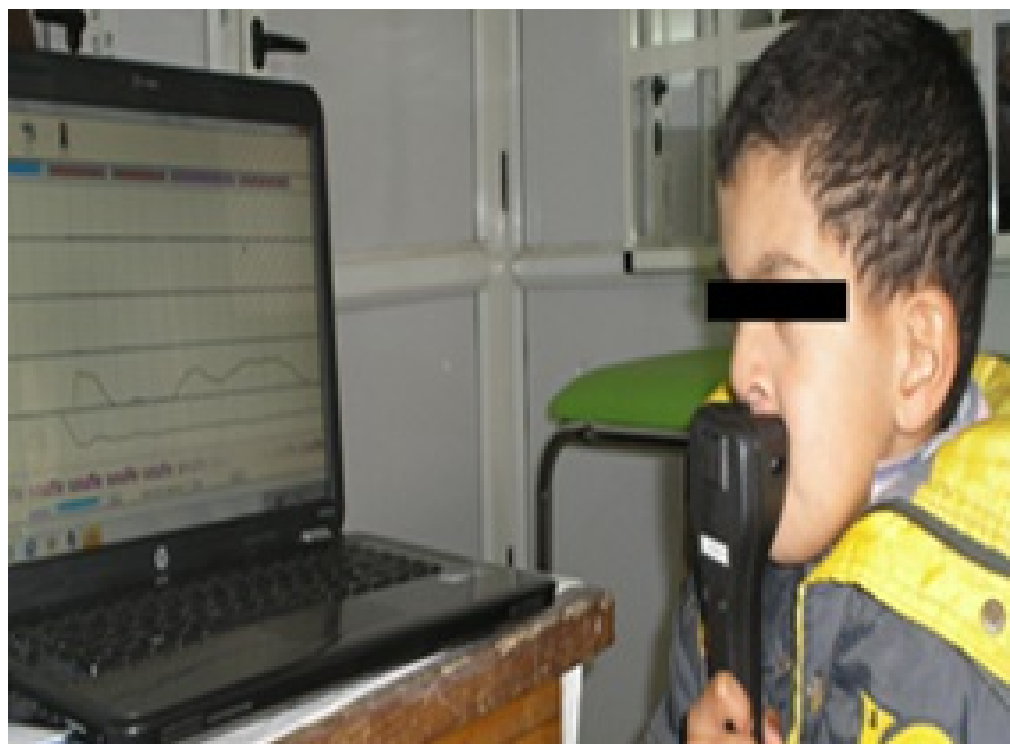

Figure 11: Profile aerophonoscopy - Photo taken at the radiography department - Tlemcen

Table 1: Comparison between the clinical, orthophonic, radiographic, and aerophonoscopic results

Technique	Number of cases	Number of fistulas	orthophony											Aérophonoscopia				VPI	
			Teleradiography											(Tonic mouth breathing TMB)		Nasal airflow in oral speech (NAOS)		Functional	Organic
			VL/CD		Veil mobility			0		>50		0-25	>50						
			I	I/2	IIb	IIIm	III	<1	>1	1	2	3	0	>50	0-25	>50			
<i>wardill</i>	45	10	1	5	15	19	5	30	15	9	20	16	15	25	13	27	20	25	
<i>ivv</i>	30	02	4	9	12	5	0	6	24	0	8	22	25	5	22	8	24	6	
<i>furlow</i>	10	0	2	3	3	2	0	0	10	0	2	8	10	0	7	3	10	0	

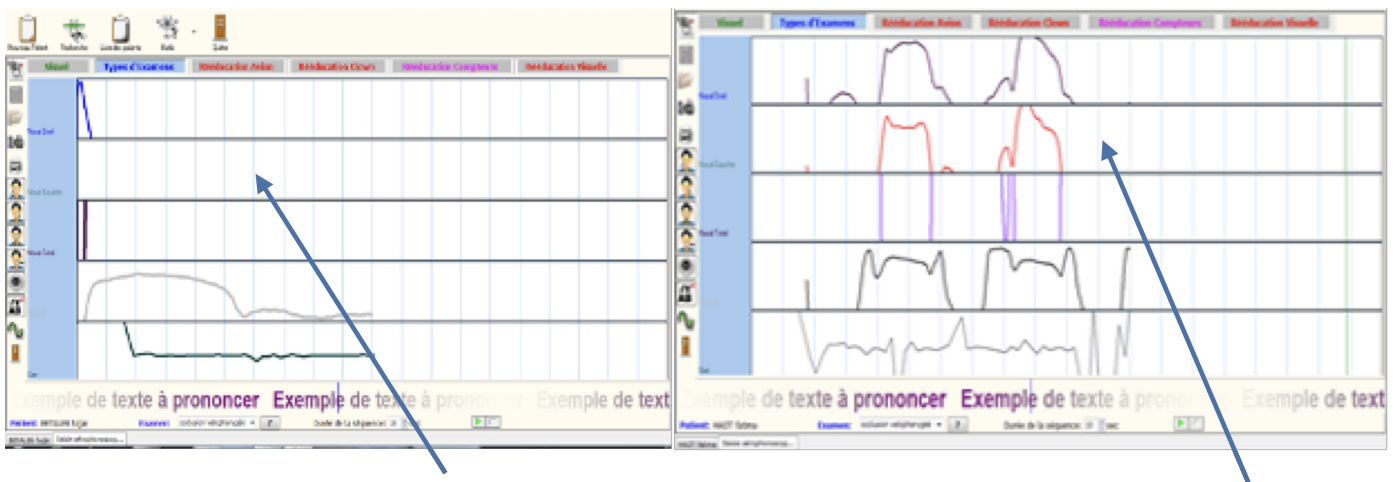
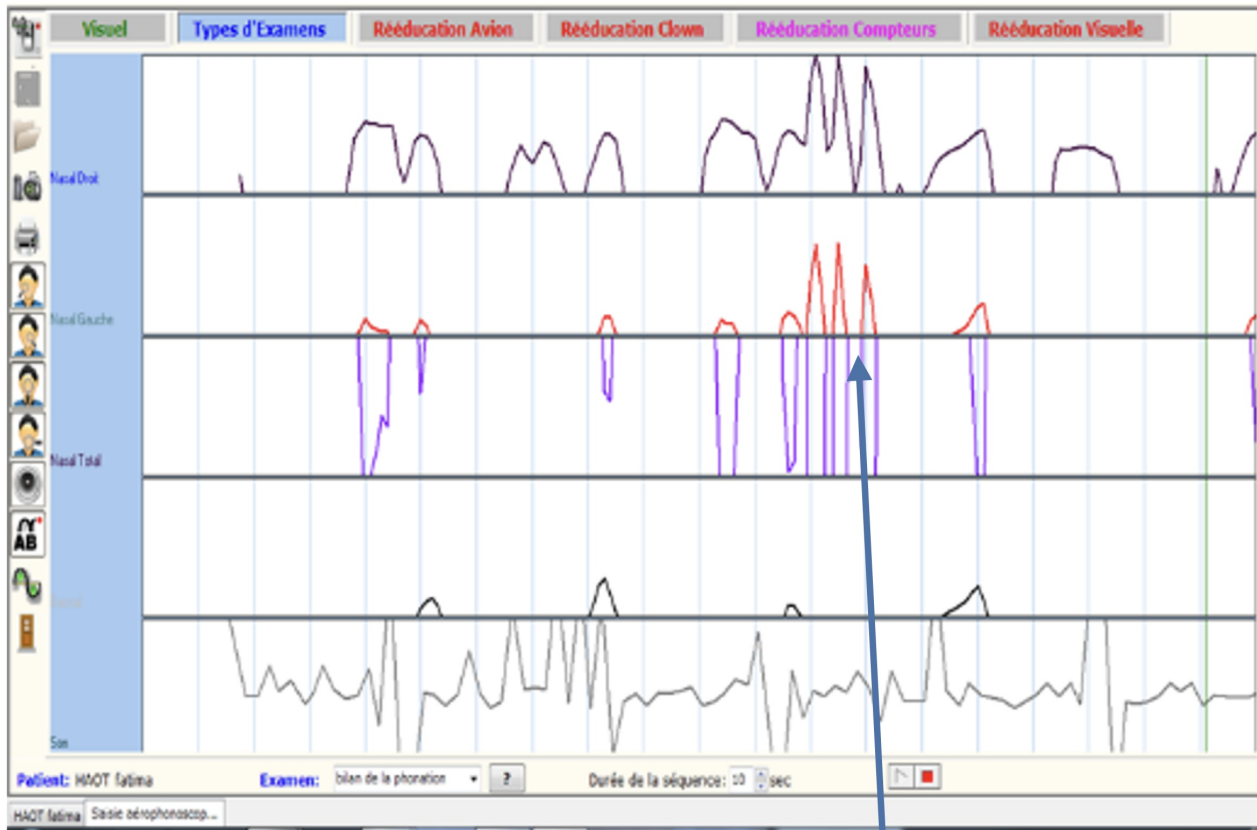


Figure 12 : Aerophonoscopy - Tonic mouth breathing



75 – 100 %: Very severe *nasal air emission*

Figure 13: 0%: No *nasal air emission*; *Nasal air emission* between 75 and 100 %: very severe
Aerophonoscopy - Nasal airflow in oral speech (NAOS)

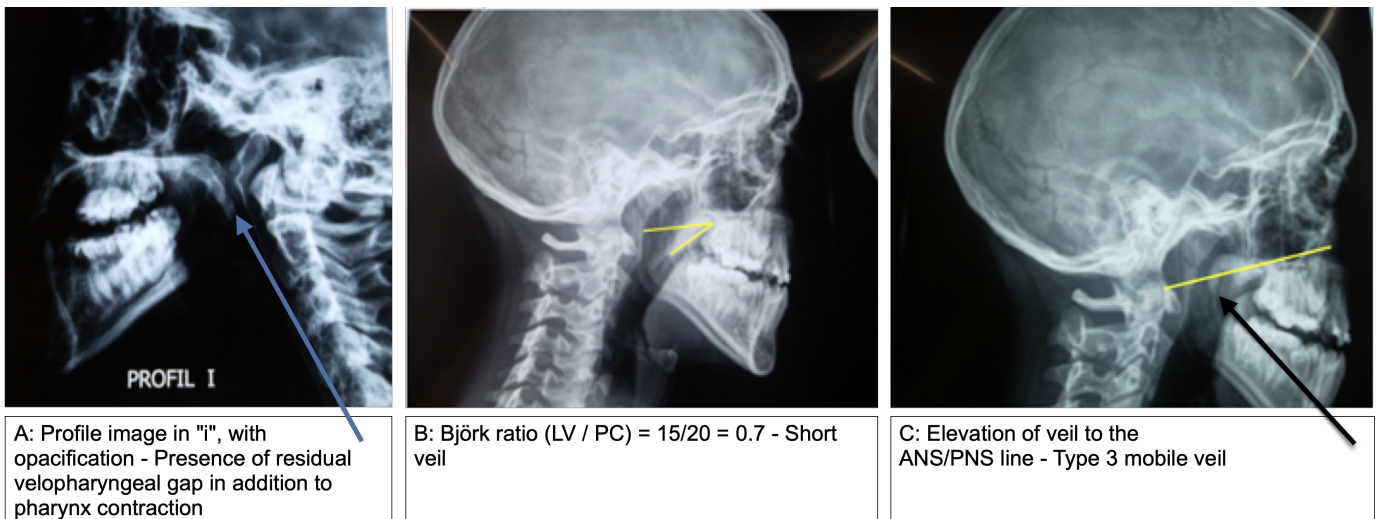


Figure 14: Profile x-rays: A – B – C

References

1. ^{a, b}ABOU-BEKR, B. (2020). *Pharyngoplastie à lambeau supérieur (PLS): Traitement de l'insuffisance vélopharyngée par la (PLS) dans les séquelles des fentes palatines*. Éditions universitaires européennes. Google scholar
2. [^]De Bérail, A., Lauwers, F., Noirrit Esclassan, E., Woisard Bassols, V., Gardini, B., & Galinier, P. (2015). *Épidémiologie des malformations associées aux fentes labiales et palatines à propos d'une étude rétrospective de 324 cas*. *Archives de Pédiatrie*, 22(8), 816-821. <https://doi.org/10.1016/j.arcped.2015.05.005>
3. [^]Talmant, J. C., Talmant, J. C., & Lumineau, J. P. (2007). *Une approche fonctionnelle lors du traitement primaire des fentes labioalvéolopalatovélaires pour le minimum de séquelles*. *Revue de Stomatologie et de Chirurgie Maxillo-faciale*, 108(4), 255-263. <https://doi.org/10.1016/j.stomax.2007.06.002>
4. [^]Mapar, D., Khanlar, F., Sadeghi, S., Abdali, H., Memarzadeh, M., Davari, H. A., & Derakhshandeh, F. (2019). *The incidence of velopharyngeal insufficiency and oronasal fistula after primary palatal surgery with Sommerlad intravelar veloplasty: A retrospective study in Isfahan Cleft Care Team*. *International Journal of Pediatric Otorhinolaryngology*, 120, 6-10. <https://doi.org/10.1016/j.ijporl.2018.12.035>
5. [^]Houge De Laulnoit S., Martinot V., Breviere G.M., Kulik J.F., Pellerin P. *Analyse téléradiographique de l'insuffisance vélo-pharyngée dans l'association catch 22*. *Ann. Chir. Plast. Esthet.* 1999. Vol. 44; 525-30.
6. [^]Devani, P., Watts, R., & Markus, A. F. (1999). *Speech outcome in children with cleft palate: Aerophonoscope assessment of nasal emission*. *Journal of Cranio-Maxillofacial Surgery*, 27(3), 180-186. [https://doi.org/10.1016/s1010-5182\(99\)80048-1](https://doi.org/10.1016/s1010-5182(99)80048-1)
7. [^]Borel-Maisonny S. *L'insuffisance vélaire, point de vue de l'orthophoniste, reéducation orthophonique 1975*.
8. ^{a, b, c}Bjork L. *Velopharyngeal function in connected speech: studies using tomography and cineradiography synchronised with speech spectrography*. *Acta. Radial.* 1961. Vol. 27.
9. [^]Montoya P., Baylon-Campillo H. *L'incompétence vélopharyngée. Exploration et prise en charge thérapeutique*. Molinghem: Ortho Edition, 1996. ISBN 2-904896-46-2.
10. [^]Benateau H., Diner P., Soubeyrand E., Vazquez M.-P., Picard A. *Les séquelles maxillaires dans les fentes labioalvéolopalatovélaires. Analyse des causes de la rétromaxillie et réflexions sur la prévention*. *Revue de Stomatologie et de Chirurgie Maxillo-Faciale*. Septembre 2007. Vol. 108, N° 4, pp. 313-320.
11. [^]Riou E., Decker A., Deffrennes D. *Réflexions thérapeutiques sur le traitement des séquelles de fente labio-alvéolo-palatine chez le patient adulte – Partie 1*. *International Orthodontics*. s.l.: Elsevier Masson, 2012. Vol. 10, 4, p. 241 à 260.
12. [^]Sommerlad, B. C. (2002). *The management of cleft lip and palate*. *Current Paediatrics*, 12(1), 43-50. <https://doi.org/10.1054/cupe.2001.0246>
13. [^]Sommerlad B.C. *The use of the operating microscope for cleft palate repair and pharyngoplasty plus reconstruction* 2003. Vol. 112
14. [^]Sommerlad B.C. *A technique for cleft palate repair*. *Plast. Reconstr. Surg.* 2003, Vol. 112: 1542-1548.
15. [^]Kara, M., Calis, M., Kara, I., Kulak Kayikci, M. E., Gunaydin, R. O., & Ozgur, F. (2021). *Comparison of speech outcomes using type 2b intravelar veloplasty or Furlow double-opposing Z plasty for soft palate repair of patients with*

unilateral cleft lip and palate. *Journal of Cranio-Maxillofacial Surgery*, 49(3), 215-222.

<https://doi.org/10.1016/j.jcms.2021.01.003>

16. [^]Basta, M. N., Fiadjoe, J. E., Woo, A. S., Peeples, K. N., & Jackson, O. A. (2018). Predicting Adverse Perioperative Events in Patients Undergoing Primary Cleft Palate Repair. *The Cleft Palate-Craniofacial Journal*, 55(4), 574-581. <https://doi.org/10.1177/1055665617744065>
17. [^]berkowitz S. performing early palatal closure in newborns, is it necessary for speech 2007.
18. [^]chapman KL., hardin-jones MA. timing of palatal surgery and speech outcome 2008.
19. [^]dissaux C, Grollemund B, Bodin F, Picard A, Vazquez M-P, Morand B, et al. Evaluation of 5-year-old children with complete cleft lip and palate: multicenter study. Part 2: functional results. *J Craniomaxillofac Surg* 2016;44(2):94–103.
20. [^]hsichberG., j.and van D. A proposal for standardization of speech and hearing evaluation to assess velopharyngeal function 1997.
21. [^]Kara, M., Calis, M., Kara, I., Incebay, O., Kulak Kayikci, M. E., Gunaydin, R. O., & Ozgur, F. (2020). Does early cleft palate repair make difference? Comparative evaluation of the speech outcomes using objective parameters. *Journal of Cranio-Maxillofacial Surgery*, 48(11), 1057-1065. <https://doi.org/10.1016/j.jcms.2020.09.003>
22. [^]talmant J-C., talmant J-C., lumineau J.-P. Traitement chirurgical secondaire des fentes labio-alvéolo-palatines. *EMC - Techniques chirurgicales - Chirurgie plastique reconstructrice et esthétique*. 2012. 7(1):1-24 [Article 45-585]
23. [^]raoul G., ferri J. Les fistules palatines résiduelles dans les séquelles de fentes labioalvéolopalatovélaires. septembre 2007, Vol. 108, N° 4, pp. 321-328.
24. [^]Kadlub, N., Chapuis Vandenberg, C., Joly, A., Neiva, C., Vazquez, M. P., & Picard, A. (2018). Speech evaluation after intravelar veloplasty. How to use Borel-Maisonny classification in the international literature? *Journal of Stomatology, Oral and Maxillofacial Surgery*, 119(2), 107-109. <https://doi.org/10.1016/j.jormas.2017.11.011>
25. [^]subtelny JD. A cephalometric study of the growth of the soft. *Plast Reconstr Surg* 1957;19:49–62.
26. [^]owsley JR JQ., chierici G., miller ER., lawson LI., blachfield HM. Cephalometric evaluation of palatal dysfunction in patients. *Plast Reconstr Surg* 1967;39:562–8.
27. [^]aussedat G. Etude des fentes labio-palatines chez l'enfant de 5 ans: apport de l'Aérophonoscope dans le cadre d'une étude pluridisciplinaire. Nancy: s.n., 2010
28. [^]Dhab S., mitrofanoff M., majourau-bouriez A. Outils pour l'évaluation de la fonction vélaire chez les patients arabophones. PARIS FRANCE: s.n., 2012.
29. [^]Ganry L., Blot P. Exploration quantitative de la phonation par aréphonoscope: étude de reproductibilité sur sujets sains *rev stomato chir maxillofacial chir oral* 20 15 117 62-66 2015.
30. [^]Gbaguidi C., Testelin S., Devauchelle B. Les pharyngoplasties dans le traitement de l'insuffisance vélo-pharyngée des fentes palatines. *Rééducation orthophonique, les fentes oro-faciales*. décembre 2003. trimestriel n° 216, p 67 - 79.
31. [^]Rousteau G. L'évaluation de la fonction vélaire au moyen de l'aérophonoscope: essai de classification des rhinolalies ouvertes à partir de 3,5 ans. 2012
32. [^]Blot P., Khonsari R.H. *Mesure du flux nasal en aérophonoscopie*. s.l.: Elsevier Masson, 2009.
33. [^]noirrit-esclassan E., pomar p., esclassan R., terrie B., galinier, woisard V. Plaques palatines chez le nourrisson porteur de fente labiomaxillaire. *EMC - Médecine buccale*. 2008.: 1-14 [Article 28-680-V-10].

34. [^] *kamina. Anatomie clinique. Paris: Maloine, 2006. Vol. 3ème édition, Tome 2.*
35. [^] *Bigorre M. Chirurgie plastique de l'enfant et de l'adolescent. s.l.: Sauramps medical, sep 2015. ISBN 13: 9791030300208.*