

## Commentary

# Kienböck's Disease May Be Due to a Wrist-Joint Tamponade

Bengt Mjöberg<sup>1</sup>

1. Department of Orthopedics, Lund University, Sweden

**Kienböck's disease may be due to a mechanism (similar to a muscle compartment syndrome) that reduces the lunate perfusion. Arthrocentesis at an early stage can probably prevent the disease.**

Corresponding author: Bengt Mjöberg, [bengt.mj@telia.com](mailto:bengt.mj@telia.com)

## Introduction

The etiology of Kienböck's disease (osteonecrosis of the lunate bone) has been debated for a century now. Kienböck asserted that it was first a nutritional disturbance of the lunate bone followed by a fracture of the weakened bone<sup>[1]</sup>. Most studies have focused on anatomical risk factors (such as ulnar variance, radial inclination, and lunate morphology), but the cause of the osteonecrosis is still considered enigmatic. Current hypotheses include suggestions of localized venous obstruction and interstitial edema ("compartment syndrome of the bone") due to stress microfractures<sup>[2]</sup>, reduced arterial blood flow to the lunate bone due to an inappropriate wrist position<sup>[3]</sup>, and intra-osseous venous thrombosis due to an inflammatory disorder<sup>[4]</sup>. Hence, it seems justified to call attention to an explanation that seems more consistent with the clinical evidence.

## Scaphoid fractures, femoral neck fractures, and Kienböck's disease

Scaphoid fractures and femoral neck fractures are etiologically interesting in this context: partly because they are associated with a high risk of osteonecrosis; and partly because the proximal fragment of a scaphoid fracture, the femoral head of a femoral neck fracture, and the lunate bone all have the characteristics of being drained via capsular veins, which are directly exposed to intra-articular pressure.

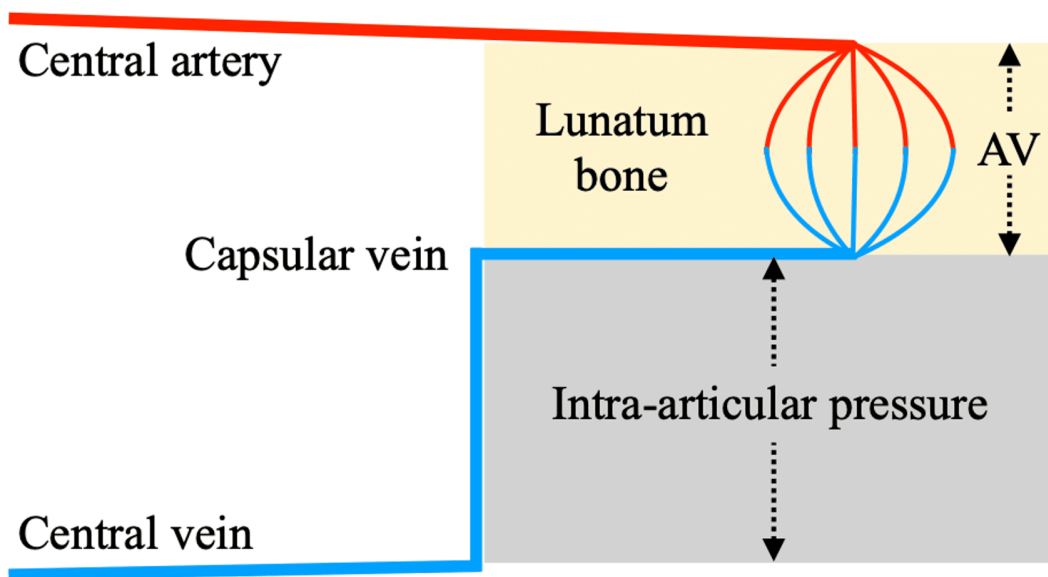
After an undisplaced scaphoid fracture, an intra-articular pressure of 10 kPa (76 mm Hg) due to hemarthrosis (*wrist-joint tamponade*) was recorded<sup>[5]</sup> – probably enough to cause osteonecrosis of the proximal scaphoid fragment or the lunate bone – and arthrocentesis (3 mL blood) in this case brought immediate pain relief.

It is well documented that hemarthrosis in the hip joint can cause osteonecrosis of the femoral head because of increased intra-articular pressure (*hip-joint tamponade*) after an undisplaced femoral neck fracture<sup>[6][7][8]</sup>. By contrast, when the joint capsule ruptures in a displaced femoral neck fracture, no joint tamponade occurs because the intra-articular bleeding is drained.

The fact that Kienböck's disease often (about 50% of cases) has a history of prior trauma to the wrist<sup>[9]</sup>, but is rare after intercarpal dislocations and fracture-dislocations (none observed in 59 cases)<sup>[10]</sup>, suggests that, similar to undisplaced femoral neck fractures, Kienböck's disease may result from a wrist-joint tamponade—an effect that does not occur when the joint capsule ruptures in intercarpal dislocations and fracture-dislocations. Kienböck's disease has also been associated with several medical disorders (such as rheumatoid arthritis, gout, juvenile idiopathic arthritis), which probably caused episodes of severe joint effusion<sup>[11]</sup>. Thus, at least some of these non-traumatic cases appear to be explained by wrist-joint tamponade.

## Wrist-joint tamponade

The proposed mechanism is similar to a muscle compartment syndrome<sup>[12]</sup> — but is confined by a joint capsule instead of a muscle fascia. A wrist-joint tamponade increases the pressure in the capsular veins draining the lunate bone, reduces the arteriovenous pressure gradient (Figure 1), and thus decreases lunate perfusion, which may result in osteonecrosis. Later, after spontaneous revascularization and osteolysis, anatomical risk factors have a mechanical impact on the weakened lunate bone that can subsequently collapse<sup>[13]</sup>.



**Figure 1.** A wrist-joint tamponade reduces the arteriovenous pressure gradient (AV) in the lunatum bone, i.e., the height of the capillary loop in the schematic chart. Note that the capsular vein pressure cannot be less than the intra-articular pressure: the higher the intra-articular pressure, the less the arteriovenous pressure gradient. Adapted from Matsen<sup>[12]</sup>.

## Conclusions

Wrist-joint tamponade may explain both traumatic and non-traumatic cases of Kienböck's disease and may also explain why the disease rarely occurs after intercarpal dislocations and fracture-dislocations. Wrist arthrocentesis of a tense joint effusion at an early stage (if given the opportunity, e.g., shortly after a trauma) can probably prevent osteonecrosis, thereby avoiding the development of Kienböck's disease.

## References

1. <sup>△</sup>Kienböck R. Über traumatische Malazie des Mondbeins und ihre Folgezustände. Entartungsformen und Kompressionsfrakturen [Concerning traumatic malacia of the lunate and its consequences: joint degeneration and compression]. *Fortschr Geb Röntgenstr.* 1910;16:77-103. Available from: <https://numerabilis.u-paris.fr/ressources/pdf/medica/bibnum/epo0555/epo0555.pdf>.
2. <sup>△</sup>Bain GI, MacLean SB, Yeo CJ, Perilli E, Lichtman DM (2016). The etiology and pathogenesis of Kienböck disease. *J Wrist Surg.* 5:248-54. doi:10.1055/s-0036-1583755.

3. <sup>△</sup>Kim S, Eichenauer F, Asmus A, Mutze S, Eisenschenk A, Honigmann P. Superselective angiography of the wrist in patients with Kienböck's disease. *BMC Musculoskelet Disord* 2019; 20: 143. doi:10.1186/s12891-019-2492-5
4. <sup>△</sup>Camus EJ, Van Overstraeten L. Kienböck's disease in 2021. *Orthop Traumatol Surg Res* 2022; 108: 103161. doi:10.1016/j.otsr.2021.103161.
5. <sup>△</sup>Mjöberg B. Wrist joint tamponade after scaphoid fracture. A case report. *Acta Orthop Scand* 1989; 60: 371. doi:10.3109/17453678909149298
6. <sup>△</sup>Strömqvist B, Nilsson LT, Egund N, Thorngren KG, Wingstrand H. Intracapsular pressures in undisplaced fractures of the femoral neck. *J Bone Joint Surg Br* 1988; 70: 192-4. doi:10.1302/0301-620X.70B2.3346286.
7. <sup>△</sup>Bonnaire F, Schaefer DJ, Kurer EH. Hemarthrosis and hip joint pressure in femoral neck fractures. *Clin Orthop Relat Res* 1998; (353): 148-55. doi:10.1097/00003086-199808000-00017.
8. <sup>△</sup>Beck M, Siebenrock KA, Affolter B, Nötzli H, Parvizi J, Ganz R. Increased intraarticular pressure reduces blood flow to the femoral head. *Clin Orthop Relat Res* 2004; (424): 149-52. doi:10.1097/01.blo.0000128296.28666.35
9. <sup>△</sup>Wassef C, Rechter GR, Tatapudi S, Sambhariya V, Pientka WF 2nd. The effect of radial inclination on the stage of Kienbock disease at the time of initial diagnosis. *HAND* 2024. Epub ahead of print. doi:10.1177/15589447231221246
10. <sup>△</sup>Russel TB. Inter-carpal dislocations and fracture-dislocations; a review of 59 cases. *J Bone Joint Surg Br* 1949; 31B: 524-31. PMID: 15397134
11. <sup>△</sup>Desy NM, Bernstein M, Harvey EJ, Hazel H. Kienbock's disease and juvenile idiopathic arthritis. *McGill J Med* 2011; 13: 8-13. PMID: 22363188
12. <sup>△</sup><sub>a</sub> <sup>b</sup>Matsen FA 3rd (1980). *Compartmental syndromes*. New York: Grune & Stratton
13. <sup>△</sup>Aspenberg P, Wang JS, Jonsson K, Hagert CG. Experimental osteonecrosis of the lunate. Revascularization may cause collapse. *J Hand Surg Br* 1994; 19: 565-9. doi:10.1016/0266-7681(94)90116-3

## Declarations

**Funding:** No specific funding was received for this work.

**Potential competing interests:** No potential competing interests to declare.