

[Open Peer Review on Qeios](#)

# MPX in a female sex worker in Nigeria: A case report

Dimie Ogoina<sup>1</sup>, Izebewule Hendris James<sup>2</sup>

<sup>1</sup> Niger Delta University

<sup>2</sup> Niger Delta University Teaching Hospital (NDUTH)

**Funding:** No specific funding was received for this work.

**Potential competing interests:** No potential competing interests to declare.

## Abstract

Although a few male sex workers were diagnosed with monkeypox during the 2022 outbreak, we are not aware of a prior case of the disease among female sex workers (FSW), especially from a previously endemic country in Africa. We hereby report a case of laboratory-confirmed monkeypox in a 24-year-old FSW from Nigeria. She initially developed a fever and then vesiculopustular lesions localized to the groin and genital skin four days after her last sexual activity with a client in a brothel. We highlight the public health implications of this case report to the epidemiology and control of monkeypox in Africa and globally.

**Dimie Ogoina**<sup>\*1,2</sup>, **Izebewule Hendris James**<sup>1</sup>

<sup>1</sup>*Infectious Diseases Unit, Department of Internal Medicine, Niger Delta University Teaching Hospital, Okolobiri, Bayelsa, Nigeria*

<sup>2</sup>*Department of Internal Medicine, Niger Delta University, Amassoma, Bayelsa, Nigeria*

### \*Corresponding author

*Prof. Dimie Ogoina. Infectious Diseases Unit, Department of Internal Medicine, Niger Delta University Teaching Hospital, Okolobiri, Bayelsa, Nigeria. PMB 100 Yenagoa. Email: [dimieogoina@gmail.com](mailto:dimieogoina@gmail.com)*

## Introduction

As of the 12<sup>th</sup> of October 2022, human monkeypox has resulted in 72,198 laboratory-confirmed infections and 28 deaths in 109 countries across the globe.<sup>[1]</sup> This unprecedented outbreak of monkeypox (MPX) began in May 2022 mostly among gay and bisexual men who belong to interconnected sexual networks, report multiple sexual partners, and had a recent or past history of sexually transmitted infections (STIs) such as HIV, syphilis, and gonorrhoea.<sup>[1][2][3]</sup> These findings support the role of sexual activity and sexual contact in the transmission of MPX, especially among gay and bisexual men who are the most affected social group during the 2022 MPX outbreak.

The role of sexual contact in the transmission of the monkeypox virus (MPV) was first proposed during the 2017- 2018 MPX outbreak in Nigeria.<sup>[4]</sup> The affected cases were mostly young heterosexual men who presented with remarkable genital ulcers and background history of multiple sexual partners, condomless casual sex, and sex with female sex workers (FSW).<sup>[5]</sup> However, follow-up of sexual contacts of cases was not possible, and as such infection among FSW could not be confirmed.

The global spread of MPX influenced by sexual activity has led health authorities to advocate for pre-emptive protection and investigation of male and female sex workers for likely exposure to the MPV.<sup>[6][7]</sup> Although a few cases of MPX have been reported among male sex workers, mainly within gay sexual networks,<sup>[8][9][10][11]</sup> we are not aware of any case of MPX reported among female sex workers, especially from a previously endemic country in Africa such as Nigeria.

We hereby report a case of MPX in a female sex worker managed at a tertiary hospital in Bayelsa, Nigeria.

## Case Description

A 24-year-old lady, who is a self-identified sex worker for about five years, presented with a week's history of fever associated with sore throat and malaise. Her symptoms began four days after condomless casual sex with an unidentified client in a brothel. There was no associated headache or muscle aches and no gastrointestinal or urinary symptoms. A day after the onset of the fever, she noticed a single pruritic papular rash on her vulva. Over the next two days, the fever and sore throat subsided but multiple vesicular lesions appeared on other parts of the groin and genital skin and on the face, trunk, limbs, and palms. The skin lesions were monomorphic and discrete, but the vulva lesions coalesced into ulcers. Within 5 to 7 days after the onset of the rash, skin lesions evolved from vesicles to pustules and started crusting. However, genital ulcers were observed to have expanded and became very painful and uncomfortable. She visited a chemist where she was given an unknown antibiotic and later presented at a private hospital where she again received three different types of antibiotics, she could not specify. Persistent vulva pain and worsening ulcers necessitated her presentation to our hospital.

To her recollection, the last casual sexual partner looked healthy and did not have any indication of active or healed rash on his genitals or on other parts of the body. She reported over 20 transactional casual sexual partners in the prior three months, including clients from two states in Nigeria. She lives with her 26-year-old boyfriend and had unprotected sex with this partner when she was asymptomatic; one day before the onset of the fever. This boyfriend reported urethral discharge and then developed vesicular skin rashes on his limbs and scalp 12 days after the sexual activity. He however declined laboratory diagnosis and further follow-up for undisclosed reasons. She reported a prior diagnosis of Hepatitis B infection a year before presentation and a history of recurrent treatment for unknown STIs characterised by vaginal discharge and lower abdominal pains. She also had a history of sharing sharps, significant alcohol ingestion, and smoking cigarettes and marijuana. There was no recent history of contact with animals (wild or domestic) and no history of ingestion of bush meat. She could not recall having chicken pox as a child but has never received smallpox vaccine. On examination, she was fully conscious and in painful distress, afebrile with an axillary temperature of 36.9 degrees Celsius. There were bilateral inguinal lymphadenopathies measuring 3cm by 4cm, discrete, not tender and not attached to

surrounding structures. Discrete monomorphic vesiculopustular skin lesions (0.5cm in diameter) were on the face, both forearms, both palms, and anterior chest wall. Overall, there were about 30 to 40 skin lesions, but lesions were more concentrated around the groin and genital area, especially around the labia majora and parts of the labia minora bilaterally. The coalescing genital lesions had evolved into deep ulcers, which were tender with surrounding vulva and soft tissue oedema. Digital vaginal examination was not possible due to severe vulva pain. However, there was no vaginal discharge. Cardiovascular, respiratory, and other systemic examinations were essentially normal.

Laboratory confirmation of MPX was by Real-time polymerase chain reaction (PCR-CT value 19.7) at the National Reference Laboratory (NRL) Abuja, Nigeria. Chickenpox PCR was negative. Serology was positive for Hepatitis B surface antigen, but negative for HIV (Rapid tests) and Syphilis (VDRL). Screening for other STIs was not done. She was managed on an outpatient basis and according to the Nigeria MPX Management guidelines.<sup>[12]</sup> Treatment received included empirical antibiotics (Tablets Amoxiclav) for secondary bacterial infections, doxycycline for empirical treatment of other STI causes of genital ulcer disease, non-steroidal anti-inflammatory drugs for pain relief, twice daily cleaning of lesions and ulcers with antiseptic solutions, daily warm saline sitz bath for genital ulcers, and psychological counselling to address anxiety and fear. She was concerned about the potential health consequences of her disease and its impact on her sexual health. She was also educated on the dangers of alcohol and drug abuse and the benefits of safer sex practices, including limiting the number of sexual partners and using condoms during casual sex.

On follow-up 22 days after her first symptom, all skin lesions had desquamated leaving hypopigmented scars and the genital ulcers had resolved significantly, except for a residual healing superficial ulcer measuring 3 by 2 cm and located on the lower part of the left side of the vulva. On follow-up via phone call on day 39 after her first symptom, she reported that all symptoms had resolved, including genital ulcers. At the time of this report, she is yet to return for a physical check-up.

## Discussion

To our knowledge, this is the first published report of human MPX in a FSW.

The temporal association between the last sexual activity and onset of symptoms, and the clustering of skin lesions around the genital area support transmission via sexual contact. The exact mode of transmission is not clear as the last sexual partner was reported to be healthy and asymptomatic. However, transmission to her boyfriend, who had features in keeping with probable MPX, is likely asymptomatic or subclinical as she did not have any symptoms during their sexual activity. It is also possible that the boyfriend was exposed from a non-sexual route, being a household contact of the case. The history of initial and predominant genital rash, rash burden of less than 50, and associated multiple sexual partners are similar to those reported among MSM during the 2022 outbreak.<sup>[13]</sup> These findings substantiate prior reports from Nigeria regarding the sexual transmission of MPX<sup>[4][5]</sup> and align with the current global trend of transmission of MPV via sexual contact. However, the confirmation of MPX in a FSW in a country previously endemic for the disease has far-reaching public health implications.

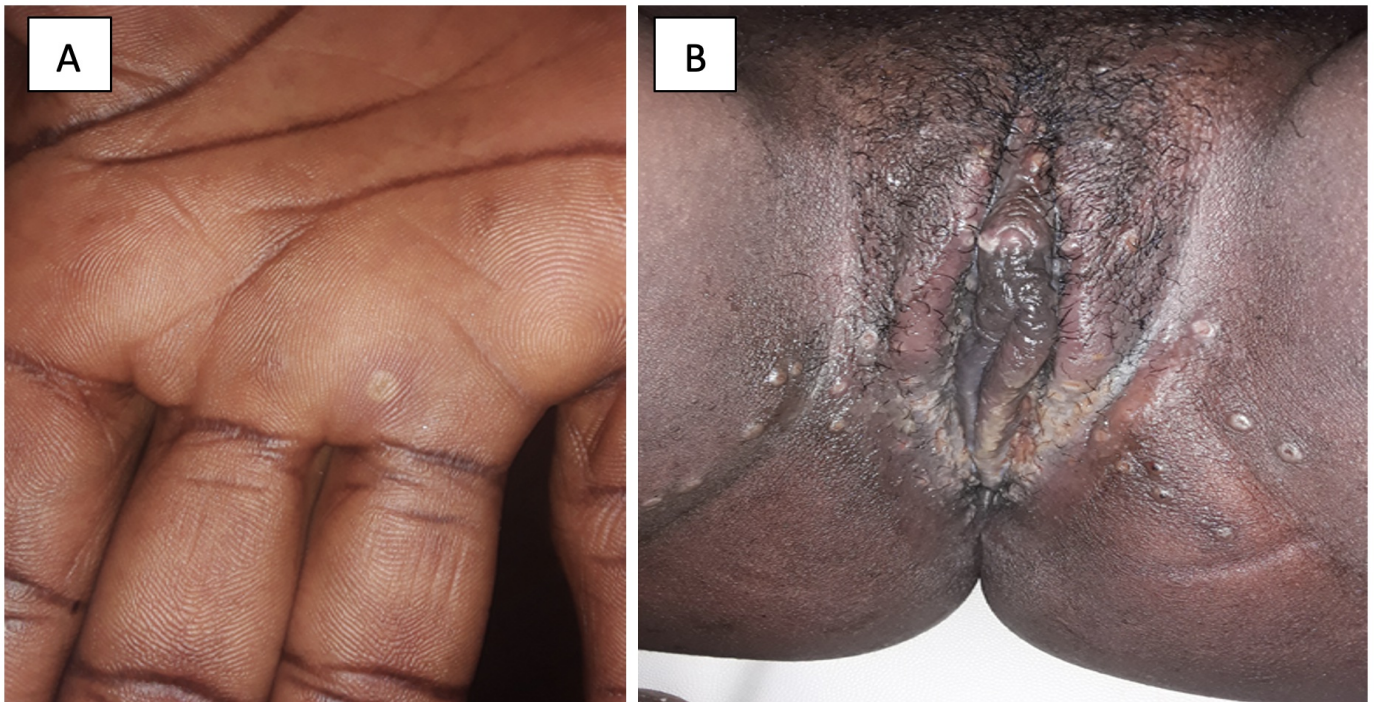
Female sex workers and persons diagnosed with STIs face stigma, blame, and shame.<sup>[14][15][16]</sup> These factors, poor health-seeking behaviour, and inadequate surveillance systems, among other factors, could have contributed to the delay

in the presentation of our case to the hospital for appropriate diagnosis and the refusal of her boyfriend to be tested. With this experience, it is probable that many cases of MPX remain undiagnosed in the community, including among FSW. The long-term impact of STIs on female reproductive health is well documented.<sup>[17][18]</sup> Our case was concerned about her reproductive health in view of the localisation of the disease to the genital area. Fortunately, genital ulcers resolved completely, but the potential impact of the infection on her occupational activities and overall reproductive health remains uncertain. During the current MPX outbreak, concerns were raised about the possible loss of jobs by sex workers and the need to prioritize this social group in preventative interventions, including vaccination programmes.<sup>[6][19][20]</sup> However, the MPX vaccines are yet to be available in most parts of Africa, and there are still a lot of knowledge gaps regarding transmission and risk factors for MPX in Africa.

The history of the HIV/AIDS pandemic provides lessons for reflection. Sexual transmission of HIV was ignored or downplayed in Africa during the early years of the disease and the continent paid and continues to pay devastatingly for this mistake.<sup>[21]</sup> Unlike countries in the global north, where the HIV pandemic initially impacted and spread mostly among MSM, FSW turned out to be one of the major drivers of transmission in Sub-Saharan Africa.<sup>[22][23][24]</sup> Studies from Africa suggest that FSW are 10 to 20 times more likely to be HIV-infected than the general population.<sup>[24][25]</sup> Among FSW, condomless sex and high numbers of sexual partners may serve as amplifiers for the community spread of STIs, including HIV.<sup>[26][27]</sup>

It seems the current global outbreak of MPX is like telling an old history with a new cast. Although transmission of MPX via animal and non-sexual physical contact is ongoing in parts of Africa, it would be careless to ignore the potential of sexual transmission in the continent. But the world seems to be very careful in classifying MPX as an STI even with growing evidence supporting this view.

Perhaps this 'rare' case report of MPX in a FSW linked to sexual contact in a country known to be endemic for the disease is coincidental. Without proactive measures to investigate ongoing MPV transmission and infection among high-risk social groups such as FSW and other key populations in Africa, the continent might be on a journey to repeat history.



**Figure 1.** Vesiculopustular lesions of MPX in a female sex worker. A: Discrete vesiculopustular lesions on the palms, B: Multiple coalescing semi-confluent skin lesions with ulceration around the labia majora and minora bilaterally

## References

1. <sup>a, b</sup>World Health Organization. 2022 Monkeypox Outbreak: Global Trends. 2022; published online Aug 20. [https://worldhealthorg.shinyapps.io/mpx\\_global/](https://worldhealthorg.shinyapps.io/mpx_global/) (accessed Aug 20, 2022).
2. <sup>a</sup>Spicknall IH, Pollock ED, Clay PA, et al. Modeling the Impact of Sexual Networks in the Transmission of Monkeypox virus Among Gay, Bisexual, and Other Men Who Have Sex With Men — United States, 2022. *MMWR Morb Mortal Wkly Rep* 2022; 71: 1131–5.
3. <sup>a</sup>Vusirikala A, Charles H, Balasegaram S, et al. Epidemiology of Early Monkeypox Virus Transmission in Sexual Networks of Gay and Bisexual Men, England, 2022 - Volume 28, Number 10—October 2022 - *Emerging Infectious Diseases journal - CDC. Emerg Infect Dis* 2022; 28: 2082–6.
4. <sup>a, b</sup>Ogoina D, Izibewule JH, Ogunleye A, et al. The 2017 human monkeypox outbreak in Nigeria-Report of outbreak experience and response in the Niger Delta University Teaching Hospital, Bayelsa State, Nigeria. *PLoS One* 2019; 14: e0214229.
5. <sup>a, b</sup>Ogoina D, Yinka-Ogunleye A. Sexual history of human monkeypox patients seen at a tertiary hospital in Bayelsa, Nigeria.: <https://doi.org/10.1177/09564624221119335> 2022; 2022: 1–5.
6. <sup>a, b</sup>Singer RB, Johnson AK, Zemplak JL, et al. Monkeypox Prevention and Protecting Sex Workers: A Call to Action. *Archives of Sexual Behavior* 2022; 1: 1–4.

7. <sup>^</sup> Rizk JG, Lippi G, Henry BM, Forthal DN, Rizk Y. Prevention and Treatment of Monkeypox. *Drugs* 2022; 82: 957–63.
8. <sup>^</sup> Antinori A, Mazzotta V, Vita S, et al. Epidemiological, clinical and virological characteristics of four cases of monkeypox support transmission through sexual contact, Italy, May 2022. *Eurosurveillance* 2022; 27: 2200421.
9. <sup>^</sup> Lapa D, Carletti F, Mazzotta V, et al. Monkeypox virus isolation from a semen sample collected in the early phase of infection in a patient with prolonged seminal viral shedding. *Lancet Infect Dis* 2022; 0. DOI:10.1016/S1473-3099(22)00513-8.
10. <sup>^</sup> Bížová B, Veselý D, Trojáněk M, Rob F. Coinfection of syphilis and monkeypox in HIV positive man in Prague, Czech Republic. *Travel Med Infect Dis* 2022; 49: 102368.
11. <sup>^</sup> Noe S, Zange S, Seilmaier M, et al. Clinical and virological features of first human monkeypox cases in Germany. *Infection* 2022; 1: 1.
12. <sup>^</sup> Nigeria Centre for Disease Control. National Monkeypox public health response guidelines, Nigeria. Abuja, 2019 [https://ncdc.gov.ng/themes/common/docs/protocols/96\\_1577798337.pdf](https://ncdc.gov.ng/themes/common/docs/protocols/96_1577798337.pdf) (accessed Aug 24, 2022).
13. <sup>^</sup> Thornhill JP, Barkati S, Walmsley S, et al. Monkeypox Virus Infection in Humans across 16 Countries - April-June 2022. *N Engl J Med* 2022; published online July 21. DOI:10.1056/NEJMOA2207323/SUPPL\_FILE/NEJMOA2207323\_DATA-SHARING.PDF.
14. <sup>^</sup> Grittner AL, Walsh CA. The Role of Social Stigma in the Lives of Female-Identified Sex Workers: A Scoping Review. *Sexuality & Culture* 2020 24:5 2020; 24: 1653–82.
15. <sup>^</sup> Starrs AM, Ezeh AC, Barker G, et al. Accelerate progress—sexual and reproductive health and rights for all: report of the Guttmacher–Lancet Commission. *The Lancet* 2018; 391: 2642–92.
16. <sup>^</sup> Unemo M, Bradshaw CS, Hocking JS, et al. Sexually transmitted infections: challenges ahead. *Lancet Infect Dis* 2017; 17: e235–79.
17. <sup>^</sup> Workowski KA, Bachmann LH, Chan PA, et al. Sexually Transmitted Infections Treatment Guidelines, 2021. *MMWR Recommendations and Reports* 2021; 70: 1–187.
18. <sup>^</sup> van Gerwen OT, Muzny CA, Marrazzo JM. Sexually transmitted infections and female reproductive health. *Nature Microbiology* 2022 7:8 2022; 7: 1116–26.
19. <sup>^</sup> Strathdee SA, Crago A-L, Shannon K. Harm reduction and rights-based approaches to reduce monkeypox transmission among sex workers. *Lancet Infect Dis* 2022; 0. DOI:10.1016/S1473-3099(22)00661-2.
20. <sup>^</sup> World Health Organization. Public health advice for sex workers on monkeypox. 2022 <https://www.who.int/publications/m/item/public-health-advice-for-sex-workers-on-monkeypox> (accessed Oct 16, 2022).
21. <sup>^</sup> Kagaayi J, Serwadda D. The History of the HIV/AIDS Epidemic in Africa. *Current HIV/AIDS Reports* 2016 13:4 2016; 13: 187–93.
22. <sup>^</sup> Côté AM, Sobela F, Dzokoto A, et al. Transactional sex is the driving force in the dynamics of HIV in Accra, Ghana. *AIDS* 2004; 18: 917–25.
23. <sup>^</sup> Buvé A, Caraël M, Hayes RJ, et al. Multicentre study on factors determining differences in rate of spread of HIV in sub-Saharan Africa: methods and prevalence of HIV infection. *AIDS* 2001; 15 Suppl 4. DOI:10.1097/00002030-200108004-00002.
24. <sup>a, b</sup> Papworth E, Ceesay N, An L, et al. Epidemiology of HIV among female sex workers, their clients, men who have

*sex with men and people who inject drugs in West and Central Africa. J Int AIDS Soc 2013; 16 Suppl 3.*

*DOI:10.7448/IAS.16.4.18751.*

25. <sup>^</sup>Ngugi EN, Roth E, Mastin T, Nderitu MG, Yasmin S. *Female sex workers in Africa: Epidemiology overview, data gaps, ways forward. SAHARA J : journal of Social Aspects of HIV/AIDS Research Alliance / SAHARA, Human Sciences Research Council 2012; 9: 148.*
26. <sup>^</sup>Kenyon C. *Strong associations between national prevalence of various STIs suggests sexual network connectivity is a common underpinning risk factor. BMC Infect Dis 2017; 17. DOI:10.1186/S12879-017-2794-X.*
27. <sup>^</sup>World Health Organization. *Consolidated guidelines on HIV, viral hepatitis and STI prevention, diagnosis, treatment and care for key populations. 2022 <https://www.who.int/publications/i/item/9789240052390> (accessed Oct 18, 2022).*