

[Open Peer Review on Qeios](#)

# Mycetoma in Animals a Review of Cases Reported From 1925-2022; Epidemiology and Management Strategies

Najwa A. Mhmoud<sup>1</sup>

<sup>1</sup> University of Khartoum

**Funding:** No specific funding was received for this work.

**Potential competing interests:** No potential competing interests to declare.

## Abstract

Mycetoma is a chronic, granulomatous disease of human and various domestic animals caused by diverse causative agents. Recently, this mycosis has gained bad reputation due to the appearance of new endemic areas, recognition of new pathogenic species, changes in epidemiology, and increasing numbers of cases. The etiological agents in eumycetoma seem to differ in human and animals. For example, *Madurella mycetomatis* are most common species in humans but only two cases have been reported in animal. While in animals the most common agents were *Pseudallescheria boydii*. However, there are few case reports and studies in animals compared to those in humans especially in endemic areas. Considering the epidemiological importance, taxonomic evolution and worldwide distribution of these fungi in the last decade, there is interest in identifying the species causing mycetoma in animals in different regions of the world. The present article only highlights on the geographic distribution of animal mycetoma in the world as well as the development and epidemiology of antifungal treatment in animals will also be discussed.

**Najwa A Mhmoud<sup>a,\*</sup>**

*Faculty of Medical Laboratory Sciences, Department of Medical Microbiology and Immunology, University of Khartoum, Khartoum, Sudan.*

\*Corresponding author. Dr. Najwa A Mhmoud, Faculty of Medical Laboratory Sciences, Department of Medical Microbiology and Immunology University of Khartoum. Khartoum, Sudan. P.O. Box 102, Khartoum, Sudan. ORCID: 0000-0003-2466-4234. Fax: +249-83-383590. E-mail: [lnfkogodaster@gmail.com](mailto:lnfkogodaster@gmail.com)

**Keywords:** Mycetoma, domestic animals, and antifungal treatment.

## Abbreviations

Scedosporium/Pseudallescheria complex, SPC; Itraconazole, ITC; voriconazole, VRC; posaconazole, POS.

## Introduction

Fungi are relatively uncommon causes of disease in healthy humans and animals, even though hosts are constantly exposed to infectious agents [1][2]. However, an increasing number of fungal diseases in animals have occurred over the last two decades, originating from opportunistic and pathogenic fungi [2][3][4][5].

From a global prospective, zoonotic infections have been recognized for many centuries, and account for the majority of emerging and reemerging infectious diseases, worldwide [6]. Naturally, individuals at highest risk for developing zoonotic diseases include those in occupations that expose them to animals or animal products such as veterinarians and veterinary personnel. A household companion animal also may be implicated as the source of zoonotic infections in humans. However, Mycetoma is a disease of human and various domestic animals caused by diverse causative agents. It was common in gardeners, farmers or people who had contact with plants and soil of natural environments where the fungus could be present in organic materials. At the other hand, the present of mycetoma infections in animals distinguishing mycetoma as an occupation-independent disease and therefore considered an implantation mycosis caused by species of dematiaceous fungi and actinomycets that usually affects the skin at the subcutaneous levels.

Furthermore, the recognition of mycetoma as a neglected disease with a relevant socioeconomic impact on the countries's development obstructs the identification of risk factors and groups. In this context, this systematic review addresses advances in the knowledge of zoonotic mycetoma as disease caused by environmental fungi and bacteria, worldwide, and discusses the points that contribute to mycetoma still being considered a neglected disease as well as the development and epidemiology of antifungal treatment in animals will also be discussed

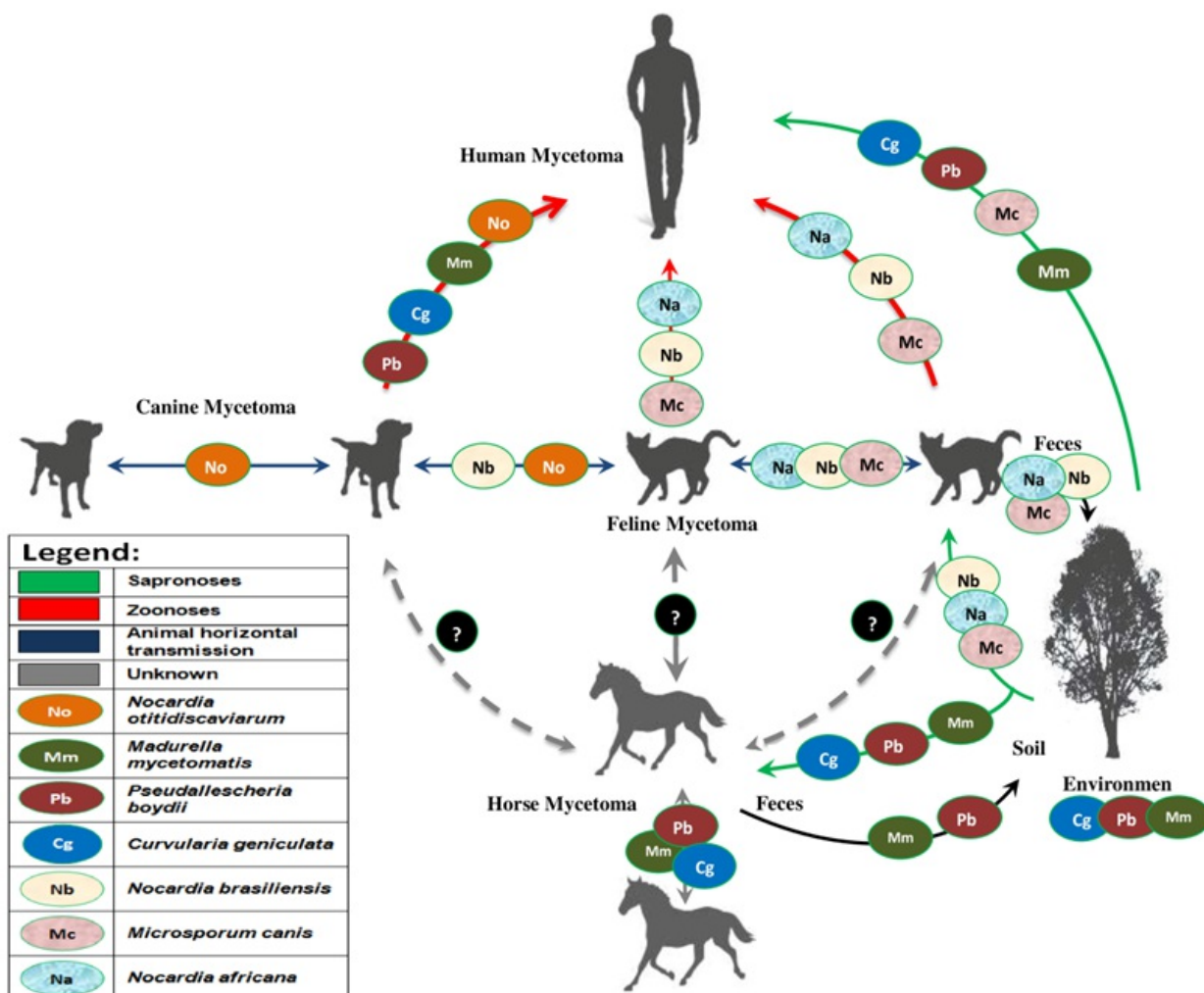
## Etiology of Mycetoma: Historical Aspects

Mycetoma can be caused by fungi (eumycetoma) or bacteria (actinomycetoma) with similar clinical presentation [7][8][9][10]. Many fungal and bacterial agents of human mycetoma have been reported in the literature, belonging to an array of the unrelated genera [11]. Actinomycetoma can be caused by aerobic agents that enter the human body through trauma. The most important agents are *Streptomyces somaliensis*, *Actinomadura madurae*; *Actinomadura pelletieri*, *Nocardia* (*N. brasiliensis*; *N. asteroides*; *N. otitidis-caviarum*; *N. transvalensis*) [7][8][9].

Approximately 50% of mycetoma are eumycetoma. The melanized species causing black-grain eumycetoma worldwide belong to at least two different orders of *ascomycetes*: the *Sordariales*, the *Pleosporales* and the *Chaetothyriales* [11] and the most common species are *Madurella mycetomatis* (70% of cases), (as well as the related *M. pseudomycetomatis*, *M. fahalii* and *M. Tropicana*) Other causative agents include *Falciformispora senegalensis* and *Trematosphaeria grisea*. Rarely, *Exophiala jeanselmei*, *Medicopsis romeroi*, *Phialophora verrucosa* and *Chaetomium atrobrunneum* can cause eumycetoma [12].

Mycetomas in domestic animals including dogs, cats and horses have been reported mostly in North America, southern regions of the United States, South Africa, UK and Australia, but in much fewer numbers [13][14][15][16][17] thus suggesting that mycetoma, in animals as in man, is primarily a subtropical or tropical disease.

The etiological agents in eumycetoma seem to be differ in human and animals. For example, *Madurella mycetomatis* are most common species in humans but only two cases have been reported in animal. While in animals the most common agents were *Pseudallescheria boydii* (Figure 1) similar to human mycetoma in the United State and North America which commonly caused by *Pseudallescheria* [15][18] Followed by *Curvularia geniculata*, *Curvularia verruculosa* [19][20][21][22][23][24], *Drechslera spiciferum* [25] *Bipolaris spicifera*, *Scedosporium apiospermum*, *Aspergillus verruculosa* [26], *Aspergillus terreus* [27] *Phialophora oxyspora* [28] and *Madurella mycetomatis* [29].



**Figure 1. Transmission routes in human and animal mycetoma.** The transmissibility between different species of clinical interest is explored based on literature review data. (A) *Nocardia otitidiscaviarum* and *Nocardia brasiliensis* is associated with large epizooties during animal horizontal transmission (blue route). This is not an exclusive host association, since *Nocardia africana* may also infect cats but with lower frequency. Cat-borne mycetoma can be transmitted to humans (zoonoses) via deep scratching and biting (red route). The threat of cross-species pathogen transmission (blue and red routes) poses the risk of a massive epidemic for humans in highly endemic areas. (B) In the sapronotic route (classical pathway), the presence of the etiologic agents of mycetoma in nature can lead to an endemic profile, with fluctuation in the number of

transmissions. However, the infections remain close to the baseline over time. (C) In the alternative route, feline-borne transmission via deep scratching is highly effective during animal horizontal transmission and during zoonotic transmission, placing a larger number of individuals at risk of acquiring mycetoma.

On the other hand actinomycetoma reports have been relatively rare. Actinomycetales are Gram-positive, branching, filamentous bacteria. They grow in anaerobic/microaerophilic (*Actinomyces* species) or aerobic (*Nocardia* species, *Dermatophilus congolensis*, *Streptomyces griseus*) conditions. All genera may be responsible for chronic, suppurative granuloma characterized by abscess formation and marked fibrosis that are frequently unresponsive to routine antimicrobial therapy. Grains which stain intensely blue with hematoxylin occur within the abscesses, with special bacterial stains, densely packed clusters of fine, branching, filamentous organisms can be seen within the grains. It is important to differentiate actinomycetoma from actinomycosis, and nocardiosis.

Actinomycosis, is a chronic, suppurative disease caused by a gram-positive, non- acid fast, branching, filamentous anaerobic organism. The lesion is characterized by the presence of granules, commonly called "sulfur granules", containing the organism. There are two well established species responsible, namely, *Actinomyces israelii* and *Actinomyces bovis* [30]. The two species are not host specific, but *Actinomyces israelii* has been found most frequently in human and *Actinomyces bovis* in domestic animals, particularly cattle. A third species, referred to as *Actinomyces baudeti*, has been isolated from dogs and cats [31][32]. The sites most frequently affected in man are cervico-facial, thoracic, and abdominal [33], whereas "lumpy jaw" is the usual syndrome in cattle. In swine the organism produces mastitis [34] and in horses it is associated with "poll evil" and "fistulous withers" [35]. In the dog cutaneous, thoracic, and abdominal forms are most common.

Nocardiosis is an acute, chronic, suppurative or granulomatous infectious disease [36]. It is Gram positive, acid-fast, but does not stain with H and E. non-capsulated, non-motile, non-sporulated, aerobic actinomycete, which consist of thin, delicate, slender, beaded filamentous hyphae of 1µm or less in diameter. The organism occurs in environment as a saprobe, and has been isolated from the soil, water, air, dust, and decaying vegetation [37][38]. Currently, over 50 species of *Nocardia* have been identified by phenotypic and molecular methods. *Nocardia asteroides* complex is the principal species, which is implicated in various clinical disorders of humans and animals including birds [39]. *Nocardia asteroides* complex have been recognized as type I, II, III, IV, and V. Type III is called as *Nocardia nova*, and type V as *Nocardia Farcinia* [40]. Recently, *Nocardia cyriacigeorgica*s differentiated from *Nocardia. asteroides*, and is now considered as an emerging pathogen in the United States [41]. Hamid and co-workers isolated *Nocardia africana*, a new pathogen, from patients with pulmonary infections [42]

The recorded history nocardiosis goes back to year 1888 when Edmond Nocard first described pathogenic aerobic actinomycete in cattle with bovine farcy on the Island of Guadeloupe, West Indies [43]. However, the first human case of disease was reported in a 52-year- old glass blower in 1890 by Eppinger [44] Pal is credited to elucidate for the first time the etiologic role of *Nocardia asteroides* in corneal ulcer of cattle from India [45]

On the other hand, *Nocardia asteroides*, does not form granules in tissues; However, other species such as *Nocardia*

*caviae*, *Nocardia mexicana* and *Nocardia brasiliensis* are characterized by the presence of granules [46][47][48][49][50].

Cattle and dogs are more affected than other species of animals [36][51]. Bovine mastitis is the most common clinical presentation of nocardiosis among domestic animals [52]. In earlier studies carried out in Brazil, [53] *Nocardia asteroides* and [54] *Nocardia brasiliensis* strains were identified as most common causative agents of cattle mastitis [55].

The disease in canine is manifested with a variety of clinical presentation Cutaneous or subcutaneous form of disease, which similar to human mycetoma, shows purulent draining sinuses producing tomato soup like exudates [51][56]. *Nocardia otitidiscaviarum* were isolated from eight cases of cutaneous-subcutaneous lesions and one case of pneumonia in dogs in 2008 from Brazil [57]. Recently, Hattori and co-investigators isolated *Nocardia africana* from a case of mycetoma in a cat [58]. *Nocardia brasiliensis* is the most frequently recognized agent of mycetoma. Recently, Rodriguez-Nava and others reported *Nocardia mexicana*, a new pathogen from human mycetoma (Figure 1) [48].

## Transmission

Mycetoma causative agents generally follow an environmental transmission route via traumatic inoculation of contaminated plant debris or from soils. For over a century, this route has affected specific occupational populations, including agricultural workers and gardeners. At the other hand, the presence of mycetoma infections in animals distinguishing mycetoma as an occupation-independent disease.

## Descriptions of Selected Case Reports of Mycetoma in Animals: Canine Mycetoma

Eumycetomas mainly occur in tropical and subtropical regions, and only 19 cases have been reported in dogs (Table 1). Most of the reports were from the United States [15][18][19][20][23][59][60][61] as early as 1925 by Krishnamurti (cited by Davis & Shorten, 1936) [62]. With one exception, in Turkey [63]. Then after that there were sporadic cases being diagnosed in Korea, [64] Australia, [65] India, [66] South Africa, [67] Israel [23] France [68] and Italy [69][70]. The pathogens were diverse, including *Curvularia geniculata* [71], *Curvularia lunata*, *Scedosporium apiospermum*, *Aspergillus terreus* [66], *Aspergillus fumigatus*, *Madurella mycetomatis* [67], *Microsporum canis* [69] *Cladophialophora bantiana* [68][72] and *Madurella pseudomycetomatis* [70].

**Table 1.** It summarizes and descriptions of Selected case reports of eumycetoma in animals and the uses of various antifungals that have proved successfully in various animal species

Host species	Country [Ref.]	Etiology	Diagnosis/Identification	Treatment	Response
	USA [20]	<i>Drechsleraspiciferum</i>	Histopathology	NA	NA
	Germany [73]	<i>Scedosporium apiospermum</i>	Histopathology, Culture	Surgery+ iodine,	Cured
	Canada [14]	<i>Scedosporium apiospermum</i>	Histopathology, Culture	Antifungal/surgery	No response
	USA [74]	<i>Scedosporium apiospermum</i>	Culture	Surgery	Cured

Horse	South Africa [13]	<i>Curvulariageniculata</i>	Histopathology	NA	NA
	Australia [22]	NA	Histopathology	NA	NA
	Czech Rep. [75]	<i>Pseudallescheriaboylei</i>	Histopathology	NA	NA
	South Africa [76]	<i>Madurellamycetomatis</i>	Histopathology, Culture	NA	NA
	USA [16]	<i>Scedosporiummapiospermum</i>	Histopathology, Immunological	Surgery+ iodine,	Cured
	Argentina [24]	<i>Curvulariaverruculosa</i>	Histopathology, Culture	Surgery	Cured
	USA [26]	<i>Aspergillusversicolor</i>	Histopathology, Culture	Surgery	Cured
	France [27]	<i>Aspergillus terreus</i>	Histopathology, Culture	Potassium iodide 30 mg/kg orally once daily / pergolidemesylate 1 mg orally once daily	Cured
	USA [28]	<i>Phialophora oxyspora</i>	Histopathology,, Molecular	Surgery+ iodine,	Cured
	Israel [29]	<i>Madurellamycetomatis</i>	Histopathology, Culture, Molecular	debridement and bandaging with an ointment containing triamcinolone, nystatin, neomycin, and gramicidin	Increased
Feline	Japan [77]	<i>Microsporumcanis</i>	Histopathology, Culture	Surgery	Recurrent
	UK [78]	<i>Exophialajeanselmei</i>	Histopathology, Culture	Surgery	Died
Cattle	Australia [79]	<i>Drechslararostata</i>	Histopathology, Culture	Penicillin and streptomycin	Increased
Canine	Israel [23]	<i>Curvularia lunata</i>	Histopathology, Culture	itraconazole.+Surgery	Died
	USA [71]	<i>Curvularia geniculata</i>	Histopathology, Culture	NA	NA
	Australia [65]	<i>Curvularia geniculata.</i>	Culture	Surgery+ iodine, trinehoprim-sulphadiazine. amphotericin B. dimethyl sulphoxide, thiabendazole and nystatin	Cure
	Italy [69]	<i>Microsporum canis</i>	Histopathology, Culture immunohistochemistry	itraconazole at the dosage of 10 mg /ml every 24 h,+ surgical excision	Cure
	Italy [69]	<i>Aspergillus fumigatus</i>	Histopathology, immunohistochemistry	itraconazole at the dosage of 10 mg /ml every 24 h,+ surgical excision	Cure
	Italy [70]	<i>Madurella pseudomycetomatis</i>	Histopathology, molecular identification	Surgery + Itraconazole (10 mg/Kg/d) for 65 days.	Cure
	France [68]	<i>Cladophialophora bantiana</i>	Histopathology, Culture, molecular identification	Surgery + oral itraconazole associated with flucytosine	Cure
	German [80]	<i>Pseudallescheria boydii</i>	Histopathology, Culture, molecular identification	Itraconazole (30 mg/kg/day)	Increased
	USA [60]	<i>Curvularia geniculata</i>	Histopathology, Culture		
	UK [81]	<i>Pseudallescheria boydii</i>	Histopathology, Culture	Ketoconazole+Surgery	Died
	USA [82]	<i>Pseudallescheria boydii</i>	Histopathology, Culture	Surgery	Died
	Korea, [64]	<i>Pseudallescheria boydii</i>	Histopathology	Surgery	Died
	India [66]	<i>Aspergillus terreus</i>	Culture	antibiotics and hydrocortisones+Surgery	Cure
South				initially comprised oral ketoconazole ('Nizoral', Janssen) 10 mg/kg + body weight three times a day, for 5 days together with	

South Africa, [67]	<i>Madurella mycetomatis</i>	Histopathology, Culture	kg-t body weight, three times a day, for 5 days together with enrofloxacin + oral fluconazole (Pfizer) 50 mg day for 6 weeks +Surgery	Recurrent
Taiwan [72]	<i>Cladophialophora bantiana</i>	Histopathology, Culture, molecular identification	liquid nitrogen cryotherapy every week and oral antifungal of itraconazole 5 mg kg, Surgery+oral itraconazole was given for 2 months after surgery	Cure
Australia [65]	<i>Curvularia</i> species.	Culture	oral itraconazole at5mg/kg SID for 90 days+surgery	Recurrent
UK [83]	<i>Penicillium duponti</i> .	Histopathology, Culture	10 g/kg itraconazole orally once a day+Surgery	Cure

The first case of mycetoma in dog was reported by Robinson<sup>[84]</sup> who submitted a case to the Seminar of the American College of Veterinary Pathologists in 1952<sup>[84]</sup>. The affected animal was, a 5-year old pointer from Florida, had a mycetoma between the toes of the right front foot for over 2years. Then after that Seibold reported one case involving the left foot of a 3-year-old grey hound from Florida<sup>[59]</sup>. The grains in these cases were dark brown in thin histological sections<sup>[84][59]</sup>. Followed by three cases of mycetomas caused by *Curvularia geniculata* were reported in dogs by Charles H. *et al* in 1957<sup>[71]</sup>. Case one represented a 4-year-old Walker hound who was submitted for clinical examination in September, 1954, with a mass of the interdigital spaces of the right front foot. A diagnosis of mycetoma with black grains was made by histopathology and culture which revealed *Curvularia geniculata*<sup>[71]</sup>. In case two; a dog submitted to the Veterinary Clinic of Texas in May, 1946, with tumor in the skin of the foot. It was diagnosed by histopathologic examination as a mycetoma caused by *Curvularia geniculata*. In case three the lesions were present in the abdominal cavity of an adult female dog, and the causative agents were identify as white grains mycetoma<sup>[71]</sup>. Mycetoma usually restricted to subcutaneous tissues, there have been only four reports of cases involving intra-abdominal lesions in dogs<sup>[71][67][85][83]</sup>. These were associated with the uterine stump and the caudal aspect of the right kidney, caused by *Curvularia geniculata*, *Madurella mycetomatis*, *Curvularia species* and *Penicillium duponti* respectively

Valerie *et al* in 1984 described a mycetoma of the fourth tarsal bone of a 5-year-old spayed Corgi-cross bitch caused by the *Curvularia geniculata*. The condition was treated successfully by surgical excision, followed by chemotherapy using iodine, trirnethoprim-sulphadiazine. Amphotericin B. dimethyl sulphoxide, thiabendazole and nystatain<sup>[65]</sup>.

Francesca *et al* in 2001 described two cases of canine dermatophytic pseudomycetoma resulting in subcutaneous nodules. In case one a 8-year-old male Chow Chow was presented with a 5-cm-diameter subcutaneous nodule on the ventral neck, of 2 months duration. The diagnosis of dermatophytic pseudomycetoma was based on histology, fungal culture and immunohisto-chemistry as *Microsporium canis*<sup>[69]</sup>.

In case two a 4-year-old female Yorkshire Terrier was referred for evaluation of 3-cm-diameter, sub-cutaneous nodule on the groin, close to the mammary gland. An excision biopsy of the mass was performed and *Aspergillus fumigatus* was diagnosed based on histology and immunohistochemistry<sup>[69]</sup>.

Pseudomycetomas caused by dermatophytic fungi should be distinguished from eumycetoma. Dermatophytic pseudomycetoma is a deep cutaneous and subcutaneous infection in which granulomatous reactions surround the dermatophyte hyphae. It was suggested that mycelial aggregates formed by dermatophytes are best referred to as

'pseudogranules' and that the term 'pseudomycetoma' should be applied to such dermatophyte infections.

The disease has been described previously in only cats, [86][87][88][89][90] humans [91][92] and horses. [93] Most reported cases of feline dermatophytic pseudomycetoma have occurred in Persians. *Microsporium canis* is reported to be the common organism isolated from cultured nodules, [86][87][88][89][90] but *Trichophyton mentagrophytes* was cultured from a pseudomycetoma in one case [94]. The pathogenesis of the pseudomycetoma is not clear, but some authors proposed that, the mycelial elements escape from the hair follicle into the surrounding tissues where they aggregate and induce an immune response [91][92]. In contrast to the supposed traumatic origin of a mycetoma. The exact immunological mechanism responsible for the formation of the grains is not clear yet.

Ajello *et al.* [95] described the criteria to differentiate between grains formed by mycetoma and pseudomycetoma which include: A sequential formation, characterized by the presence of small to large clusters of mycelia elements.; The pseudograins surround by Splendore–Hoeppli reaction; Characterized by the presence of fewer hyphal filaments; Lack of cementing substance [95].

J. Guillot *et al.* in 2004 reported a case of eumycetoma due to *Cladophialophora bantiana* in a 3-year-old male Siberian Husky dog living in France. The dog presented a tumefaction on the thorax and deformity of the second and third subjacent ribs, which were surgically removed [68].

Peng-Cheng *et al.* in 2011 reported the second case of eumycetoma caused by to *Cladophialophora bantiana* from a 5-year-old castrated male Maltese with lesions on the abdomen for 3 months duration. Small black grains were drained from the fistulae. The grains were collected by a sterile swab and the diagnosis of eumycetoma was made by microscopic examination and culturing. It was identified as *Cladophialophora bantiana* by morphology. The isolated fungus was subjected to molecular identification by amplifying and sequencing ITS regions and 5.8 S ribosomal DNA with the primer pair of ITS1 / ITS4. The sequence was 100% identical to that of CBS100436 of *Cladophialophora bantiana* [72].

In 2009 a case of disseminated pseudallescheriasis in a German Shepherd bitch is presented. Bones (ilium, a rib and phalanges), joints (elbow and acetabulum) and the surrounding tissues were the principal organs affected. In addition, *Pseudallescheria boydii* was isolated, in lower numbers, from the eye, kidney, lymph nodes draining the affected regions and urine. The dog was euthanized. *Pseudallescheria boydii* was identified by morphologic characteristics and molecular techniques. Interestingly, while mycetoma cases have been observed after trauma such as thorn break, operations or especially in cases involving hysterectomies which were complicated by dehiscence of the sutures, disseminated infections caused by the fungus have been reported only in German Shepherd dogs [80]. This case, had no apparent portal of entry or predisposing factors. This seems to be similar to what is known concerning dogs suffering from disseminated aspergillosis caused by *Aspergillus terreus* [66].

In 2022 a 2-year-old dog had a subcutaneous mass in the right thigh that was surgically removed in Italy. Grossly, black-grains were visible and molecularly identify as. *Madurella pseudomycetomatis* [70].

In Summary of cases the most common agents of eumycotic mycetoma in dogs belong to the Scedosporium/Pseudallescheria complex (seven cases) [15][18][80][60][81][82][96] followed by four cases of mycetomas



caused by *Curvularia geniculata* [71][65] two cases by *Cladophialophora bantiana* [68][72].one case was caused by *Curvularia lunata* [23], *M. mycetomatis* [67] *Microsporium canis* [69], *Aspergillus fumigatus* [69] *Aspergillus terreus* [66], and *Madurella pseudomycetomatis* [70].

On the other hand actinomycetoma reports have been relatively rare. Differentiating between lesions caused by actinomyces species as opposed to nocardia species can be challenging, but is important for better identification of the causative agents and better prevention and treatment of infection [54][55][56][57]. Cytological and histopathological evaluation in combination with culture and sensitivity testing is recommended. For both organisms, histological sections stained with Gram stain reveal Gram-positive, branching, filamentous rods. Acid-fast staining can be used for differentiation as nocardia species are more commonly acid-fast while actinomyces species and other anaerobic actinomycetes are not. However, culture of the organism is still required for definitive diagnosis. Nocardia species are strictly aerobic, are usually cultured and are frequently the sole isolate obtained from the sample. Actinomyces species are either facultatively anaerobes or strict anaerobes. Although they are usually cultured within 5-7 days, growth may require up to 4 weeks [97][98][99]

Actinomycetes are endogenous saprophytes on mucous membranes of the oral cavity and gastrointestinal tract of mammals [97][98][99].*Actinomyces viscosus*, *Actinomyces odontolyticus*, *Actinomyces israelii*, *Actinomyces naeslundii* and *Actinomyces bovis* have been cultured from dental plaque of dogs and *Actinomyces hordeovulneris* and *Actinomyces denticolens* have been cultured from normal feline gingiva [100]. These opportunistic pathogens depend on mechanical disruption of normal barriers by disease, or trauma [90]. Bite wounds [49] and foreign bodies are the most common routes of infection in both dogs and cats [97]. Swerczek *et al* described eight cases of canine actinomycosis and mention important criteria for differentiation of actinomycosis from similar diseases, especially nocardiosis, on the basis of histopathologic findings [101]. Nocardiosis usually affects dogs less than a year old whereas; actinomycosis usually affect the oldest dogs. Also actinomycosis is more common among the hunting breeds, possibly because of their greater exposure to soil-contaminated trauma.

The first case of canine nocardiosis was apparently recorded by Trolldenier in 1903 [102]. Since then several further cases have been reported. The disease in canine is manifested with a variety of clinical presentation Cutaneous or subcutaneous form of disease, which simulates to human mycetoma, shows purulent draining sinuses producing tomato soup like exudates [51][56]. *Nocardia otitidiscaviarum* were isolated from eight cases of cutaneous-subcutaneous lesions and one case of pneumonia in dogs in 2008 from Brazil [57]. The cutaneous-subcutaneous lesions (abscesses) in eight dogs were characterized by firm to fluctuant masses, with multiple draining sinuses, and exudation of serosanguinous to purulent secretion containing whitish granules ("sulfur granules"), predominantly in cervical and inguinal regions of skin [57]. In some animals, regional lymph nodes were committed. *Nocardia otitidiscaviarum* was predominantly isolated from the dogs which reported in seven cases where *Nocardia asteroides* in one case. Great similarity was observed between Nocardia species identified in the dogs and cattle, with isolates described previously in human nocardiosis [103][104][105][106][107].

## Feline Mycetoma

Reports of mycetoma in cats are rare. However, to our knowledge, there is no reliable description of feline eumycetoma in the literature. A single case of a British feline eumycetoma is described in 1987 [78]. The lesions principally affected the soft tissues of the right hip and right sublumbar region and were characterized by granulomatous swelling with sinuses, discharging pus containing black granules *Exophiala jeanselmei* (*Torula jeanselmei*). *Exophiala* is a member of the dematiaceous or brown-pigmented fungi and it has been isolated from soil in England [108]. It is probable that the infection in this cat was derived from soil and introduced into the body by wound contamination.

The dermatophytic mycetoma is uncommon in humans and animals [109]. As mentioned above it is a unique form of dermatophytosis (pseudomycetoma).

The first case of feline mycetoma by a dermatophyte has been reported in 2008 by Kano *et al.* The patient was a 9-year-old castrated male Persian cat weighing 4.2 kg with subcutaneous nodules on the dorsal trunk that drained purulent exudates with cement-like substances containing yellowish granules. The etiologic fungus was molecularly as well as morphologically identified as *Microsporum canis* [77].

Although pseudomycetoma has been described previously in cats, [86][87][88][89][90] humans [91][92] and horses. [93], most reported cases of feline dermatophytic pseudomycetoma have occurred in Persian cats suggesting a genetic association with disease, and *Microsporum canis* is reported to be the common organism isolated from cultured nodules, [86][87][88][89][90] but *Trichophyton mentagrophytes* was cultured from a pseudomycetoma in a single case [94].

For actinomycetoma cases in cats, individual case reports of actinomycetoma caused by *Nocardia* species and *Streptomyces* species have been reported [97][98][99]. It is more common causative agents of feline mycetoma. *Nocardia asteroides* is the most common species isolated, and the other *Nocardia* species are very infrequently isolated [99][110]. Zoonotic infection in nocardiosis has not been demonstrated until 2014 by Sykes [111]. However, nocardiosis has been reported in humans with profound scratch or bite wounds from healthy cats or dogs. For that it has been considered as zoonotic disease.

There are 17 cases of nocardiosis in cats over 14 years from the three eastern states of Australia has been reported [112]. The majority of cats presented with spreading lesions of the subcutis and skin associated with draining sinus tract. Lesions were generally located in regions subjected to cat bite or scratch injuries, including limbs, body wall, inguinal panniculus and nasal bridge. In some other cases, lesions were situated on distal extremities. Interestingly, the majority of infections were attributable to *Nocardia nova* [112].

In a single case report *Nocardia africana* was the first report as an agent of mycetoma in a cat [58]. The clinical isolate was identified by physiological tests and 16S ribosomal DNA analysis [58].

*Nocardia brasiliensis* is an important cause of mycetoma in man in the tropical areas of the Americas [33][50], and has also been recorded in a cat in California [113].

In cats individual case reports of cutaneous and subcutaneous infections caused by actinomyces species have been reported previously [114][115]. *Actinomyces viscosus*, *Actinomyces meyeri*, *Actinomyces pyogenes* and *Actinomyces bowdenii* is the most common species isolated from cats [97][98][99][100][116]. Only a single report describing an intraperitoneal mass caused by actinomyces in this species could be found in the literature [117]. In contrast, intra-abdominal actinomycetomas are more frequently reported in humans, predominantly affecting the ileocaecal junction. An unusual presentation of an abdominal actinomycetoma in a cat is described [118]. A 5-year-old, female Ragdoll cat was diagnosed with an intra-abdominal mycetoma involving the ileocaecal region [119].

*Streptomyces* species infections are rarely reported in cats, with three reports describing subcutaneous mycetomas. The first report in the scapula of one cat [118], and the other affecting a hind limb in another cat which was identified as *Streptomyces griseus* [120]. The third case of orbital actinomycotic mycetomas in an 18-month-old male cat presented with an 8 week history of progressive unilateral right-sided mucopurulent nasal discharge and exophthalmos. *Streptomyces cinnamoneus* was identify as causative agents [121].

*Streptomyces cinnamoneus*, a gram-positive, branching filamentous bacteria that belongs to the genus *Streptomyces* and order Actinomycetales. Mycetomas due to *Streptomyces* species are clinically indistinguishable from those due to *Actinomyces* species [118]. *Streptomyces* species are slow-growing saprophytes, which are prevalent in tropical and subtropical regions [122]. Infection is usually established after traumatic implantation [123][124]. Trauma are apparently necessary to produce conditions suitable for the growth of the agent. Since contaminating bacteria are commonly found in the lesions, these may be necessary "associates" for the actinomycete [33]. The collagenase activity of *Streptomyces* species is a risk factor which produce conditions suitable for the growth and spread of the organism [123][124] to adjacent tissues and an actinomycotic mycetoma is formed. [116][118]. Soft tissue infections can progress to involve bone over time. Infection is usually characterized by tumefaction and draining sinuses with granules or grains [123].

## Mycetoma in Horses

Mycetomas in horses have been reported mostly in North America, South Africa, and Australia, and in only once in Europe [29]. There were 17 publications reporting cases as eumycetoma in horses, with the etiological agent identified by culture or immunological techniques (Table 1). Among these, three cases [19][20][125] were caused by *Bipolaris spicifera* (*Helminthosporium spiciferum* or *Curvularia spicifera* at the time of publication). The isolates from the remaining cases were identified as *Scedosporium/ Pseudallescheria* complex (SPC), *Aspergillus versicolor*, *Curvularia verruculosa*, *Phialophora oxyspora* and *Madurella mycetomatis*. [16][22][24][26][27][28][29][126][73][75][76].

These organisms can usually be isolated from plant material and soil; in particular, *Scedosporium/ Pseudallescheria* complex (SPC) can also be isolated from polluted aquatic environments, salt water and air [29]

Johnson *et al* in 1975 described case of a 13 year old crossbred gelding from east-central Alberta (Canada) which was presented to the Clinic at the Western College of Veterinary Medicine in June 1973 with aretrobular swelling causing severe exophthalmos of the left eye. *Scedosporium apiospermum* was isolate as disease caused [14].

In 1977 Boomker *et al* reported the first case of mycetoma from South Africa with black grain mycetoma occurred in two horses, in both cases the organisms identify as *Curvularia geniculata* [13].

In 1995 A 5-year-old mare was presented for treatment of a mass on the upper lip, ungal culture revealed all isolates were identical strains of *Aspergillus versicolor* [26].

A 2 year old Jersey heifer was presented to Veterinary Clinics, Faculty of Veterinary Sciences and Animal Husbandry, Shere-Kashmir University of Agricultural Sciences and Technology of Kashmir, Srinagar, with history of cutaneous Dermatomycosis. Mycological screening of skin scrapings led to isolation and identification of *Curvularia spp.* [126].

Elad *et al* in 2010 reported a case of a 3-year-old Haflinger mare from Israel. It was presented with a wound, measuring about 3 cm, located on the left hind foot at the fetlock. Black 'granules' measuring up to 0.5 cm were seen in the wound. Biopsy was taken for histopathology and culture. The definitive identification of the isolate was established by molecular methods as *Madurella mycetomatis* [29].

Randleff-Rasmussen *et al* described the unusual finding of a cutaneous mycetoma of the on the right upper lip and lateral wing of the nostril of 16 years old horse in 2017 . The causative agent was identify as *Aspergillus terreus* [27].

## Myceroma in Goats

In 1978, Gumaa *et al* reported for the first time in the literature three cases of mycetoma in goats [127]. Two goats had mycetomas on their hind legs and the third on its left scapula. In two goats the causative agents were identified by culture, histopathology and serology as *Actinomadura madurae*. In the remaining goat diagnosis was based only on histopathology and the causative agent was considered to be *Actinomadura pelletierii*. To our knowledge, there is no more reliable description of goats eumycetoma in the literature.

## Mycetoma in Cattle

*Drechslera rostrata* was isolated from a case of eumycotic mycetoma with lesions involved the skin, nasal cavity and lymph nodes of a cow. This was represented the first case of eumycotic mycetoma in Australia. *Drechslera rostrata* is an ubiquitous fungus which often occurs on grasses and in the soil It has not been isolated from other recorded cases of mycetoma [79].

## Antifungal in Animals With Mycetoma Infections

The two major factors for successful management of mycetoma patients are better identification of the causative agents and better prevention and treatment of infection [9][10]. The identification of the causative agent is off value for proper treatment and identification the drug of choice for patient treatment [10]. Especially, fungal mycetoma is difficult to treat,

with long treatment durations and high recurrence rates.

For treatment of eumycetoma, there are no standardized therapies however, many of the antifungal agents that are used in humans are also used in animals for the treatment of eumycetoma infections. Itraconazole (ITC), voriconazole (VRC), and posaconazole (POS) terbinafine, and the echinocandins demonstrate the most consistent *in vitro* activities against the relevant group of fungi [\[128\]\[129\]\[130\]\[131\]\[132\]\[133\]\[134\]\[135\]\[136\]\[137\]](#)

Similarly, many limitations also occur in some animal species, including variable pharmacokinetics, adverse effects, drug interactions, and antifungal resistance.

Successful management of eumycetoma infection usually relies on wide surgical excision of affected areas after medical treatment with antifungal agent. Although antifungal therapy alone may result in variable prognosis even within strains of a single species and recurrence at the same or new site are common [\[138\]](#).

Several treatment regimens have been employed for eumycetoma in animals by different authors. There are several reports on the use of itraconazole in veterinary medicine and usually a prolonged treatment of 1-2 years is required [\[139\]](#). Treatment is continued after apparent clinical recovery to ensure that no fungal elements may remain at the site of healed lesions for up to 6 months.

In one report, a 10-month course of itraconazole (ranging from 10 mg /kg every 12 h to 20 mg /ml every 48 h, together with surgical excision, was successful in resolving dermatophyte pseudomycetoma in a cat [\[90\]](#).

In another case report, the use of oral itraconazole was promising as it was effective in reducing the size of the mass but it had to be withdrawn because of gastrointestinal toxicity. Side-effects have been reported in cats, they seem to be dose-dependent and are usually resolved after drug withdrawal [\[140\]](#).

For feline eumycetoma treatment, Itraconazole 10 mg/kg/day is the treatment of choice but may or may not be successful. Alternatives include ketoconazole 10 mg/kg/day or terbinafine 30-40 mg/kg/day [\[141\]](#) and should be combined with surgical removal.

No extensive clinical trials are available in veterinary medicine allowing us to correlate clinical and histological parameters with the response to therapy. Extension of the lesion, fibrosis and oedema might be considered as factors influencing antifungal therapy.

Actinomycetomas are usually susceptible to antibiotic treatment. Several antibiotics, among these cotrimoxazole, streptomycin, trimethoprim, rifampicin, and amoxicillin-clavulanic acid combination, have been used and found to be effective [\[142\]\[143\]\[144\]\[145\]](#). In addition, combinations such as amikacin with cotrimoxazole and rifampicin, and meropenem have also been used. *In vitro* sensitivity of actinomycetes to ciprofloxacin and linezolid [\[146\]](#) has also been demonstrated, but these are currently not used as a first-line therapy. Today, the common consensus is that cotrimoxazole should be administered as a gold standard therapy in all actinomycetoma patients. Combination antibiotic therapy is preferable to monotherapy to avoid development of drug resistance and to eradicate residual infection. Surgery may be required for

some patients unresponsive to medical therapy alone.

In 1987, Welsh demonstrated excellent therapeutic response with amikacin alone and in combination with TMP-SMX (Welsh regimen) in the treatment of 15 patients with poorly responsive actinomycotic mycetoma and those with systemic involvement. The regimen included cyclical dosing of amikacin 15 mg/kg/day, in two divided doses in cycles of 21 days for 1-3 cycles with intervals of 15 days between cycles while cotrimoxazole (one DS tablet BD) was administered continuously for 35-105 days. The 2-week interval of amikacin in the 5-week cycle is used for renal and audiometric monitoring. All patients achieved remission with this regimen with most patients requiring two cycles (42 days) of amikacin and 70 days of cotrimoxazole therapy [\[147\]](#).

Ramamet *al.* initially described a two-step regimen consisting of an intensive phase with penicillin, gentamicin, and cotrimoxazole for 5-7 weeks, followed by maintenance therapy with amoxicillin and cotrimoxazole continued 5-6 months after clinical remission; however, they later modified this to gentamicin (1.5 mg/kg IV) plus TMP-SMX (two DS tablets) given twice daily for 4 weeks followed by continuation of TMP-SMX plus doxycycline (100 mg twice daily). This modified approach had the advantage of reducing the number of injections and duration of intensive phase and reducing the cost of therapy but still maintaining the efficacy [\[148\]\[149\]](#).

In case of resistance or allergy to co-trimoxazole or amikacin, co-amoxiclav can be used as an alternative to co-trimoxazole and netilmicin to amikacin. Co-amoxiclav can also be used alone during pregnancy; however, chances of resistance are there. Amikacin combined with a carbapenem, such as imipenem or meropenem, could also be used in refractory cases [\[150\]](#).

In conclusion; Transmission by bites or scratches, mainly from cats, which can carry large amounts of spores between their claws in addition to their close contact with humans, may act as risk factor for infection. Suspicious lesions should be biopsied for histopathologic examination and for culture and molecular identification; laboratory errors in the identification of the organism can occur. Tissue and exudate samples must be considered potentially hazardous until a definitive diagnosis has been made. For treatment of eumycetoma, there are no standardized therapies however, many of the antifungal agents that are used in humans are also used in animals for the treatment of eumycetoma infections. Clinical trials are needed in veterinary medicine to correlate clinical and histological parameters with the response to therapy.

## Statements and Declarations

### Acknowledgements

We would like to express our sincere gratitude to the university of Khartoum faculty of medical laboratory sciences for their valuable assistance during this review. Their expertise and support have been instrumental in ensuring the accuracy and quality of our work.

**Funding:** Not applicable.

**Consent to publish:** Not applicable.

**Competing interests:** The authors declare that they have no competing interests.

## References

- <sup>a</sup> Kohler JR, Casadevall A, Perfect J. *The spectrum of fungi that infects humans. Cold Spring Harb Perspect Med.* 2015; 5: a019273.2.
- <sup>a, b</sup> Matthew C Fisher , Daniel A Henk, Cheryl J Briggs, John S Brownstein, Lawrence C Madoff, Sarah L McCraw, et al. *Emerging fungal threats to animal, plant and ecosystem health. Nature.* 2012; 484: 186–194.
- <sup>a</sup> Casadevall A, Pirofski LA. *Host-pathogen interactions: basic concepts of microbial commensalism, colonization, infection, and disease. Infect Immun.* 2000; 68: 6511–6518.
- <sup>a</sup> Guarro J, GeneJ Stchigel AM. *Developments in fungal taxonomy. Clin Microbiol Rev.* 1999; 12: 454–500.
- <sup>a</sup> S Seyedmousavi , J Guillot , A Toloee , P E Verweij , G S de Hoog *Neglected fungal zoonoses: hidden threats to man and animals. Clin Microbiol Infect.* 2015; 21:416–425.
- <sup>a</sup> Kate E. Jones, Nikkita G. Patel, Marc A. Levy, Adam Storeygard, Deborah Balk, John L. Gittleman, et al. *Global trends in emerging infectious diseases. Nature.* 2008; 451: 990–993
- <sup>a, b</sup> Fahal AH, Suliman SH, Hay R. *Mycetoma: The Spectrum of Clinical Presentation. Trop Med Infect Dis.* 2018; 3(3):97.
- <sup>a, b</sup> Emmanuel P, Dumre SP, John S, Karbwang J, Hirayama K. *Mycetoma: a clinical dilemma in resource limited settings. Ann Clin Microbiol Antimicrob.* 2018;17(1):35.
- <sup>a, b, c</sup> Welsh O, Al-Abdely HM, Salinas-Carmona MC, Fahal AH. *Mycetoma medical therapy. PLoS Negl Trop Dis.* 2014;8(10):e3218.
- <sup>a, b, c</sup> Ahmed AA, van de Sande W, Fahal AH. *Mycetoma laboratory diagnosis: Review article. PLoS Negl Trop Dis.* 2017;11(8):e0005638..
- <sup>a, b</sup> de Hoog GS, Adelmann D, Ahmed AOA, Belkum A. *Phylogeny and typification of *Madurella mycetomatis*, with a comparison of other agents of eumycetoma. Mycoses.*2004; 47: 121–130.
- <sup>a</sup> Mhmoud NA, Santona A, Fiamma M, Siddig EE, Deligios M, Bakhiet SM, et al. *Chaetomium atrobrunneum causing human eumycetoma: The first report. PLoS Negl Trop Dis* 2019; 13(5): e0007276. <https://doi.org/10.1371/journal.pntd.1007276>.
- <sup>a, b, c</sup> Boomker J, Coetzler JAW, Scott DB. *Black grain mycetoma (maduromycosis) in horses. Onderstepoort J Vet Res* 1977;44:249-251.
- <sup>a, b, c</sup> Johnson GR, Schiefer B, Pantekoek JFCA. *Case-report, maduromycosis in western Canada. Can Vet J* 1975;16(11):341-344.
- <sup>a, b, c, d</sup> Kurtz HJ, Finco DR, Perman VP. *Maduromycosis by *Pseudallescheria boydii* in a dog. J Am Vet Med Assoc*1970; 157(7):917-921.
- <sup>a, b, c</sup> McEntee M *Eumycotic mycetoma: review and report of a cutaneous lesion by *Pseudallescheria boydii* in a horse. J Am Vet Med Assoc* 1987;191(11):1459-1461.

17. <sup>a</sup> Muller GH, Kirk RW, Scott DW: *Fungal disease*. In: *Small animal dermatology*, 1989, pp. 336-337. WB Saunders Co., Philadelphia, PA
18. <sup>a, b, c</sup> Jang, S. S., J. A. Popp. *Eumycotic mycetoma in a dog caused by Allescheria boydii*. *J. Am. Vet. Med. Assoc* 1970; 157:1071–1076.
19. <sup>a, b, c</sup> Bridges CH. *Maduromycotic mycetomas in animals Curvularia geniculata as an etiologic agent*. *Am J Pathol* 1957; 33: 411–427.
20. <sup>a, b, c, d</sup> Bridges CH. *Maduromycotic mycetomas in animals. Brachycladium spiciferum as an etiologic agent*. *J Am Vet Med Assoc* 1960; 137: 192–201.
21. <sup>a</sup> Bridges, C.H. *Maduromycosis of bovine nasal mucosa*. *Cornell Vet.* 1960;50:468-484.
22. <sup>a, b, c</sup> Miller RI, Norton JH, Summers PM. *Black grained mycetoma in two horses*. *Aust Vet J* 1980; 56: 347–348.
23. <sup>a, b, c, d, e</sup> Elad , U Orgad, B Yakobson, S Perl, P Golomb, R Trainin, et al. *Eumycetoma caused by Curvularia lunata in a dog*. *Mycopathologia* 1991; 116: 113–118
24. <sup>a, b, c</sup> Russo AM, Ebremeyer SE, Mancebo OA, Monzon CM. *Eumycotic mycetomas in horses caused by Curvularia verruculosa*. *Rev Argent Microbiol* 1994; 26: 179–182.
25. <sup>a</sup> Kaplan, W., Chandler, F. W., Ajello, I., Gauthier, R., Riggings, R., Cayouette, P., 1975. *Equine phaeohyphomycosis caused by Drechslera spicifera*. *Canadian Veterinary Journal*. 1975; 16, 205-208.
26. <sup>a, b, c, d</sup> Kevin G. Keegan, Clayton L. Dillavou, Susan E. Turnquist, William H. Fales *Subcutaneous mycetoma-like granuloma in a horse caused by Aspergillus versicolor*. *J Vet Diagn Invest* 1995; 7: 564–567.
27. <sup>a, b, c, d</sup> Pia K. Randleff-Rasmussen, Marion Mosca, Frederic Knoerr, Didier Pin, Isabelle Desjardins *Successful medical treatment of an Aspergillus terreus mycetoma of the nostril/lip in a 16-year-old Fjord ponygelding with pituitary pars intermedia dysfunction* *Vet Dermatol* 2017 DOI: 10.1111/vde.12471.
28. <sup>a, b, c</sup> Lopez MJ, Robinson SO, Cooley AJ, Prichard MA, McGinnis MR. *Molecular identification of Phialophora oxyspora as the cause of mycetoma in a horse*. *J Am Vet Med Assoc* 2007; 230: 84–88.
29. <sup>a, b, c, d, e, f</sup> Elad, D., Blum, S., Kol, A., Ederi, N., David, D. *Eumycetoma caused by Madurella mycetomatis in a mare*. *Med. Mycol.* 2010; 48, 639–642.
30. <sup>a</sup> Thompson, L. *Isolation and comparison of actinomyces from human and bovine infections*. *Proc. Mayo Clin.* 1950; 25, 81-86.
31. <sup>a</sup> Breed, R. S., E. G. I. Murray, N. R. Smith. In *Bergey's Manual of Determinative Bacteriology*, 7th ed. 1957. Williams & Wilkins Co., Baltimore Md.
32. <sup>a</sup> Brion, A. *L'Actinomycose du chien et du chat. Formes cliniques. Necrobacillose des carnivores. Pathogenie, pluralitk des espices d'Actinomyces. Actinomyces baudeti*. *Rev. MCd. VCt.* 1942; 93, 145-147.
33. <sup>a, b, c</sup> Emmons, C. W., C. H. Binford, J. P. Utz. in *Medical Mycology*. Lea & Febiger, Philadelphia. 1963; 73-85.
34. <sup>a</sup> Jubb, K. V. F., P. C. Kennedy. In *Pathology of Domestic Animals*. Academic Press Inc. New York and London. 1963; 1, 458.
35. <sup>a</sup> Kimball, A., E. R. Frank. *The isolation of Actinomyces bovis from fistulous withers and poll evil*. *Amer. J. vet. Res.* 1945; 6, 39-44. 3
36. <sup>a, b</sup> Pal M. *Veterinary and Medical Mycology (1st Edition)*. 2007. Indian Council of Agricultural Research, New Delhi,



India.

37. ^Pal M. Nocardiosis: a saproozoonosis. *Vet* 1999;23: 13-14.
38. ^Saubolle MA, Sussland D. Nocardiosis: review of clinical and laboratory experience. *J Clin Microbiol.* 2003;41: 4497-4501.
39. ^Wilson JW. Nocardiosis: updates and clinical overview. *Mayo Clin Proc* 2012; 87: 403-407.
40. ^Roth A, Andress S, Kroppenstedt RM, Harmsen D, Mauch H. Phylogeny of the genus *Nocardia* based on reassessed 16S rRNA gene sequences reveals underspeciation and division of strains classified as *Nocardia asteroides* into three established species and two unnamed taxons. *J Clin Microbiol* 2003;41: 851-856.
41. ^Schlaberg R, Huard RC, Della-Latta P. *Nocardia cyriacigeorgica* an emerging pathogen in the United States. *J Clin Microbiol* 2008; 46: 265-273.
42. ^Hamid ME, Maldonado L, Sharaf-Eldin GS, Mohammed MF, Saeed NS, Michael Goodfellow *Nocardia africana* sp. nov., a new pathogen isolated from patients with pulmonary infections. *J Clin Microbiol* 2001;39: 625-630.
43. ^Nocard EI. Note about the disease of cattle of Guadeloupe, known for farcy. *Ann Inst Pasteur* 1888;2: 293-302.9.
44. ^Eppinger H. About a new pathogenic *Cladothrix* and induced them pseudotuberculosis (*cladothrichica*). *Posts Path Anat* 1891;9: 287-328.
45. ^Pal M. Etiological significance of *Nocardia asteroides* in corneal ulcer of cattle. *Curr Sci* 1982;51: 533-534.
46. ^Brown-Elliott BA, Brown JM, Conville PS, Wallace RJ Jr. Clinical and laboratory features of the *Nocardia* spp. based on current molecular taxonomy. *Clin Microbiol Rev* 2006;19: 259-282.
47. ^Lovett IS, Housang ET, Burge S, Turner-Warwick M, Thomson FD, Harrison AR, et al. An outbreak of *Nocardia asteroides* infection in a renal transplant unit. *Q J Med* 1981;50: 123-135.
48. <sup>a, b</sup>Rodrigues-Nava V, Couble A, Molinard C, Sandoval H, Boiron P, Laurent F. *Nocardia mexicana* sp. nov., a new pathogen isolated from human mycetomas. *J Clin Microbiol* 2004;42: 4530-4535.
49. <sup>a, b</sup>Paredes BE, Hunger RE, Braathen LR, Brand CU. Cutaneous nocardiosis caused by *Nocardia brasiliensis* after an insect bite. *Dermatology* 1999;198: 159-161
50. <sup>a, b</sup>Gonzalez Ochoa, A. Mycetomas caused by *Nocardia brasiliensis*; with a note on the isolation of the causative organism from soil. *Lab. Invest.*, 1962; 11: 1118-1123.
51. <sup>a, b, c</sup>Ackerman N, Grain E, Castleman W. Canine nocardiosis. *J Am Anim Hosp Assoc* 1982; 18: 147-153.
52. ^Pal M, Khan ZU. Mastitis in a cow due to *Nocardia asteroides*. *Vet Res Bull* 1979;2: 175-176.
53. ^Costa, E.O.; Ribeiro, M.G.; Ribeiro, A.R. et al. Diagnosis of clinical bovine mastitis by fine needle aspiration followed by staining and scanning electron microscopy in a *Prototheca zopfii* outbreak. *Mycopathologia* 2004;158: 81-85.
54. <sup>a, b</sup>Kirpensteijn J, Fingland RB. Cutaneous actinomycosis and nocardiosis in dogs: 43 cases (1980e1990). *JAmVet Med Assoc* 1992;201: 917e20.
55. <sup>a, b</sup>Costa, E.O.; Macedo, M.M.; Coutinho, S.D. Castilho W, Teixeira C.M, Benesi J.F. Isolamento de Actinomicetales aeróbios do gênero *Nocardia* de processos infecciosos dos animais domésticos. *Rev.Fac. Med. vet. Univ. S. Paulo*, 24: 17-21, 1987.
56. <sup>a, b, c</sup>Pal M, Tesfaye S, Boru BG. Nocardial infections of canines and felines. *Indian Pet J* 2011;3: 29-34.
57. <sup>a, b, c, d</sup>Márcio Garcia Ribeiro, Tatiana Salerno, Ana Luiza de Mattos-Guaraldi, Thereza Cristina Ferreira Camello,

Hélio Langoni, Amanda Keller Siqueira, et al. Nocardiosis: an overview and additional report of 28 cases in cattle and dogs. *Rev. Inst. Med. trop. S. Paulo* 2008; 50(3):177-185.

58. <sup>a, b, c</sup>Hattori Y, Kano R, Kunitani Y, Yanai T, Hasegawa A. *Nocardia Africana* isolated from a feline mycetoma. *J Clin Microbiol* 2003;41(2): 908-910. DOI: 10.1128/JCM.41.2.908-910.2003
59. <sup>a, b, c</sup>Seibold, H.R. Mycetoma in a dog. *J.Am.Vet.M.A.* 1955;127:444-445.
60. <sup>a, b, c</sup>Brodey, R. S., H. F. Schryver, M. J. Deubler, W. Kaplan, L. Ajello. Mycetoma in a dog. *J. Am. Vet. Med. Assoc.* 1967;151:442–451.
61. <sup>^</sup>Mezza LE, Harvey HJ. Osteomyelitis associated with Maduromycotic mycetoma in the foot of a dog. *J Am Anim Hosp Assoc* 1985; 21: 215–8.
62. <sup>^</sup>Davis, C. L. Shorten, H. L. Granulomatous nasal swelling in a bovine. *Journal of the American Veterinary Medical Association* 1936; 89, 91-96.
63. <sup>^</sup>Akun, R..Eine Chromoblastomycosis-ähnliche Pilz-krankheit beim Pferde. *Zentralblatt fur Allgemeine Pathologie* 1953;9, 294-297.
64. <sup>a, b</sup>Bak UB, Cheong CK. Abdominal maduromycosis in a dog. *Korean J Vet Res* 1982; 22: 67–8.
65. <sup>a, b, c, d, e</sup>Valerie Coyle, Josephine P. Isaacs, Denise A. O'boyle. Canine mycetoma: a case report and review of the literature *J. small Anirn. Pract.* 1984; 25,26 1-268.
66. <sup>a, b, c, d, e</sup>Pal M, Verma JD. *Aspergillus terreus* as a possible cause of mycetoma on the foot of a dog. *Mykosen* 1987; 30: 172–4.
67. <sup>a, b, c, d, e</sup>Lambrechts N, Collett MG, Henton M. Black grain eumycetoma (*Madurella mycetomatis*) in the abdominal cavity of a dog. *J Med Vet Mycol* 1991; 29: 211–214. doi:10.1080/02681219180000311
68. <sup>a, b, c, d, e</sup>J.Guillot, D. Garcia-Hermoso, F. Degorce, M. Deville, C. Calvie´,G. Dickele´,F. Delisle, R. Chermette. *Eumycetoma Caused by Cladophialophora bantiana in a Dog Journal of Clinical Microbiology*, 2004, 43(10):4901–4903.
69. <sup>a, b, c, d, e, f, g, h</sup>Francesca Abramo, Antonella Vercelli, Francesca Manciant. Two cases of dermatophytic pseudomycetoma in the dog: an immunohistochemical study *Dermatology* 2001;12, 203 – 207.
70. <sup>a, b, c, d, e</sup>Francesco Albanese , Luisa Vera Muscatello , Alice Michelutti , Christian Falcaro , Laura Bellentani , Patrizia Danesi . *Canine eumycetoma caused by Madurella pseudomycetomatis. Medical Mycology Case Reports* 35 (2022) 51–53.
71. <sup>a, b, c, d, e, f, g</sup>Charles H Bredges D.VM. Maduromycotic mycetomas in animals *I957;33 (3):411-427.*
72. <sup>a, b, c, d</sup>Pei-Lun Sun, Pin-Chieh Peng, Pin-Hsien Wu, Ya-Lun Chiang, Yu-Ming Ju, Cheng-Chi Chang, Peng-Cheng Wang. *Canine eumycetoma caused by Cladophialophora bantiana Mycoses*, 2013, 56, 376–381 doi:10.1111/myc.12033
73. <sup>a, b</sup>Von Schiefer B, Mehnert B. Maduromycosis in a horse in Germany. *Berl Munch Tierartztl Wochenschr* 1965; 12: 230–234
74. <sup>^</sup>Reid MM, Jeffrey DR, Kaiser GE. A rare case of maduromycosis of 10 the equine uterus. *Vet Med Sm Anim Clin* 1976; 71: 947–949.
75. <sup>a, b</sup>Otcenášek M, Mátl J, Vitovec J, Vladik P, Wohlman J. Maduromycotic mycetoma in a horse. *Vet Med (Praha)* 1982;

27: 37–43.

76. <sup>a, b</sup> Van Amstel SR, Ross M, van den Bergh SS. *Maduromycosis (Madurella mycetomatis) in a horse*. *J S Afr Vet Assoc* 1984; 55: 81–83.
77. <sup>a, b</sup> Rui Kano, Kazuya Edamura, Hisayoshi Yumikura, Haruhiko Maruyama, Kazuyuki Asano, Shigeo Tanaka, Atsuhiko Hasegawa. *Confirmed case of feline mycetoma due to Microsporium canis* *Mycoses* 2008;52, 80–83.  
doi:10.1111/j.1439-0507.2008.01518.x.
78. <sup>a, b</sup> A. H. M. Van den Broek, K. L. Thoday *Eumycetoma in a British cat* *J. small Anim. Pract.* (1987) 28, 827–831.
79. <sup>a, b</sup> D. Pritchard, B. F. Chick, M. D. Connol. *Eumycotic mycetoma due to Drechslera Rostrata infection in a cow*. *Australian Veterinary Journal* 1977; 53:241–244.
80. <sup>a, b, c</sup> D. Elad, S. Perl, G. Yamin, S. Blum, D. David. *Disseminated pseudallescheriosis in a dog* *Medical Mycology* 2010;48:635–638.
81. <sup>a, b</sup> Allison, N., R. K. McDonald, S. R. Guist, J. Bentinck-Smith. *Eumycotic mycetoma caused by Pseudallescheria boydii in a dog*. *J. Am. Vet. Med. Assoc.* 1989; 194:797–799.
82. <sup>a, b</sup> Walker RL, Monticello TM, Ford RB, English RV. *Eumycotic mycetoma caused by Pseudallescheria boydii in the abdominal cavity of a dog*. *J Am Vet Med Assoc* 1988; 192: 67–70.
83. <sup>a, b</sup> Janovec, J., Brockman, D. J., Priestnall, S. L., & Kulendra, N. J. (2015). *Successful treatment of intra-abdominal eumycotic mycetoma caused by Penicillium duponti in a dog*. *Journal of Small Animal Practice*, 57(3), 159–162.  
doi:10.1111/jsap.12375.
84. <sup>a, b, c</sup> Robinson, V.B. *Third Annual Seminar of the American College of Veterinary Pathologists, 1952, Case number 12*.
85. <sup>^</sup> Joe Herberta., Deborah Chonga, Derek Spielmana, Mark Krockenbergera., Jamie Wildnera, Richard Bishop *Unusual presentation and urinary tract obstruction due to disseminated intra-abdominal eumycetomas caused by Curvularia species in a dog*. *Medical Mycology Case Reports* 26 2019: 28–31
86. <sup>a, b, c, d</sup> Bourdin M., Destombes P., Parodi AL., Drouhet E., Segretain G. *Première observation d'un mycétome chez un chat*. *Recueil de Médecine Vétérinaire*, 1975, 151, 475–480.
87. <sup>a, b, c, d</sup> Tuttle, P.A., Chandler, F.W. *Deep dermatophytosis in a cat*. *Journal of the American Veterinary Medical Association* 1983; 183: 1106 – 8.
88. <sup>a, b, c, d</sup> Yager JA, Wilcock BP, Lynch JA, Thompson AR, *Mycetoma-like granuloma in a cat caused by Microsporium canis*. *Journal of Comparative Pathology* 1986; 96: 171– 6.
89. <sup>a, b, c, d</sup> Fansworth, G.A. *A friable subcutaneous mass in a Persian cat*. *Military Medicine* 1990; 155: 618– 22.
90. <sup>a, b, c, d, e</sup> Medleau, L., Rakich, P.M. *Microsporium canis pseudomycetoma in a cat*. *Journal of the American Animal Hospital Association* 1994; 30: 573 – 6.
91. <sup>a, b, c</sup> M. G. Rinaldi, E. A. Lamazor, E. H. Roeser, C. J. Wegner. *Mycetoma or pseudomycetoma? A distinctive mycosis caused by dermatophytes*. *Mycopathologica* 1983; 81: 41– 8.
92. <sup>a, b, c</sup> Chen AWJ, Kuo JW, Chen JS, Sun C.C, Huang SF. *Dermatophyte pseudomycetoma: a case report*. *British Journal of Dermatology* 1993; 129: 729 – 32.
93. <sup>a, b</sup> Reifinger, M., Pfeifer, F., Kuttin, E.S. *Trichophyton equinum als Ursache von Pseudomyzetomen bei einem Pferd*. *Wiener Tierärztliche Monatsschrift* 1999; 86: 88 –92.

94. <sup>a, b</sup>Scott, D.W., Miller, W.H., Griffin, C.E. Fungal skin diseases. In: Muller and Kirk's Small Animal Dermatology, 5th edn. Philadelphia: W.B. Saunders, 1995: 341.
95. <sup>a, b</sup>Ajello, L., Kaplan, W., Chandler, F.N. Dermatophyte mycetomas: fact or fiction? Proceedings of the Fifth International Conference on Mycoses, Publication number 396. Washington, DC: Pan American Health Organization, 1980: 135 – 40.
96. <sup>^</sup>Cabanes FJ, Roura X, Garcia F, et al. Nasal granuloma caused by *Scedosporium apiospermum* in a dog. *J Clin Microbiol* 1998; 36: 2755–2758.
97. <sup>a, b, c, d, e</sup>Beale KM. Nodules and draining tracts. *Vet Clin North Am Small Anim Pract* 1995; 25: 887e900.
98. <sup>a, b, c, d</sup>Hardie E. Actinomycosis and nocardiosis. In: Greene C, ed. *Infectious diseases of the dog and cat*. Philadelphia: WB Saunders, 1990: 585e591
99. <sup>a, b, c, d, e</sup>Edwards DF. Actinomycosis and nocardiosis. In: Greene C, ed. *Infectious Diseases of the Dog and Cat* 3rd edn. St Louis: Saunders Elsevier, 2006: 451e461.
100. <sup>a, b</sup>Love DN, Vekselstein R, Collings S. The obligate and facultatively anaerobic bacterial flora of the normal feline gingival margin. *Vet Microbiol* 1990; 22: 267e75
101. <sup>^</sup>T. W. Swerczek, B. Schiefer and S. W. Nielsen. Canine Actinomycosis *Zbl. Vet Med., Reihe D, Dd. 15, Heft 9* 1968; 955-970.
102. <sup>^</sup>Trolldenier, I. Uber eine bei einem Hunde gefundene pathogene *Streptothrix*. *Z. Tiermed.* 1903; 7:81-109.
103. <sup>^</sup>Chedid, M.B.; Chedid, M.F.; Porto, N.S.; Severo, C.B., Severo, L.C. -Nocardial infections: report of 22 cases. *Rev. Inst. Med. trop. S. Paulo*, 49: 239-246, 2007.
104. <sup>^</sup>Petrillo, V.F.; Severo, L.C.; Londero, A.T., porto, N.S. Pulmonary nocardiosis report of the first two Brazilian cases. *Mycopathologia (Den Haag)*, 66: 17-20, 1978
105. <sup>^</sup>Awad, F. I., 1959: Nocardiosis in the dog in the Sudan. *Zbl. Vet. Med.* 6, 919-924.
106. <sup>^</sup>Kiska, D.L.; Hicks, K., Pettit, D.J. Identification of medically relevant *Nocardia* species with an abbreviated battery of test. *J. clin. Microbiol.*, 40: 1346-1351, 2002.
107. <sup>^</sup>Saubolle, M.A., Sussland, D. Nocardiosis: review of clinical and laboratory experience. *J. clin. Microbiol.*, 41: 4497-4501, 2003.
108. <sup>^</sup>Chester RS, C.G.C., Thornton, R.H. (1956) A comparison of techniques for isolating soil fungi. *Transaction of the British Mycological Society* 39(3), 301-313.
109. <sup>^</sup>Miller, W.H., Goldschmidt, M.H. Mycetomas in the cat caused by dermatophyte: a case report. *Journal of the American Animal Hospital Association* 1986; 22: 255 – 60.
110. <sup>^</sup>Sanyal, M., Thammayya, A., Basu, N. Actinomycetoma Caused by Organisms of the *Nocardia Asteroides* Complex and Closely Related Strains. *Mycoses*, 2009; 21(4), 109–121. doi:10.1111/j.1439-0507.1978.tb01624.x
111. <sup>^</sup>Sykes J.E. Nocardiosis. *Canine and Feline Infectious Diseases*, Elsevier, 2014.; 409 - 416.
112. <sup>a, b</sup>Malik R., Krockenberger M.B., O'Brien C.R., White J.D., Foster D., Tisdall P.L., et al. Nocardia infections in cats: a retrospective multi-institutional study of 17 cases. *Australian Veterinary Journal* 2006; 84(7): 235-245.
113. <sup>^</sup>Ajello, L., W. W. Walker, D. L. Dungworth, G. L. Brumfield. Isolation of *Nocardia brasiliensis* from a cat with a review of its prevalence and geographic distribution. *J. amer. vet. med. Ass.* 1961; 138:370-376.

114. ^Lewis GE, Fidler WJ and Crumrine MH. Mycetoma in a cat. *J Am Vet Med Assoc* 1972; 161: 500–503.
115. ^Reinke, S. I., P. J. Ihrke, J. D. Reinke, A. A. Stannard, S. S. Jang, D. M. Gillette, K. W.. Hallock. Actinomycotic mycetoma in a cat. *J Am Vet Med Assoc* 1986; 189: 446–448.
116. <sup>a, b</sup>Pascual, C., Foster, G., Falsen, E., Bergstrom, K., Greko, C., Collins, M. D. *Actinomyces bowdenii* sp. nov., isolated from canine and feline clinical specimens. *International Journal of Systematic Bacteriology*, 1999; 49(4): 1873–1877. doi:10.1099/00207713-49-4-1873.
117. ^Kawamura N, Shimada A, Morita T, Murakami S, Azuma R, Fujiwara M, et al. Intra-abdominal actinomycosis in a cat. *Vet Rec* 2005;157: 593e4
118. <sup>a, b, c, d</sup>Thanos L, Mylona S, Kalioras V, Pomoni M, Batakis N. Ileocecal actinomycosis: a case report. *Abdom Imaging* 2004;29:36e8.
119. ^Sharman, M. J., Goh, C. S., Kuipers von Lande, R. G., Hodgson, J. L. Intra-Abdominal Actinomycetoma in a Cat. *Journal of Feline Medicine and Surgery*, 2009; 11(8), 701–705. doi:10.1016/j.jfms.2008.10.007
120. ^Murakami S, Yamanishi MW, Azuma R. Lymph node abscess due to *Actinomyces viscosus* in a cat. *J Vet Med Sci* 1997;59: 1079e80.
121. ^Stuart Walton, Patricia Martin, Carla Tolson, Susannah Plumridge, Vanessa R Barrs. Orbital actinomycotic mycetoma caused by *Streptomyces cinnamomeus* *Journal of Feline Medicine and Surgery Open Reports* 2015;1-5 DOI: 10.1177/2055116915589836.
122. ^Noyal Mariya Joseph, Belgode NarasimhaHarish, Sujatha Sistla, Devinder Mohan Thappa, Subhash Chandra Parija. *Streptomyces bacteremia* in a patient with actinomycotic mycetoma. *J Infect Develop Ctries* 2010; 4: 249–252.
123. <sup>a, b, c</sup>Erika T Quintana, Katarzyna Wierzbicka, Pawel Mackiewicz, Abdalla Osman, Ahmed H Fahal, Mohamed E Hamid, et al. *Streptomyces sudanensis* sp. nov., a new pathogen isolated from patients with actinomycetoma. *Antonie Van Leeuwenhoe* 2008; 93: 305–313.
124. <sup>a, b</sup>Schrenpf H. The family Streptomycetaceae, part II: molecular biology. *Prokaryotes* 2006; 3: 605–622.
125. ^Schauffler AF. Maduromycotic mycetoma in an aged mare. *J Am Vet Med Assoc* 1972; 160: 998–1000.
126. <sup>a, b</sup>Qureshi, S. A. Wani, S. Beg. *Curvularia* Dermatofungosis In a Jersey Heifer: a case report *Pakistan Vet. J.*, 2006, 26(3): 149-150.
127. ^Samia A. Gumaa, F. H. A. Mohamed, E. S. Mahgoub, S. E. I. Adam, A M. EL Hassan, S. E. Imbabi. Mycetoma in goats. *Sabouraudia* 1978; 16:217-223.
128. ^N'diaye B, Dieng MT, Perez A, Stockmeyer M, Bakshi R. Clinical efficacy and safety of oral terbinafine in fungal mycetoma. *Int J Dermatol* 2006;45:154-7.
129. ^Mahgoub ES, Gumaa SA. Ketoconazole in the treatment of eumycetoma due to *Madurella mycetomii*. *Trans R Soc Trop Med Hyg* 1984;78:376-9.
130. ^Venugopal PV, Venugopal TV. Treatment of eumycetoma with ketoconazole. *Australas J Dermatol* 1993;34:27-9.
131. ^Queiroz-Telles F, McGinnis MR, Salkin I, Graybill JR. Subcutaneous mycoses. *Infect Dis Clin North Am* 2003;17:59-85, viii
132. ^Porte L, Khatibi S, Hajj LE, Cassaing S, Berry A, Massip P, et al. *Scedosporium apiospermum* mycetoma with bone involvement successfully treated with voriconazole. *Trans R Soc Trop Med Hyg* 2006;100:891-4

133. ^Negróni R, Tobón A, Bustamante B, Shikanai-Yasuda MA, Patino H, Restrepo A. Posaconazole treatment of refractory eumycetoma and chromoblastomycosis. *Rev Inst Med Trop Sao Paulo* 2005;47:339-46.
134. ^Kloezen W, Meis JF, Curfs-Breuker I, Fahal AH, van de Sande WW. In vitro antifungal activity of isavuconazole against *Madurella mycetomatis*. *Antimicrob Agents Chemother* 2012;56:6054-6
135. ^Ahmed SA, Kloezen W, Duncanson F, Zijlstra EE, de Hoog GS, Fahal AH, et al. *Madurella mycetomatis* is highly susceptible to ravuconazole. *PLoS Negl Trop Dis* 2014;8:e2942.
136. ^Ahmed AO, van de Sande WW, van Vianen W, van Belkum A, Fahal AH, Verbrugh HA, et al. In vitro susceptibilities of *Madurella mycetomatis* to itraconazole and amphotericin B assessed by a modified NCCLS method and a viability-based 2,3-Bis (2-methoxy-4-nitro-5- sulfophenyl)-5-[(phenylamino) carbonyl]-2H-tetrazolium hydroxide (XTT) assay. *Antimicrob Agents Chemother* 2004;48:2742-6.
137. ^van de Sande WW, Fahal AH, Bakker-Woudenberg IA, van Belkum A. *Madurella mycetomatis* is not susceptible to the echinocandin class of antifungal agents. *Antimicrob Agents Chemother* 2010;54:2738-40
138. ^Matsumoto T, Ajello L. Agents of Phaeohiphomycosis. In: *Medical Mycology Volume 4*. Ajello L, Hay RJ (eds), in: *Topley & Wilson's Microbiology and Microbial Infections* Collier L, Balows A, Sussman M (eds). Arnold: OxfordUniversity Press, Inc., New York, 1998: 503–524.
139. ^Welsh O, Salinas MC, Rodríguez MA. Treatment of eumycetoma and actinomycetoma. *Curr Top Med Mycol* 1995;6:47-71.
140. ^Scott DW, Miller WH Jr, Griffin CE.) *Muller and Kirk's Small Animal Dermatology* (6th edn). WB Saunders: Co:Philadelphia, 2001;pp. 379–381.
141. ^Vanessa Schmidt. Uncommon fungal infections in cats and dogs in the UK. *UK Vet – 2008*; 13 (5):1-4.
142. ^Praveen K., Sumathy T.K., Prasad S.A.L., Devi D.R.G., Shivaswamy K.N., Ranganathan C. An unusual presentation of primary cutaneous nocardiosis at a rare site: succesful treatment with a modified Welsh regimen. *Dermatology Online Journal* 2011; 17(12): 1.
143. ^Welsh O, Saucedo E, Gonzalez J, Ocampo J. Amikacin alone and in combination with trimethoprim-sulfamethoxazole in the treatment of actinomycotic mycetoma. *J Am Acad Dermatol* 1987;17:443-8
144. ^Gomez A, Saul A, Bonifaz A, Lopez M. Amoxicillin and clavulanic acid in the treatment of actinomycetoma. *Int J Dermatol* 1993;32:218-20.
145. ^Mahaisavariya P, Chairprasert A, Sivayathorn A, Khemngern S. Deep fungal and higher bacterial skin infections in Thailand: Clinical manifestations and treatment regimens. *Int J Dermatol* 1999;38:279-84
146. ^Gugnani HC, Suselan AV, Anikwe RM, Udeh FN, Ojukwu JO. Actinomycetoma in Nigeria. *J Trop Med Hyg* 1981;84:259-63.
147. ^Damle DK, Mahajan PM, Pradhan SN, Belgaumkar VA, Gosavi AP, Tolat SN, et al. Modified Welsh regimen: A promising therapy for actinomycetoma. *J Drugs Dermatol* 2008;7:853-6.
148. ^Ramam M, Garg T, D'Souza P, Verma KK, Khaitan BK, Singh MK, et al. A two-step schedule for the treatment of actinomycotic mycetomas. *Acta Derm Venereol* 2000;80:378-80.
149. ^Ramam M, Bhat R, Garg T, Sharma VK, Ray R, Singh MK, et al. A modified two-step treatment for actinomycetoma. *Indian J Dermatol Venereol Leprol* 2007;73:235-9.

150. <sup>^</sup>Zijlstra EE, van de Sande WW, Welsh O, Mahgoub el S, Goodfellow M, Fahal AH. *Mycetoma: A unique neglected tropical disease. Lancet Infect Dis 2016;16:100-12.*