

VI: 11 March 2024

Case Report

Occlusive Syndrome by Internal Transmesosigmoid Hernia: A Case Report and Review of the Literature

Peer-approved: 11 March 2024

© The Author(s) 2024. This is an Open Access article under the CC BY 4.0 license.

Qeios, Vol. 6 (2024)
ISSN: 2632-3834

Mohammed Chadli¹, Yassine Merad¹, Nabil Bemrah¹, Malika Tabeche¹

1. Independent researcher

Internal transmesosigmoid is a rare condition, that can cause unusual small bowel obstruction we report of an 80-year-old male patient presenting an acute intestinal obstruction due to transmesosigmoid hernia, the patient was operated for bladder lithiasis 6 years ago. Auscultation revealed intestinal borborygmus, and CT scan showed sigmoid volvulus in a dolichocolon. The diagnosis of acute intestinal obstruction was made, and an emergency laparotomy was indicated. Because of the high risk of strangulation with transmesosigmoid hernia, it is mandatory to timely and periodically reassess. Early surgical intervention is crucial to reduce mortality.

Introduction

Internal hernias are an uncommon cause of small bowel obstruction and are estimated to occur in 1-6% of all cases [1][2], transmesosigmoid hernias constitute 6% of all internal hernias.

Previously, paraduodenal hernias were considered the most common type of internal hernia; however, the incidence of transmesenteric hernias has recently been reported to be increasing [3][4].

Transmesosigmoid hernia is a rare condition [5], especially in patients without a history of abdominal surgery or trauma, it occurs primarily in children due to anatomical factors related to their development [6].

Internal hernias are a serious threat due to the high risk of strangulation and ischemia in the trapped organs. This makes them a surgical emergency. It leads to strangulation, without a previous history of surgery or any known abdominal inflammation [5].

Nonspecific clinical signs are possible [5].

Their diagnosis is generally made intraoperatively [1][7][8].

Early surgical intervention is important in the acute presentation to reduce the high rates of morbidity and mortality associated with this disease. Early recognition of transmesosigmoid hernia is paramount [5].

Case report

We report on 80-year-old male patient admitted urgently for an occlusive syndrome evolving for 05 days.

In surgical history, the patient was operated for bladder lithiasis 6 years ago.

Medical history: RAS

The patient reported the onset of symptoms five days ago, characterized by generalized colic-like abdominal pain, associated with vomiting (02 episodes) and a cessation of materials and gases contemporaneous with the pain syndrome.

The patient was conscious cooperating patient, general condition preserved, integument and

conjunctiva normal colored and stable on the hemodynamic and respiratory level.

BP = 14/09 mm Hg, HR= 90 BPM, FR= 18 CPM.

On inspection, abdomen follows respiratory movements well, and an abdominal pelvic scar was remarked.

Auscultation revealed intestinal gurgling sounds, tympany on the percussion of the abdomen, the hernial orifices were free, rectal ampoule empty and a periumbelicale sensitivity was noted after palpation.

Biology: GR: 5.71,106 elts/mm³, HB: 15.8g/dl, HT: 49.2%, GB: 9440 elts/mm³

Urea: 0.53 g/l, creatinine: 8.40 mg/l, natremia: 141meq/l, kalemia: 4.05 meq/l, chloremia: 104.1meq/l.

TP: 95%, TCA: 25.3 sec, INR: 1.03 Blood sugar: 1.3G/L, GS: O rhesus +

Abdominal X-rays without contrast showed images of inverted U-shaped arches higher than they are wide with hydro-aerial levels at their bases (Figure 1)

Abdominal CT revealed acute mechanical colic intestinal obstruction by strangulation: sigmoid volvulus on a dolichocolon (Figure 2)

Operating protocol was **conducted** under general anesthesia, including endotracheal intubation, in supine position, and midline abdominal incision.

The surgical exploration revealed internal herniation of the grelic loops through a significant defect of the mesosigmoid and dolichosigmoid (viable loops) (Figure 3)

The surgical procedures performed were resection of the sigmoid, closure of the distal colon and opening of the proximal colon using a temporary colostomy.

The patient follow-up was satisfactory, and after few weeks, the patient's digestive continuity was restored.

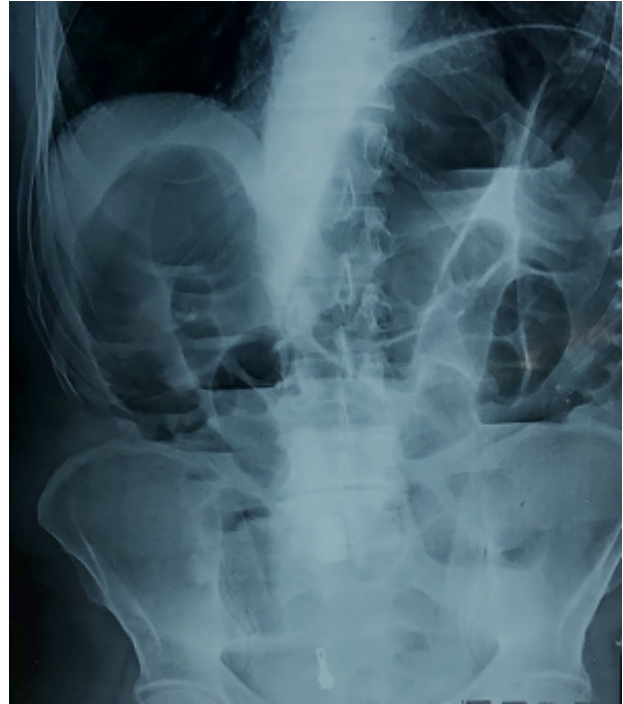

Figure 1.

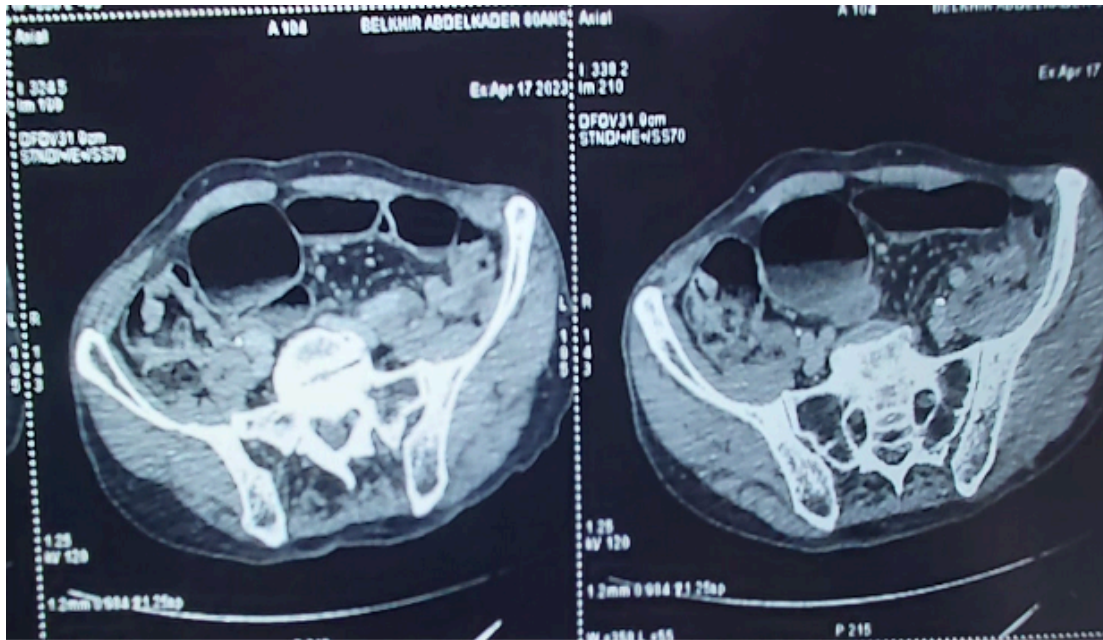


Figure 2.

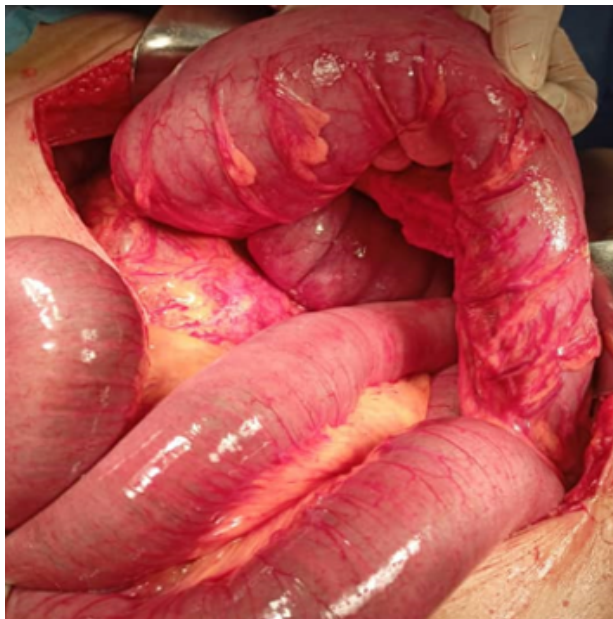

Figure 3.

Discussion

Congenital internal hernias of the mesosigmoid are divided into three categories: inter-sigmoid,

intramesosigmoid and transmesosigmoid [9]. Transmesosigmoid hernias occur when a loop of the small intestine passes through a defect in the mesosigmoid. Its existence in adults is extremely rare [1].

This type of hernia involves both layers of the mesosigmoid and does not have a hernia sac. The underlying embryology of this defect has not been fully elucidated; however, there are several theories as to how these defects occur. It is due to partial regression of the dorsal mesentery or inadequate vascularization of the enlarging mesentery during foetal development. Alternatively, the mesosigmoid may be torn after abdominal trauma [10].

Internal hernias exhibit a spectrum of clinical presentations, ranging from mild digestive complaints to acute abdomen. Physical examination may reveal a palpable mass of herniated loops with localized tenderness [11].

In cases of transmesosigmoid hernias, patients tend to present with acute abdominal pain and signs of small bowel obstruction. However, because the degree of symptoms is related to hernia's duration, reducibility, and presence or absence of strangulation and incarceration [11][12][13], we can have clinical signs

of progressive or persistent small bowel obstruction [5].

Li et al, reported mild tenderness in the lower abdomen with auscultation revealing hyperactive bowel sounds [5]. However, a delayed diagnosis is frequently caused by non-specific clinical presentation, and is typically made at the time of laparotomy [14][15].

Neutrophil leukocytosis can be found on biological assessment [5]. In the acute setting a prompt imaging diagnosis is mandatory [11]. Nevertheless, it is crucial to reassess the condition timely and periodically [5].

In the literature, some patients had a history of several spontaneous resolutions of crisis, before strangulation [1].

Reportedly, the existence, in the antecedents, of numerous similar crises having resolved spontaneously after a few hours should be taken into account.

The majority of literature cases were not considered as internal hernia preoperatively [5]. Making a preoperative examination of an internal hernia can be difficult, CT and MRI scans play a significant role in diagnosis [7]. Classically, abdominal CT can reveal dilated loops of the small bowel with multiple air fluid levels, or a possible blockage in the lower part of the small intestine [5].

Many studies have showed the accuracy of CT in the detection of small bowel obstruction, with a sensitivity and specificity of 94-100% and 90-95% respectively [16][17][18].

Transmesosigmoid hernias are prone to strangulation and necrosis [5]. Management of internal hernias requires reduction of the hernia and repair of the defect by laparoscopy or open approach. In most literature cases, patients presented with septic shock with a provisional diagnosis of intestinal gangrene or closed-loop obstruction requiring exploratory laparotomy. Taking into account the general and intestinal condition of the patient, the stoma was made.

This case highlights a rare cause of intestinal obstruction. In the event of small bowel obstruction without prior abdominal surgery, a congenital internal hernia should be considered. Rapid diagnosis and intervention allowing active management are essential.

Conclusion

Transmesosigmoid hernias are rare congenital hernias that represent only 6% of all internal hernias. Intestinal obstruction due to congenital internal hernias is even rarer with a reported incidence of less than 6%.

Early surgical intervention is important to reduce the high rates of morbidity and mortality associated with this condition.

References

1. ^{a, b, c, d}Mahmoud A, Ounjif O, Azzouzi T et al. Occlusion By Transmeso – Internal Hernia Congenital Sigmoid: About A Case. *SAS J Surg*, 2024 Jan 10(1): 12-14.
2. [^]Malit, M., Burjonrappa, S. (2012). Congenital mesenteric defect: description of a rare cause of distal intestinal obstruction a neonate. *International journal of surgery case reports*, 3(3), 121-123
3. [^]Martin LC, Merkle EM, Thompson WM. Review of internal hernias: radiographic and clinical findings. *AJR Am J Roentgenol*. 2006;186:703-717.
4. [^]Collins D, Kavanagh D, Myers E, Richards S, McDermott E. Incarcerated transmesosigmoid hernia presenting in a 60-year-old man: a case report. *J Med Case Reports*. 2008;2:161.
5. ^{a, b, c, d, e, f, g, h, i, j, k}Li B, Assaf A, Gong YG, Feng LZ, Zheng XY, Wu CN. Transmesosigmoid hernia: case report and review of literature. *World J Gastroenterol*. 2014 May 21;20(19):5924-9.
6. [^]Elmadi, A., Lechqar, M., El Biache, I., Tenkorang, S., Khattala, K., Rami, M., & Bouabdallah, Y. (2014). Trans-mesenteric hernia in infants: report of two cases. *Journal of Neonatal Surgery*, 3(3), 29-31.
7. ^{a, b}Zissin, R., Hertz, M., Gayer, G., Paran, H., & Osadchy, A. (2005). Congenital internal hernia as a cause of small bowel obstruction: CT findings in 11 adult patients. *The British radiology*, 78(933), 796-802.
8. [^]Hirata, K., Kawahara, H., Shiono, N., Nishihara, M., Kubota, A., Nakayama, M., & Kitajima, H. (2015). Mesenteric hernia causing bowel obstruction in very low-birthweight infants. *Pediatrics International*, 57(1), 161-163.
9. [^]Van der Mieren G, de Gheldere V, Vanclooster P. Transmesosigmoid hernia: report of a case and review of the literature. *Acta Chir Belg*. 2005;105:653-655.
10. [^]Sasaki T, Sakai K, Fukumori D, Sato M, Ohmori H, Yamamoto F. Transmesosigmoid hernia: report of a case. *Surg Today*. 2002;32:1096-1098.

11. ^{a, b, c}Lanzetta MM, Masserelli A, Addeo G, Cozzi D, Maggialetti N, Danti G, Bartolini L, Pradella S, Giovagnoni A, Miele V. Internal hernias: a difficult diagnostic challenge. Review of CT signs and clinical findings. *Acta Biomed.* 2019 Apr 24;90(5-S):20-37
12. [^]Fan HP, Yang AD, Chang YJ, Juan CW, Wu HP. Clinical spectrum of internal hernia: a surgical emergency. *Surg Today.* 2008;38:899-904.
13. [^]Blachar A, Federle MP. Internal hernia: an increasingly common cause of small bowel obstruction. *Semin Ultrasound CT MR.* 2002;23:174-83.
14. [^]Akyildiz H, Artis T, Sozuer E, et al. Internal hernia: a complex diagnostic and therapeutic problem. *Int J Surg.* 2009;7:334-7.
15. [^]Kar S, Mohapatra V, Rath PK. A Rare Type of Primary Internal Hernia Causing Small Intestinal Obstruction. *Case Rep Surg.* 2016;2016:3540794.
16. [^]Boudiaf M, Soyer P, Terem C, Pelage JP, Maissiat E, Rymer R. Ct evaluation of small bowel obstruction. *Radiographics.* 2001;21:613-24.
17. [^]Yaghmai V, Nikolaidis P, Hammond NA, Petrovic B, Gore RM, Miller FH. Multidetector-row computed tomography diagnosis of small bowel obstruction: can coronal reformations replace axial images? *Emerg Radiol.* 2006;13:69-72.
18. [^]Merad Y, Derrar H, Zeggai A, Belkacemi M, Belmokhtar Z, Adjmi-Hamoudi H. A rare primary hydatid cyst of the psoas muscle in a rural setting: A case presentation. *Annals of Medicine and Surgery* 59, 86-88, 2020

Declarations

Funding: No specific funding was received for this work.

Potential competing interests: No potential competing interests to declare.